"Hypodense Holes" and the Ocular Glymphatic System: Author Response: "Black Holes" and the Ocular Glymphatic System

We would like to acknowledge our appreciation for Denniston and Keane[1] for their thoughtful and generous comments on our letter.[2] Their statement that their hypothesis of the existence of an "ocular glymphatic system," published in early June 2015 in *Investigative Ophthalmology & Visual Science*, bears resemblance to cosmologic predictions of the existence of "black holes" may, at first sight, seem to be purely metaphoric. However, there may be a surprising realistic relationship between "holes" in the retinal nerve fiber layer (RNFL) and the ocular glymphatic system.

As noted as a personal communication in our hypothesis paper published in June 2015 in *Fluids and Barriers of the CNS*,[3] we had already discussed the possibility of glymphatics in the optic nerve with Iliff in 2013. Xin et al.[4] had previously reported hypodense regions, which looked like holes, in the RNFL of frequency-domain optical coherence tomography (OCT) scans of glaucoma patients and suspects. These holes were typically located adjacent to major blood vessels.[4] In a follow-up study by the same group, eyes from glaucoma patients or suspects previously identified as having holes were studied with en face slab analysis of wide-field swept-source OCT scans.[5] The eyes exhibited paravascular defects even in the absence of epiretinal membranes or high myopia.[5] The authors defined a paravascular defect as a break in the RNFL that extends at least over three B-scans (0.11 mm) along a blood vessel.[5] The paravascular defects appeared as holes or fissures, which followed the course of the blood vessel, as previously described for paravascular inner retinal defects seen with OCT line scans near blood vessels in individuals with high myopia and/or epiretinal membranes.[5] The authors did not have a satisfactory explanation for why the holes tended to appear near blood vessels.[4] One possibility was that a local loss of axons might create a local mechanical force that pulls axons away from the nearest vessel.[4,5] Here, we propose a possible alternative explanation based on extrapolation of the findings in the brain to the retina.

In particular, we raise the question of whether the hyporeflective regions (holes) in the RNFL seen on circumpapillary OCT images of glaucoma patients and suspects could be dilated paravascular spaces analogous to the described dilated Virchow-Robin spaces (VRSs) in the brain. Dependent on their orientation and plane of imaging, enlarged VRSs appear as dots or stripes on magnetic resonance imaging (Fig.).[6] The mechanisms of dilated VRSs are still not well understood, but several different theories have been postulated. Evidence indicates that the VRSs have an important role in the homeostasis of cerebral fluids in the central nervous system,[7] and suggests a possible correlation between VRS enlargement and a disturbance of cerebrospinal fluid (CSF) dynamics. Indeed, if CSF outflow is reduced as a consequence of either CSF flow obstruction or cerebral artery pulsatility inefficiency, or cerebrospinal venous insufficiency and lymphatic disorders, local perivascular CSF recirculation may be impaired and, consequently, the VRSs may dilate due to fluid retention.[7] Given that distension of the VRSs may be related to the fluid retention in and along the paravascular circulation,[7] and given that recent evidence suggests the existence of a glymphatic system in human retina (Hu P, et al. *IOVS* 2016;57:ARVO E-Abstract 996), we postulate that at least some holes in the RNFL and some defects along blood vessels seen in glaucoma patients and suspects could result from ocular glymphatic pathway dysfunction. Obviously, additional research is needed to substantiate this view, and other explanations could also account for these findings in glaucoma patients and suspects.

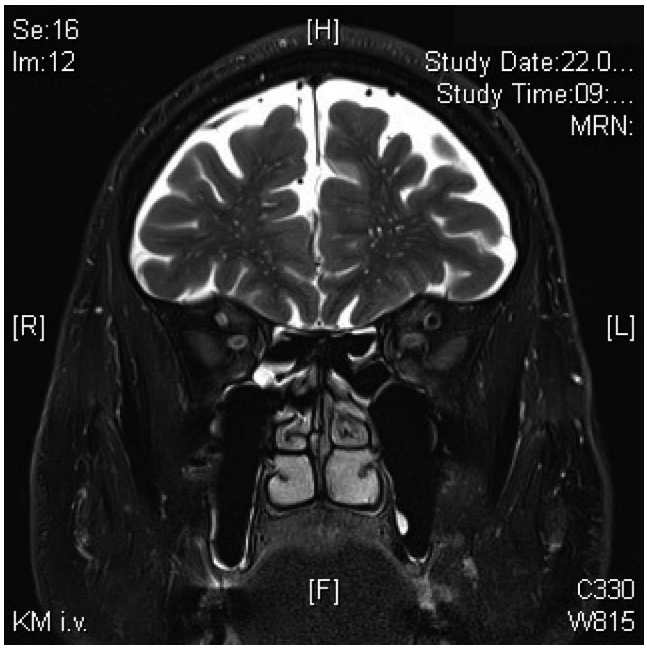

Figure. Coronal T2-weighted magnetic resonance image of the brain of a patient with normal-tension glaucoma, showing multiple enlarged VRSs visible as well-demarcated cerebrospinal fluid-like structures that appear as dots or stripes.

Peter Wostyn[1]
Veva De Groot[2]
Debby Van Dam[3,4]
Kurt Audenaert[5]
Peter Paul De Deyn[3,4,6]
Hanspeter Esriel Killer[7]

[1]Department of Psychiatry, PC Sint-Amandus, Beernem, Belgium; [2]Department of Ophthalmology, Antwerp University Hospital, Antwerp, Belgium; [3]Laboratory of Neurochemistry and Behavior, Institute Born-Bunge, University of Antwerp, Department of Biomedical Sciences, Antwerp, Belgium; [4]Department of Neurology and Alzheimer Research Center, University of Groningen and University Medical Center Groningen, Groningen, The Netherlands; [5]Department of Psychiatry, Ghent University Hospital, Ghent, Belgium; [6]Department of Neurology and Memory Clinic, Middelheim General Hospital (ZNA), Antwerp, Belgium; and the [7]Department of Ophthalmology, Kantonsspital Aarau, Aarau, Switzerland.
E-mail: wostyn.peter@skynet.be

References

1. Denniston AK, Keane PA. "Black holes" and the ocular glymphatic system: author response to "the glymphatic system:

Copyright 2017 The Authors

This work is licensed under a Creative Commons Attribution-NonCommercial-NoDerivatives 4.0 International License.
Downloaded From: http://iovs.arvojournals.org/pdfaccess.ashx?url=/data/journals/iovs/936033/ on 02/21/2017

a new player in ocular diseases?" *Invest Ophthalmol Vis Sci*. 2016;57:5428.

2. Wostyn P, De Groot V, Van Dam D, Audenaert K, De Deyn PP, Killer HE. The glymphatic system: a new player in ocular diseases? *Invest Ophthalmol Vis Sci*. 2016;57:5426–5427.
3. Wostyn P, Van Dam D, Audenaert K, Killer HE, De Deyn PP, De Groot V. A new glaucoma hypothesis: a role of glymphatic system dysfunction. *Fluids Barriers CNS*. 2015;12:16.
4. Xin D, Talamini CL, Raza AS, et al. Hypodense regions (holes) in the retinal nerve fiber layer in frequency-domain OCT scans of glaucoma patients and suspects. *Invest Ophthalmol Vis Sci*. 2011;52:7180–7186.
5. Hood DC, De Cuir N, Mavrommatis MA, et al. Defects along blood vessels in glaucoma suspects and patients. *Invest Ophthalmol Vis Sci*. 2016;57:1680–1686.
6. Barkhof F. Enlarged Virchow-Robin spaces: do they matter? *J Neurol Neurosurg Psychiatry*. 2004;75:1516–1517.
7. Gallina P, Scollato A, Conti R, Di Lorenzo N, Porfirio B. Aβ clearance, "hub" of multiple deficiencies leading to Alzheimer disease. *Front Aging Neurosci*. 2015;7:200.

Citation: *Invest Ophthalmol Vis Sci.* 2017;58:1132–1133.
doi:10.1167/iovs.16-21143

Investigative Ophthalmology & Visual Science

Downloaded From: http://iovs.arvojournals.org/pdfaccess.ashx?url=/data/journals/iovs/936033/ on 02/21/2017