Surgical treatment of Class II dento-facial deformity during adolescence : long-term follow-up

Reference:

Marangoni Sara, Van de Casteele Elke, Frigo Anna Chiara, Fusetti Stefano, Nadjmi Nasser.- Surgical treatment of Class II dento-facial deformity during adolescence : long-term follow-up
Journal of cranio-maxillo-facial surgery - ISSN 1010-5182 - 44:8(2016), p. 979-984
Full text (Publishers DOI): http://dx.doi.org/doi:10.1016/J.JCMS.2016.05.008
To cite this reference: http://hdl.handle.net/10067/1336890151162165141

Accepted Manuscript

Surgical treatment of Class II dento-facial deformity during adolescence: long-term follow-up

Sara Marangoni, Elke Van de Casteele, Anna Chiara Frigo, Stefano Fusetti, Nasser Nadjmi, MD, DDS, PhD, EFOMFS

PII: S1010-5182(16)30059-2

DOI: 10.1016/j.jcms.2016.05.008

Reference: YJCMS 2366

To appear in: *Journal of Cranio-Maxillo-Facial Surgery*

Received Date: 24 December 2015

Revised Date: 13 April 2016

Accepted Date: 9 May 2016

Please cite this article as: Marangoni S, Casteele EVd, Frigo AC, Fusetti S, Nadjmi N, Surgical treatment of Class II dento-facial deformity during adolescence: long-term follow-up, *Journal of Cranio-Maxillofacial Surgery* (2016), doi: 10.1016/j.jcms.2016.05.008.

Surgical treatment of Class II dento-facial deformity during adolescence: Long-term follow-up

Sara Marangoni[a,b], Elke Van de Casteele[a,c], Anna Chiara Frigo[d], Stefano Fusetti[e], Nasser Nadjmi[a]

[a] Department of Cranio-Maxillofacial Surgery, University of Antwerp, AZ MONICA Antwerp, Harmoniestraat 68, 2018 Antwerp, Belgium

[b] Department of Maxillofacial Surgery, Ospedale dell' Angelo di Mestre, via Paccagnella 11, 30174 Venezia, Italy

[c] All for Research vzw, Harmoniestraat 68, 2018 Antwerp, Belgium

[d] Department of cardiac, Thoracic and Vascular Sciences, Medical statistics, University of Padova, Italy

[e] Department of Maxillofacial Surgery, University of Padova, Policlinico Universitario di Padova, via Giustiani 2, 35100 Padova, Italy

Corresponding author:

Nasser Nadjmi, MD, DDS, PhD, EFOMFS – Professor and coordinating program director for OMFS at the University of Antwerp (UA), Belgium and Director of the team for Cleft & Craniofacial anomalies Antwerp, Belgium – nasser@nadjmi.com

Summary

INTRODUCTION

Orthognathic surgery can be seen as a means of correcting an abnormal growth in the facial area through the harmonization of the jaws. Identification of the altered growth patterns responsible for the deformity is important, particularly in the adolescent patient who still has a high growth potential. There is a gradient of movement during puberty, with a trend toward cranio-caudal growth. At the level of the face, there is an acceleration of growth in the lower jaw with respect to the maxilla, which results in differential growth (Bergman at al., 2014). Nanda et al. followed the growth of the jaws in a longitudinal study of 50 patients 6 to 18 years of age, all with skeletal class I deformities, who had not been subjected to any orthodontic treatment (Nanda et al., 2012). Their study clearly demonstrated that the development of the transverse diameter of the face increases steadily for females between ages 6 and 11 years and peaks at age 14, whereas in males, the development is constant up to 13 years, with a peak at the age of 15. The growth was completed at 17.5 years for females and 18 years for males. The growth at the level of the jaws shows a peak with the development of the molars. At age 12, females have achieved 98% of the adult size of the maxilla, and males have achieved 95% of the size.

There have been a multitude of studies on the long-term stability of orthognathic surgery in adult patients with a class II dental-skeletal pattern (de Lir Ade et al.,2013, Moen et al., 2011, Joss and Thüer, 2008, Joss and Vassili, 2009, Mobarak et al., 2001). However, it is more difficult to find a consensus in the literature regarding surgery in

adolescent patients, where there is still a component of postpubertal skeletal growth. Although the results of surgery in a growing patient are not completely understood, the potential benefits include a reduction in treatment times by avoiding the orthopedic-orthodontic treatment phase, and a greater healing potential in the adolescent patient, leading to a better adaptation and stability of the occlusion, muscles, bones, and joints.

The purpose of this study was to evaluate the long-term stability of patients surgically treated for a class II dental-skeletal malocclusion during adolescence. Subjects with a skeletal Class II malocclusion having a hyperdivergent (II,1) or a hypodivergent (II,2) growth pattern represent two distinct groups with different treatment plans and long-term behavior. The patients were evaluated in the light of this distinction in order to study the long-term results of surgical treatment and to compare the stability and performance in patients with remaining growth.

MATERIAL AND METHODS

Patient selection

This research consists of a retrospective case-control comparison of the postoperative trends in patients with Class II division 1 and 2 malocclusion who underwent an osteotomy of one or both jaws at age ≤15 years and who had reached the end of growth in 2014. Patients who had previously undergone surgery for rapid palatal expansion with positioning of a bony distractor and/or had undergone surgically assisted expansion of the lower jaw with a dental anchored distractor were included. However, patients with congenital and syndromic conditions were excluded from the study.

The study population consisted of 30 patients of white ethnicity, including 25 females and five males. Eleven patients had a skeletal Class II division 1 malocclusion, whereas the other 19 patients had a skeletal Class II division 2 malocclusion. The average age of the patients at the time of mono- or bimaxillary surgery was 14.5 ± 0.5 years, and the average age at follow-up was 18.9 ± 1.6 years (Table 1).

A preoperative evaluation was performed to assess the anthropometric measurements, the inclination of the mandibular plane, the overbite and overjet, the dental exposure at rest, and the gummy smile. The treatment plan was then determined according to the findings. In the Class II division 1 group, eight patients underwent a bimaxillary osteotomy (bimax), four of whom also received genioplasty. Two bimax surgeries were preceded by an expansion of both jaws, whereas the other two were performed using only a palatal expansion. Three patients underwent a bilateral sagittal split osteotomy (BSSO) of the mandible. In the Class II division 2 group, 17 patients received a BSSO, two of which included advancement genioplasty. In six cases, the procedure was preceded by palatal expansion, and in one case, the surgery was preceded by expansion of both the maxilla and mandible. Two patients in the division 2 group underwent a bimax.

Surgical procedure

During the bimax surgery, a Le Fort I−type osteotomy of the maxilla was executed, and the fixation was performed using titanium plates and screws (2.0 mm Mini System, KLS Martin). The bilateral sagittal split osteotomy was performed during both single and double jaw surgeries. The distal segment was advanced and the fixation was performed using three positioning bicortical screws per side. The mandibular condyle

was pushed back and upward in the glenoid fossa. The screw fixation was performed with the interposition of a spacer between the proximal and distal segments to prevent the occurrence of compression and torsion of the condyles. There was no rigid intermaxillary fixation used after surgery; however, an elastic guide was applied immediately postoperatively. All patients were treated by the same surgeon (N.N.) and were discharged on the first postoperative day.

Data collection

The data collected for this study comprised the direct measurements obtained using a caliber during consultation and the cephalometric measurements obtained from the radiographic images.

All clinical measurements were performed at three different time points: t_0 = 2 weeks before surgery, t_1 = 1 year postoperatively, and t_2 = after a long-term follow-up. The variables were gathered by the same investigator at t_0 and t_1, whereas the long-term variables were recorded by another investigator from the same team. The direct measurements used throughout this study were the overbite, overjet, frontal dental exposure at rest, frontal gummy smile, premolar gummy smile, and interlabial gap.

For the cephalometric measurements, the angular variables and ratios were used to avoid the influence of magnification factors present in different radiographic images, which were obtained using different machines over the years. Preoperatively, a cone beam computed tomography (CBCT) scan was acquired for all patients in a natural head position using the i-CAT™ (Imaging Sciences International, Hatfield, USA) scanner with a voxel size of 0.4 mm. A lateral cephalogram was reconstructed from the three-dimensional dataset. During the postoperative period, a lateral cephalometric image was

obtained using the CRANEX®D instrument (Soredex, Tuusula, Finland). The different time points of the cephalometric analysis were as follows: t_0 = 2 weeks before surgery, t_1 = 1 week postoperatively, t_2 = after 1 year of follow-up, and t_3 = after long-term follow-up. The chosen landmarks and measurements are depicted in Figure 1 and contain the sella-nasion-A-point (SNA), sella-nasion-B-point (SNB) and A-point-nasion-B-point (ANB) angle, the Frankfort horizontal plane to mandibular plane angle (FHMP), the facial angle which is given by the nasion (N) – pogonion (Pog) and the Frankfort horizontal plane, and finally, the midface-to-lower-face skeletal height ratio (N-ANS:ANS-Me). The cephalometric measurements were obtained by a single investigator.

Statistical analysis

Of the 30 patients, 16 underwent a clinical and radiographic follow-up 1 year after surgery, and 18 underwent a long-term follow-up after an average time of 54 ± 18 months, ranging from 28 to 85 months. Eight patients had follow-up data for both time points (1 year and long-term). A trend-over-time analysis was performed based on a linear mixed effects model that could manage the missing data problem associated with this longitudinal study. The effects of the diagnosis, time, and the interaction (time−diagnosis) were analyzed and estimated means and standard errors were obtained. Using a least squares method, the significance of differences for each parameter was analyzed for the diagnosis (II,1 and II,2) and different time points. All statistical analyses were carried out using the SAS 9.2 software program (SAS Institute, Cary, NC, USA). Differences were considered to be statistically significant for $p < 0.05$.

RESULTS

The estimated mean and standard error of the direct and cephalometric measurements obtained by the mixed effects model are shown in Tables 2 and 3. The statistically significant differences between the time points and diagnoses are indicated. In Figures 2 and 3, the trends over time are graphically shown for all measurements. The p values were obtained for both the diagnosis (D) and the time (T), where the null hypothesis was that the groups (D or T) had the same intercept. When the diagnosis−time interaction (D*T) was studied, the difference between the slope of the two groups was analyzed.

Clinical variables

All measured clinical values showed a statistically significant variation over time (Table 2 and Figure 2). For the overbite, frontal/premolar gummy smile, and interlabial gap, this trend-over-time was not influenced by the initial diagnosis, whereas for the overjet and frontal dental exposure at rest, there was a significant time−diagnosis interaction. A clearly significant difference between the two populations was observed for the frontal dental exposure at rest and the interlabial gap.

Cephalometric variables

The SNA value did not vary significantly over time or between the diagnoses (Table 3 and Figure 3). On the other hand, the SNB and ANB showed statistically significant differences for the trend-over-time, although no statistically significant difference was observed between groups divided based on the initial diagnosis. The FHMP angle was also significantly different in the trend-over-time and was not influenced by the

diagnosis, although a significant difference was observed between the two populations. The facial angle varied significantly in the trend-over-time in a manner dependent on the initial diagnosis. Finally, the midface-to-lower-face skeletal height ratio (N-ANS : ANS-Me) ratio showed a significant difference in the time−diagnosis interaction, and the trend-over-time is dependent on the initial diagnosis.

DISCUSSION

The minimum recommended age for early orthognathic surgery in subjects with facial dysmorphia that is not correctable with only orthopedic-orthodontic treatment is still a controversial issue, not only in the community of maxillofacial surgeons but also among the orthodontists who are the first to diagnose conditions in the patients. This is underlined by a survey of 334 orthodontists conducted in Canada (Weaver et al., 1998).

To identify possible signs and consequences of early surgery, a group of patients with class II dentofacial deformities treated at an age of <15 years was studied in this work. When we analyzed the dental exposure at rest, a significant variation in the trend-over-time was observed in the class II,1 patients. In this specific group, the maxilla was repositioned, causing the frontal dental exposure at rest to decrease toward a value in the normal range. This parameter remained stable between the first year postoperatively and the long-term follow-up (Figure 2). In patients with a class II,2 deformity, the treatment consisted of a mandibular osteotomy, which did not influence this parameter. Another consequence of the maxilla adjustment of the class II,1 patients is that a significant difference was observed for the interlabial gap and gummy smile for both the

frontal and premolar teeth 1 year after surgery. A tendency toward a reduction of this parameter was observed in both the class II,1 and II,2, groups between the first year and long-term follow-up, which is thought to be due to a minimal but continuous elongation of the lip over time. In subjects with a II,2 deformity, there was a slower reduction of the interlabial gap, whereas the patients in the II,1 group showed a steeper deflection. This is in line with a previous study by Blanchette et al., who investigated the soft tissue profiles of patients with a short and long faces, showing that they had different growth patterns of the upper and lower lips (Blanchette et al., 1996). In subjects with a long face, the upper lip protruded more, and a more vertical growth pattern was observed than for subjects with a short face. The growth in the lower third region was more or less twofold in subjects with a long face, resulting in a tendency for the growth to mask the soft tissue and skeletal defects.

The overjet and overbite showed a significant reduction in both populations compared to the preoperative situation at both the 1-year and long-term follow-up examinations. However, only the overjet was significant influenced by the initial diagnosis, although no statistically significant difference was observed between the two populations. As a reference, the ideal range for overjet (2−4 mm) is shown in Figure 2. The overjet value for all patients was located within this range postoperatively and remained stable after orthodontic treatment.

From the cephalometric measurements, the SNA value, which is related to the repositioning of the maxilla, showed no significant differences over time and was not significantly affected by the diagnosis. In the era of rigid osteosynthesis, the repositioning of the upper jaw is considered to be a highly stable movement, as

supported by Proffit et al. in their review on the principles of the hierarchy of the stability and predictability of orthognathic surgery (Proffit et al., 2007).

The SNB angle, related to the mandibular changes, showed the same trend-over-time in both class II,1 and II,2 patients, although the mean values remained within the normal range. The relationship between the two jaws is better expressed by the ANB angle. This parameter showed a similar trend-over-time for the two groups and also had a tendency to increase toward the original value, although a statistically significant difference was still observed between the preoperative situation and the postoperative follow-up.

The mandibular plane angle (FHMP), another parameter assessing the BSSO, showed a significant difference between the two populations and a significant influence of the time factor. In particular, in the class II,1 patients, it was noted that the FHMP value was reduced as a result of surgery, but it tended to relapse during the follow-up period. In patients with class II,2 deformities, the increase in the value of the FHMP angle in the immediate postoperative period remained stable after the long-term follow-up, showing an increased vertical vector leading to a growth closer to normal. Proffit analyzed the differences in the results after treatment of a mandibular deficiency between adolescent patients and adults, and observed an increase in the mandibular plane angle that suggested delayed vertical growth (Proffit et al., 2010). Wolford evaluated the effects of the surgical correction of mandibular defects in growing subjects, dividing them into hypodivergent and hyperdivergent patients. He showed that the growth in these patients followed the divergence of the mandibular plane, and became closer to normal (Wolford et al., 1979).

The analysis of the vertical dimension, expressed by the ratio between the middle third and the bottom third (N-ANS : ANS-Me) of the facial height, confirmed the different time courses after surgery between the two classes. In both groups, a normalization of this relationship is pursued by lengthening the lower third of the face in patients with a deep bite (short face) and by reducing the middle third in patients with a long face. Mogavero et al. showed that patients with a vertical maxillary excess who were treated at an average age of 14.5 years showed a 50% reduction of their residual growth (Mogavero et al., 1997). However, in patients with class II,2 deformities, there was a continuous reduction over the long term, which is indicated by the increased ANS-Me. This supports mandibular vertical growth, as shown in the trends of the FHMP angle. The tendency to relapse in patients with class II,1 deformities was further confirmed by the facial angle, which gives a measure for prognathism. A significant difference was observed in the trend-over-time between the two populations (class II,1 and class II, 2). In particular, in the class II,2 patients, the value increased over time, which was consistent with a residual horizontal growth of the mandible. In patients with class II,1 deformities, a decrease was observed due to the tendency to relapse, which was also observed in the mandibular plane angle. This resulted in the backward movement of the pogonion, in addition to a possible reduction of the sagittal mandibular length, as observed by several other researchers (Mojdehi et al., 2001, Wolford et al., 2001, Maia et al., 2010). Mojdehi studied 15 patients with adolescent skeletal class II,1 deformities treated with only maxillary surgery. Early surgery on the upper jaw did not alter the growth pattern of subjects with vertical maxillary excess, but it did induce an adaptation of the mandible to the new upper jaw location with a backward rotation (Mojdehi et al., 2001).

The trends in the changes in the cephalometric variables between the two populations shows a slight difference, with a more gradual variation of the parameters in patients with a diagnosis of II,2 deformities, whereas in patients with a diagnosis of class II,1 the tendency toward a certain degree of stability was observed in the first postoperative year, which approached the preoperative values between the first year and long-term follow-up. This was also found in a study by Moen et al., who evaluated the long-term stability of mandibular advancement after BSSO in patients with class II dentofacial deformities, and identified a trend toward early relapse (2 months) in patients surgically treated for dysmorphia class II deep-bite, whereas in the patients with a long face, recurrence was not noted until 1 to 3 years after surgery (Moen et al., 2011).

CONCLUSION

Given the characteristics of the study population, which was mainly composed of females who were approximately 15 years old, and the fact that we observed the changes in the clinical and cephalometric variables over a long-term follow-up, we can conclude that early surgery can and should be considered in light of the functional and esthetic needs of the patient. In particular, we have observed how the subjects with a deep bite as a result of the surgery may show a modification of the vectors of growth, with the maintenance of the harmonious development between the jaws and of the facial esthetics in the presence of residual postpubertal growth.

Less predictable is the trend in hyperdivergent patients, who are more prone to relapse in the long-term. Early surgery in these patients should be considered based on the

degree of deformity present and its influence on the patient's self-image and interpersonal relationships.

REFERENCES

Bergman RT, Waschak J, Borzabadi-Farahani A, Murphy NC: Longitudinal study of cephalometric soft tissue profile traits between the ages of 6 and 18 years. Angle Orthod. 84(1): 48-55, 2014. (doi: 10.2319/041513-291.1)

Blanchette ME, Nanda RS, Currier GF, Ghosh J, Nanda SK: A longitudinal cephalometric study of the soft tissue profile of short- and long-face syndromes from 7 to 17 years. Am J Orthod Dentofacial Orthop. 109(2): 116-31, 1996.

de Lir Ade L, de Moura WL, Oliveira Ruellas AC, Gomes Souza MM, Nojima LI: Long-term skeletal and profile stability after surgical-orthodontic treatment of Class II and Class III malocclusion. J Craniomaxillofac Surg. 41(4): 296-302, 2013. (doi:10.1016/j.jcms.2012.10.001)

Joss CU, Thüer UW: Stability of the hard and soft tissue profile after mandibular advancement in sagittal split osteotomies: a longitudinal and long-term follow-up study. Eur J Orthod. 30(1): 16-23, 2008.

Joss CU, Vassalli IM: Stability after bilateral sagittal split osteotomy advancement surgery with rigid internal fixation: a systematic review. J Oral Maxillofac Surg. 67(2): 301-13, 2009. (doi: 10.1016/j.joms.2008.06.060)

Maia FA, Janson G, Barros SE, Maia NG, Chiqueto K, Nakamura AY: Long-term stability of surgical-orthodontic open-bite correction. Am J Orthod Dentofacial Orthop. 138(3): 254.e1-254.e10; discussion 254-6, 2010. (doi: 10.1016/j.ajodo.2010.03.021)

Mobarak KA, Espeland L, Krogstad O, Lyberg T: Mandibular advancement surgery in high-angle and low-angle class II patients: different long-term skeletal responses. Am J Orthod Dentofacial Orthop. 119(4): 368-81, 2001.

Moen K, Wisth PJ, Skaale S, Bøe OE, Tornes K: Dental or skeletal relapse after sagittal split osteotomy advancement surgery? Long-term follow-up. J Oral Maxillofac Surg. 69(11): e461-8, 2011. (doi: 10.1016/j.joms.2011.02.086)

Mogavero FJ, Buschang PH, Wolford LM: Orthognathic surgery effects on maxillary growth in patients with vertical maxillary excess. Am J Orthod Dentofacial Orthop. 111(3): 288-96, 1997.

Mojdehi M, Buschang PH, English JD, Wolford LM: Postsurgical growth changes in the mandible of adolescents with vertical maxillary excess growth pattern. Am J Orthod Dentofacial Orthop. 119(2): 106-16, 2001.

Nanda R, Snodell SF, Bollu P: Transverse growth of maxilla and mandible. Semin Orthod 18: 100-117, 2012. (doi: 10.1053/j.sodo.2011.10.007)

Proffit WR, Turvey TA, Phillips C: The hierarchy of stability and predictability in orthognathic surgery with rigid fixation: an update and extension. Head Face Med. 3:21, 2007.

Proffit WR, Phillips C, Turvey TA: Long-term stability of adolescent versus adult surgery for treatment of mandibular deficiency. Int J Oral Maxillofac Surg. 39(4): 327-32, 2010. (doi: 10.1016/j.ijom.2010.01.012)

Weaver N, Glover K, Major P, Varnhagen C, Grace M: Age limitation on provision of orthopedic therapy and orthognathic surgery. Am J Orthod Dentofacial Orthop. 113(2): 156-64, 1998.

Wolford LM, Schendel SA, Epker BN: Surgical-orthodontic correction of mandibular deficiency in growing children (long term treatment results). J Maxillofac Surg. 7(1): 61-72, 1979.

Wolford LM, Karras SC, Mehra P: Considerations for orthognathic surgery during growth, part 1: mandibular deformities. Am J Orthod Dentofacial Orthop. 119(2): 95-101, 2001.

Wolford LM, Karras SC, Mehra P: Considerations for orthognathic surgery during growth, part 2: maxillary deformities. Am J Orthod Dentofacial Orthop. 119(2): 102-5, 2001.

Figure 1. Schematic drawing of the cephalometric landmarks used for the angular and ratios analysis at the different time points.

Figure 2. Trend over time for the direct measurements. D = diagnosis, T = time, D*T = Diagnosis−time interaction. p Values < 0.05 are considered statistically significant.

Figure 3. Trend over time for the cephalometric analysis. D = diagnosis; T = time; D*T = Diagnosis−time interaction. p Values < 0.05 are considered statistically significant.

Table 1. Information on the studied patient group operated for a class II dental-skeletal malocclusion (N = 30)

Sex		
Male	5 (17%)	
Female	25 (83%)	
Class II	Division 1: 11 (37%)	Division 2: 19 (63%)
BSSO	3 (28%) → incl. 1 TPD & 1 TPD + TMD	15 (78%) → incl. 5 TPD & 1 TPD + TMD
BSSO + chin	/	2 (11%) → incl. 1 TPD
Bimax	4 (36%) → incl. 1 TPD & 1 TPD + TMD	2 (11%)
Bimax + chin	4 (36%) → incl. 1 TPD & 1 TPD + TMD	/
Age (y)	At surgery	At follow-up
Mean ± SD	14.5 ± 0.5	18.9 ± 1.6
Range	14–16	16–22

Abbreviations: BSSO, bilateral sagittal split osteotomy; incl., including; TPD, trans-palatal distraction; TMD, trans-mandibular distraction.

Table 2. Estimated means and standard errors for the direct measurements obtained through a linear mixed effects model

		T_0	T_1	T_2
Overbite	II,1	3.36 ± 0.62	1.70 ± 0.26 *	1.43 ± 0.30 *
(mm)	II,2	4.22 ± 0.49	2.13 ± 0.16 *	1.83 ± 0.24 *
Overjet	II,1	6.50 ± 0.63	3.22 ± 0.28 *	3.29 ± 0.50 *
(mm)	II,2	8.00 ± 0.49	2.79 ± 0.18 *	2.70 ± 0.39 *
Frontal dental exposure at rest	II,1	6.27 ± 0.42	4.33 ± 0.42 *	4.25 ± 0.33 *
(mm)	II,2	3.58 ± 0.32 #	3.59 ± 0.30	3.64 ± 0.26
Frontal gummy smile	II,1	1.25 ± 0.36	0.37 ± 0.24 *	0.33 ± 0.24 *
(mm)	II,2	0.81 ± 0.27	0.22 ± 0.16 *	0.43 ± 0.18
Premolar gummy smile	II,1	1.23 ± 0.34	0.70 ± 0.35	0.26 ± 0.22 *
(mm)	II,2	0.86 ± 0.27	0.49 ± 0.26	0.26 ± 0.18
Interlabial gap	II,1	6.35 ± 0.92	4.46 ± 0.90 *	1.77 ± 0.46 * ~
(mm)	II,2	2.76 ± 0.81 #	0.91 ± 0.75 * #	0.24 ± 0.39 * #

Statistically significant differences of the least squares means are indicated as follows: *significant difference compared to T_0; ~ significant difference between T_1 and T_2; # significant difference between II,1 and II,2 at the same time point.

Table 3. Estimated means and standard errors for the cephalometric analysis obtained through a linear mixed effects model

		T_0	T_1	T_2	T_3
SNA (°)	II,1	78.98 ± 1.01	80.27 ± 1.16	79.67 ± 1.18	80.15 ± 1.20
	II,2	80.47 ± 0.75	80.75 ± 0.88	80.63 ± 0.89	81.10 ± 0.91
SNB (°)	II,1	75.45 ± 1.22	78.00 ± 1.19 *	77.38 ± 1.32 *	75.70 ± 1.06 + ~
	II,2	74.68 ± 0.90	78.37 ± 0.92 *	77.47 ± 1.00 * +	77.20 ± 0.79 *
ANB (°)	II,1	5.74 ± 0.74	2.27 ± 0.46 *	2.70 ± 0.67 *	3.32 ± 0.88 *
	II,2	5.48 ± 0.55	2.31 ± 0.35 *	3.28 ± 0.50 * +	3.51 ± 0.66 * +
FHMP (°)	II,1	28.28 ± 1.75	25.86 ± 1.34	27.10 ± 1.72	28.48 ± 1.42 +
	II,2	22.24 ± 1.30 #	23.03 ± 1.02	24.78 ± 1.30 * +	24.73 ± 1.10 * +
Facial angle (°)	II,1	83.50 ± 1.38	89.59 ± 1.00 *	88.93 ± 0.98 *	86.08 ± 1.01 + ~
	II,2	88.63 ± 1.04 #	89.41 ± 0.78	88.56 ± 0.75 +	89.88 ± 0.75 #
N-ANS:ANS-Me	II,1	0.77 ± 0.02	0.79 ± 0.02	0.79 ± 0.02	0.78 ± 0.03
	II,2	0.82 ± 0.02	0.80 ± 0.02	0.80 ± 0.02	0.77 ± 0.02 *

Statistically significant differences of the least squares means are indicated as follows: *significant difference compared to T_0; +significant difference compared to T_1; ~ significant difference between T_2 and T_3; # significant difference between II,1 and II,2 at the same time point.

Figure captions

Figure 1: Schematic drawing of the cephalometric landmarks used for the angular and ratios analysis at the different time points.

Figure 2: Trend over time for the direct measurements. (D = diagnosis, T = time, D*T = Diagnosis-time interaction, p-values < 0.05 are considered statistical significant)

Figure 3: Trend over time for the cephalometric analysis. (D = diagnosis, T = time, D*T = Diagnosis-time interaction, p-values < 0.05 are considered statistical significant)

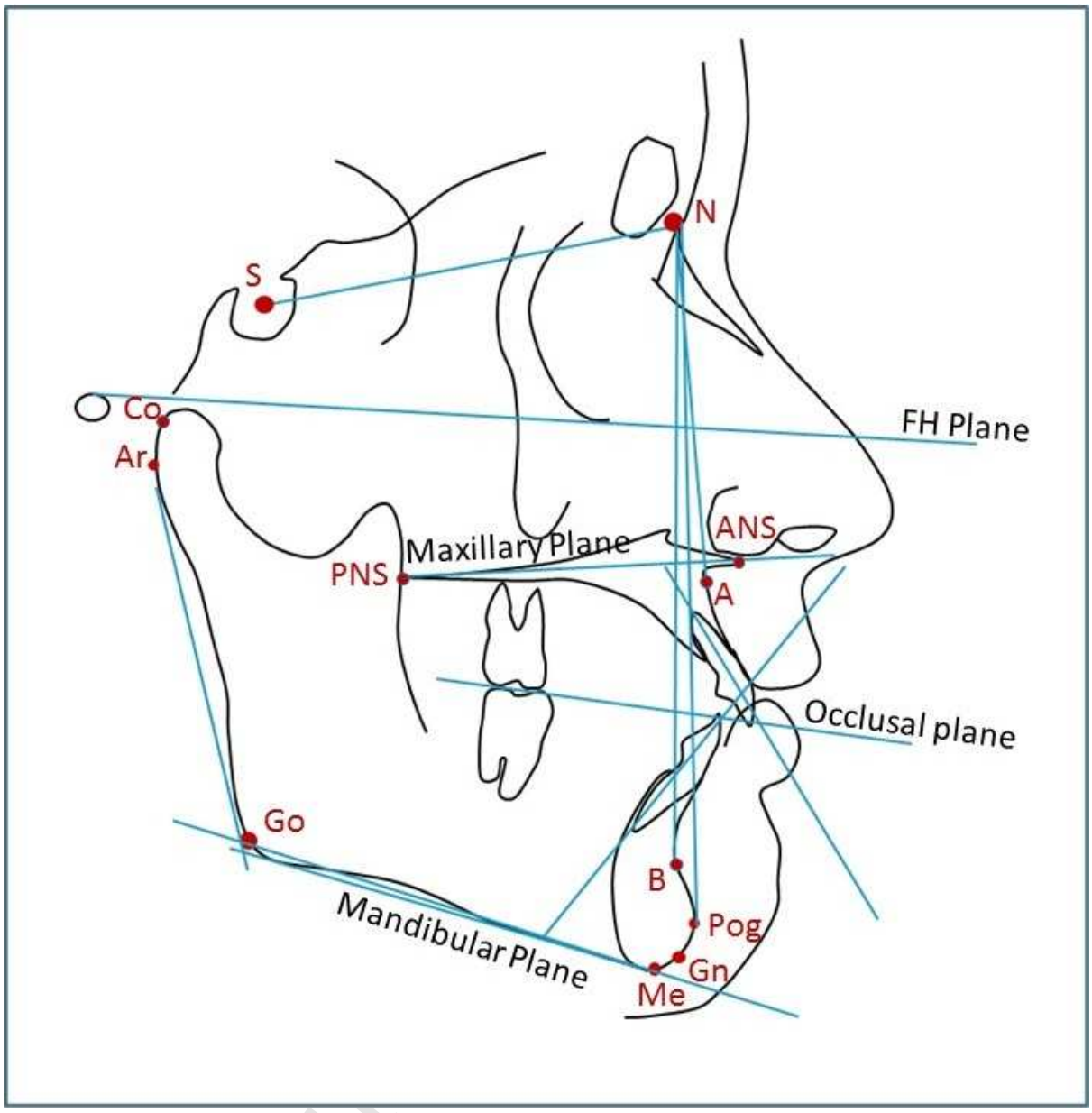
N
S
Co
Ar
FH Plane
ANS
Maxillary Plane
PNS
A
Occlusal plane
Go
B
Pog
Gn
Me
Mandibular Plane

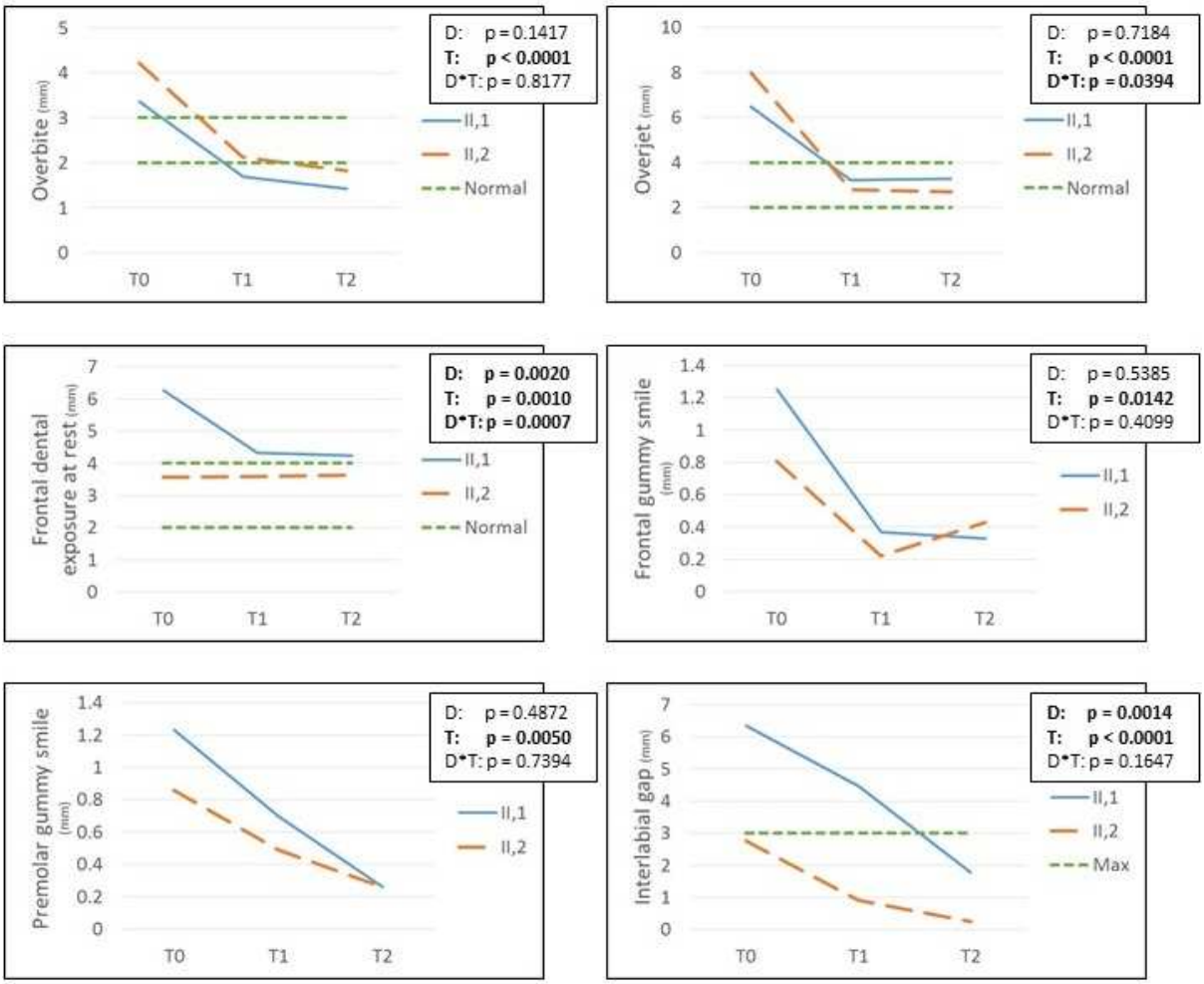
Overbite (mm)
D: p = 0.1417
T: p < 0.0001
D*T: p = 0.8177
II,1
II,2
Normal
Overjet (mm)
D: p = 0.7184
T: p < 0.0001
D*T: p = 0.0394
Frontal dental exposure at rest (mm)
D: p = 0.0020
T: p = 0.0010
D*T: p = 0.0007
Frontal gummy smile (mm)
D: p = 0.5385
T: p = 0.0142
D*T: p = 0.4099
Premolar gummy smile (mm)
D: p = 0.4872
T: p = 0.0050
D*T: p = 0.7394
Interlabial gap (mm)
D: p = 0.0014
T: p < 0.0001
D*T: p = 0.1647
Max
T0
T1
T2

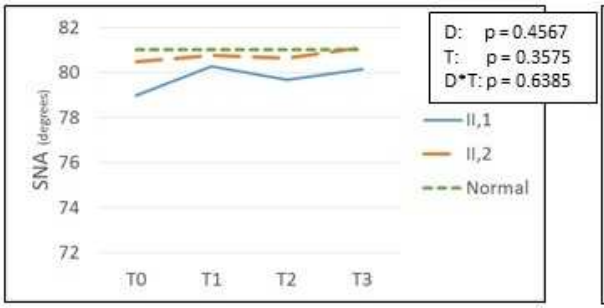
SNA (degrees)
82
80
78
76
74
72
T0
T1
T2
T3
D: p = 0.4567
T: p = 0.3575
D*T: p = 0.6385
II,1
II,2
Normal

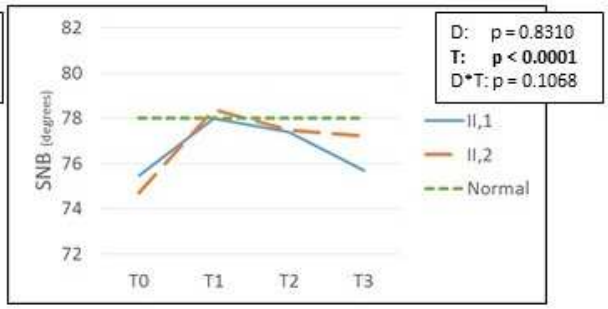
SNB (degrees)
82
80
78
76
74
72
T0
T1
T2
T3
D: p = 0.8310
T: p < 0.0001
D*T: p = 0.1068
II,1
II,2
Normal

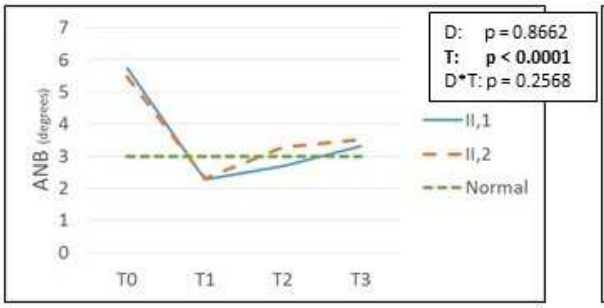
ANB (degrees)
7
6
5
4
3
2
1
0
T0
T1
T2
T3
D: p = 0.8662
T: p < 0.0001
D*T: p = 0.2568
II,1
II,2
Normal

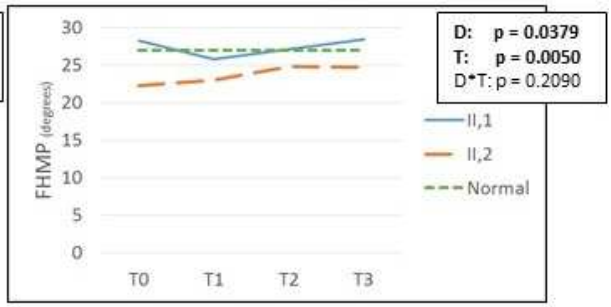
FHMP (degrees)
30
25
20
15
10
5
0
T0
T1
T2
T3
D: p = 0.0379
T: p = 0.0050
D*T: p = 0.2090
II,1
II,2
Normal

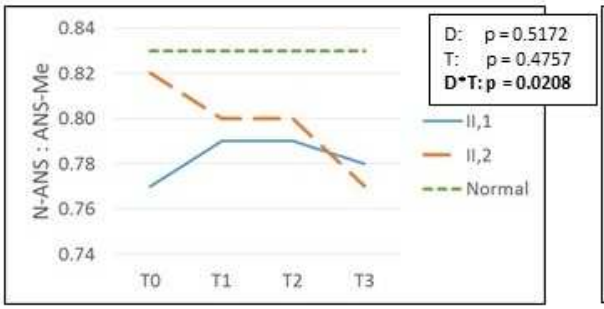
N-ANS : ANS-Me
0.84
0.82
0.80
0.78
0.76
0.74
T0
T1
T2
T3
D: p = 0.5172
T: p = 0.4757
D*T: p = 0.0208
II,1
II,2
Normal

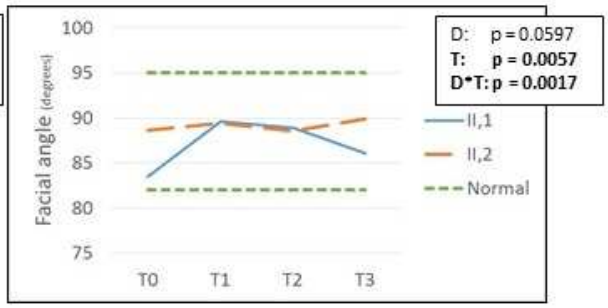
Facial angle (degrees)
100
95
90
85
80
75
T0
T1
T2
T3
D: p = 0.0597
T: p = 0.0057
D*T: p = 0.0017
II,1
II,2
Normal