

OPEN

A New, Promising Experimental Ossicular Prosthesis: A Human Temporal Bone Study With Laser Doppler Vibrometry

*Anton Rönnblom, †Kilian Gladiné, ‡Anders Niklasson, §||Magnus von Unge, †Joris Dirckx, and *Krister Tano

*Department of Clinical Science, Otorhinolaryngology/Sunderby Research Unit, Umeå University, Umeå, Sweden; †Department of Physics, University of Antwerp, Antwerp, Belgium; ‡Department of Clinical Science, Otorhinolaryngology, Umeå University, Umeå, Sweden; §Department of Otorhinolaryngology, Akershus University Hospital and University of Oslo, Oslo, Norway; and ||Region Västmanland – Uppsala University, Centre for Clinical Research, Hospital of Västmanland, Västerås, Sweden

Objective: We compared the sound transmission using different types of total ossicular replacement prostheses (TORP); we then studied the performance of a new TORP that we designed inspired by the columella, the single ossicle found in birds.

Methods: Stapedial vibrations were measured on nine freshly frozen human temporal bones with laser Doppler vibrometry. We then compared the performances of eight common TORP positions or designs as well as the new silver prototype of bird-type prosthesis, designed also according to our digital holography patterns of the human tympanic membrane (TM).

Results: The TORPs placed in lateral contact with both the TM and the malleus handle outperformed, at most frequencies, those placed only in contact with the TM.

The new bird-type prosthesis performed equally well or better than all other prostheses.

Conclusion: If the malleus handle can be retained when placing a TORP, the best sound transmission can be achieved by placing the TORP in contact with both the distal part of the malleus handle and the TM. The good performance of our bird-type prosthesis suggests that there is still room for future improvement of prosthesis design to further optimize hearing outcomes after surgery.

Key Words: Digital holography—Human temporal bone—Laser Doppler vibrometry—Ossicular prosthesis—TORP.

Otol Neurotol 41:537–544, 2020.

Ossiculoplasty is one of the most common otosurgical procedures aimed at restoring hearing. In previous studies we described a method using laser Doppler vibrometry (LDV) and freshly frozen human temporal bones (TBs) to compare the efficacy of different types of ossiculoplasty (1,2). This method was also used to identify the best way to place partial ossicular replacement prostheses (PORPs), often used in middle ear surgery when there is an intact and mobile stapes (2) (Fig. 1B).

Address correspondence and reprint requests to Anton Rönnblom, M.D., Västervägen 8, 95433 Gammelstad, Sweden; E-mail: anton.ronnblom@umu.se

No financial support than from the County of Norrbotten in Sweden has been received.

The authors disclose no conflicts of interest.

This is an open access article distributed under the terms of the Creative Commons Attribution-Non Commercial-No Derivatives License 4.0 (CCBY-NC-ND), where it is permissible to download and share the work provided it is properly cited. The work cannot be changed in any way or used commercially without permission from the journal.

DOI: 10.1097/MAO.0000000000002556

A total ossicular replacement prosthesis (TORP) is an alternative used especially when the superstructures of the stapes are damaged or completely missing. In this procedure, the stapes footplate is connected directly to the tympanic membrane (TM) and/or to the malleus (Fig. 1C).

Many types of prefabricated PORPs and TORPs are available on the market, and prostheses can also be sculptured from ossicles and cortical bones by a surgeon. However, controlled, randomized clinical trials to identify the best options are hard to perform due to a number of variables that are difficult to control, such as level of experience and skills of the surgeon, individual anatomical variations, and varying healing processes (3,4).

LDV has been used for many years to assess stapes vibration velocity and thus determine sound transmission in human TBs, which can then be translated into hearing loss function (5–8).

Mammals, including humans, are the only class of vertebrates that have three middle ear ossicles. Amphibians, reptiles, and birds, on the other hand, have only one ossicle: the columella. At frequencies up to 4 kHz, the

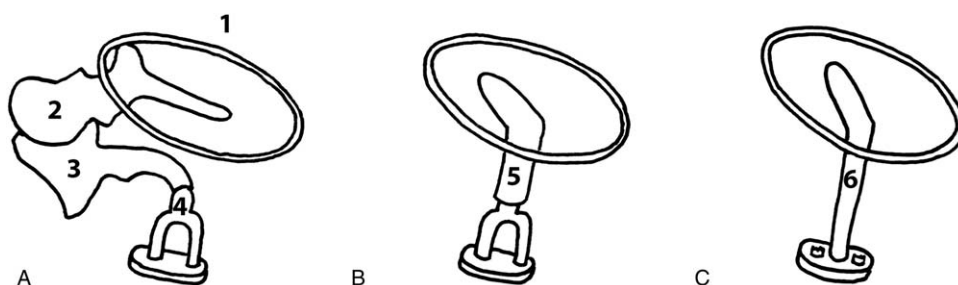


FIG. 1. A, Normal ossicular chain. 1, Circle marking the outline of the TM; 2, malleus; 3, incus; 4, stapes. B, Placement of a partial ossicular replacement prosthesis (PORP) in the presence of an intact and mobile stapes. 5, PORP. C, Placement of a total ossicular replacement prosthesis (TORP), in those cases in which the superstructures of the stapes are damaged or completely missing. 6, TORP.

hearing ability of birds is comparable to that of man (9). Therefore, in our study we decided to include a comparison with a prosthesis inspired by the avian single-ossicle system. We thus manufactured a silver TORP based on the shape of the columella from long-eared owls. The TORP was then adapted to fit the human middle ear anatomy.

Digital holography has been previously used for visualizing vibration patterns and amplitudes of the TM at different frequencies (10–13). In the present study, we used digital holography recordings of a human TM as a reference for designing the silver TORP. This was done to match the TORP contacts with the TM to those areas that showed the highest amplitudes in the digital holography recordings.

The aim of the present study was to compare, using the previously described LDV method, different TORPs commonly used in ossiculoplasty (1,2); this way, we aimed at assessing which TORP setup shows the best sound transmission. In addition, we aimed at studying the function of a novel TORP design, inspired by the bird columella and adapted according to the TM vibration pattern, and comparing it to the conventional TORP designs.

METHODS

For this study, 11 freshly frozen TBs were assessed by otomicroscopy during dissection. Two TBs were excluded from the study due to signs of disease: one had probable otosclerotic foci and one had middle ear adhesions. The remaining nine TBs had apparently normal middle ears, without visible or measurable defects and were therefore included in the study. All bones were stored below -20°C before the measurements.

The TBs were donated for research, and ethical approval was given by Umeå University, dnr 2014-352-31.

LDV on Freshly Frozen Human Temporal Bones

While the specimen was still frozen the cochlea was cut away, thus exposing the medial side of the stapes footplate, where a reflective patch was then placed. The velocity of the vibrations was measured perpendicularly to the medial side of the stapes footplate by LDV. An access to the middle ear was created by drilling a hole through the tympanic tegmen in a middle fossa-like approach. The TBs were thawed and, before measurement, an earphone speaker and a microphone were screwed onto the *planum mastoideum* over the external ear

canal (EEC) and sealed with elastic paste (Otoform AKX). During all manipulations of the ossicular chain with the different TORPs, the TM was kept intact. During the LDV measurements the stapes footplate was kept moistened with saline solution. Our previous article describes this procedure in detail (2).

Only one alteration to the previously described method was made: the cartilaginous part of the EEC was removed. This did not change the distance between the microphone and the TM. The rationale was that we noted a small variation in the velocity peak at approximately 4 kHz. After the removal of the cartilage and adjacent soft tissues the baseline recordings showed less interindividual variation.

Digital Holography

The shape, structure, and surface motion of the TM have been reported in several published works. We made digital holographic measurements on a TB prepared similarly to what described by Cheng et al. (11). We then measured the TM displacement induced by sound stimuli and how it varied over a frequency range of 0.05 to 12.80 kHz, using the setup as described by De Greef et al. (13).

Ossicular Prostheses

Nine different TORPs were sculptured from ossicles or cortical skull bone. These are referred to as bone TORPs (Fig. 2).

The prefabricated titanium prostheses we used were the following: TORPs of various lengths, in order to get the best fit (TTP Tuebingen total Prosthesis, nr 3 in Fig. 2), and TORPs with a hook of various lengths for malleus and TM contact (MNP Malleus notch total Prosthesis, nr 5 in Fig. 2). Plastic templates, taken from the Multifunctional AC sizer disk, initially intended for size measurement but used as a TORP in the present study (nr 2 in Fig. 2). All prefabricated prostheses were from Heinz Kurz Medizintechnik, Dusslingen, Germany.

Five silver, custom-made, bird-type prostheses were manufactured for this study (by AR) under a surgical microscope and using a combination of gold smithing and otosurgical tools. This type of prostheses was shaped as a rigid model of the owl's bony columella and cartilaginous extra-columella; however, its angle in the middle ear and its position on the TM is more similar to a classical TORP (Fig. 3). The prosthesis has a relatively strong coupling to the malleus handle and its three protrusions stretch out to lightly touch three "active" areas of the TM, as shown by digital holography. The birds we assessed for prosthesis modeling (chicken, mallard duck, ostrich, and long eared owl) all had ossicles with great similarities. The ossicle of the owl had good

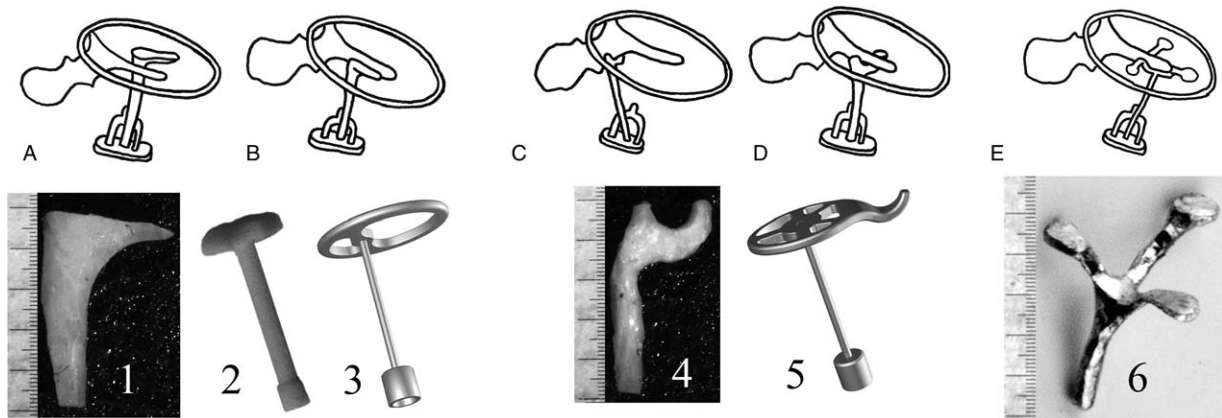


FIG. 2. Some of the prostheses that were used (1–6) and some of their applications (A–E). A, Total ossicular replacement prosthesis (TORP) placed without contact to the malleus. B, TORP placed in contact with both the tympanic membrane (TM) and the side of the malleus. TORPs 1–3 were used in positions (A) and (B). C, Custom-made bone TORP (4) placed in contact with the malleus neck. D, TORP with both TM and malleus contact (4,5). E, New, silver, bird-type TORP with a malleus and TM contact more extensive than that of the prosthesis in “D” (6). The long vertical lines next to the prosthesis measure 1 mm.

proportions and could with least alteration allow a malleus handle to be fit inside the cartilage tripod.

Silver was chosen for these prototypes due to its favorable molding properties.

LDV measurements were performed on each TB with an intact ossicular chain and were repeated after the removal of the incus and after ossicular reconstruction. Each type of reconstruction was made as “best fit” according to the surgeon’s evaluation; also, to avoid an increase in tension, particular care was put in choosing prostheses of adequate lengths. After the LDV measurement, the TORP was removed and adjusted before the next measurement was performed. When compiling

the data, we used the best result for each prosthesis placement. Measurements of the same prosthesis generally displayed only minor variations, but could vary up to 5 to 10 dB, due to inferior angulation or, bad connection.

The surgeons AR, AN, and KT all have clinical experience as ear surgeons and have experience from similar LDV measurements on TBs in previous studies (1,2). The order in which the different prostheses were tested was randomly chosen. The surgeons who performed the “operations” did not perform the measurements, and the physicist who performed the measurements had no experience in otosurgical techniques.




FIG. 3. A, Cast in bronze of an ossicle from a long-eared owl; the model, created by AR, is based on a high-resolution 3D scan (scale of 10:1). The rounded mass at the base is the equivalent of the stapes footplate, which in birds is integrated with the ossicle. The upper tripod in the owl is cartilaginous and is connected to an outward bulging tympanic membrane (TM). The entire ossicle, from base to tip, measures 5 mm. B and C, One of the silver prostheses made by AR, depicted from two different angles. The tripod is shaped to fit a malleus handle, and the extended arms are made to fit flat against the TM. The long vertical lines between (B) and (C) measure 1 mm. Note the different angulation between the connection of the shaft to the tripod in the owl ossicle and in our TORP.

In order to avoid the risk of damaging the footplate, the stapes superstructure was left intact during the measurements, and the TORPs were placed in parallel with it (Fig. 2).

When all measurements that required a malleus in situ were completed, the malleus was removed. Then, a long bone TORP was inserted, and measurements were performed on TBs with the TM bulging outward, in order to simulate the TM position in birds. This is contrary to the TM position in humans, in whom the TM is funnel-shaped with the apex pointing medially.

RESULTS

All prostheses were weighed and photographed. The average weight of the prostheses we used is here reported as mean (standard deviation): bone TORPs weighted 9.3 mg (2.9 mg); titanium Kurtz TORPs weighted 4.5 mg (0.3 mg), but 5.3 mg (0.3 mg) with the addition of cartilage; Kurtz plastic TORPs weighted 2.4 mg (0.1 mg); silver prostheses weighted 24.0 mg (4.1 mg).

Digital Holography

Our digital holography measurements were in line with those reported in previous publications (10,11). The results indicated that the highest amplitudes were recorded at the dorsal part of the TM at frequencies < 1 kHz, and more complex movement patterns were recorded as the frequencies increased.

Laser Doppler Vibrometry

The LDV results are here presented as graphs showing the ratio (expressed in dB) between the stapes footplate velocity amplitudes using different prostheses, and the stapes velocity amplitudes in the intact middle ear, for each specific TB (Figs. 4–6). In these graphs (Figs. 4–6), each colored line indicates the mean of all measurements with that specific prosthesis type, and the upright bars of the same color indicate the standard error (the standard deviation divided by the square root of the amount of measurements). The results from the intact middle ear correspond to the 0-dB line (Figs. 4–6).

After we removed the incus, the velocity was reduced by approximate 35 dB in the low-, 40 dB in the mid-, and 25 dB in the high-frequency ranges (Fig. 4A). Repeated measurements with the same prosthesis in the same position did not show variations in the velocity curve.

All TORPs in contact with the TM showed similar results regardless of the TORPs' material (Fig. 4A). TORPs in contact with both TM and malleus also showed similar velocities, with an advantage in the higher frequencies for the bone TORPs (Fig. 4B).

A TORP can be placed on different areas under the malleus. In the present study, three specific places under the malleus were evaluated: the malleus neck, the proximal malleus handle (just distal to the tendon), and the distal part of the malleus handle. The latter placement was along the handle and toward the umbo but not under it, due to the unfavorable angle of the prosthesis. Distal placement resulted in better velocities at most frequencies (Fig. 6). Additionally, both distal and proximal placements performed, on average, 10 dB better than

the neck placement at frequencies < 6 kHz (data not shown).

After we completed all the measurements requiring the malleus in place, we removed the malleus and thus obtained a TM in a "flat position," without its natural tension. When placing TORPs with a loose fit to this "flat" TM, we recorded worse velocities than those recorded with TORPs in contact only with the TM and in the presence of a malleus. However, when a long prosthesis was inserted, thus resulting in an inverted-shaped TM, we recorded similar velocities (except at 3 kHz) as those recorded in the presence of a malleus and with TORPs in contact only with the TM (Fig. 5).

At most frequencies, the different TORPs in contact with both the TM and malleus handle outperformed the TORPs with the TM-only contact. A subgroup that stood out was that of the bone TORPs with distal contact near the umbo: these performed better than the other normal TORPs. The bird-type prosthesis performed similarly to the distal bone TORPs (Fig. 6).

DISCUSSION

In the present study we showed that TORPs placed in contact with both the TM and the malleus handle give a better sound transmission than those in contact only with the TM. This is in accordance with our previous findings on PORPs (2), and similar results were also reported over 50 years ago (14). It thus seems to be beneficial to use the malleus, when present, to achieve a better sound transmission. The use of the malleus for TORP stability during healing is common in the clinical practice. However, the best way to place such a prosthesis has been the subject of several studies. The umbo has the greatest displacement in response to sound pressure, and thus, in theory, it could represent an optimal placement (7). Another study reported the advantages of a neck placement rather than a placement under the handle or the umbo (15). Mid-malleus placement was also found to be superior in one study (16).

The present study supports the hypothesis that to obtain the best hearing results the placement of the prosthesis should involve contact with the distal part of the malleus handle toward the umbo.

A weakness of this study is the fact that, when keeping the pre-existing TM funnel shape, adapting and placing the custom sculptured bone TORP according to the anatomy of each specimen was easier than placing the prefabricated titanium TORP. The latter is generally fitted onto a flatter surface. This might be part of the reason for the difference in velocity responses between the titanium TORP malleus and bone TORP malleus prostheses (Fig. 5B). Such difference was not observed with the TM-only contact prosthesis (Fig. 5A).

Another reason could be that, due to their adaptable shape, the custom-made bone TORPs allowed more distal placement toward the umbo. These prostheses did provide excellent sound transfer in "best fit" but, due to the angulation, they were also the most sensitive

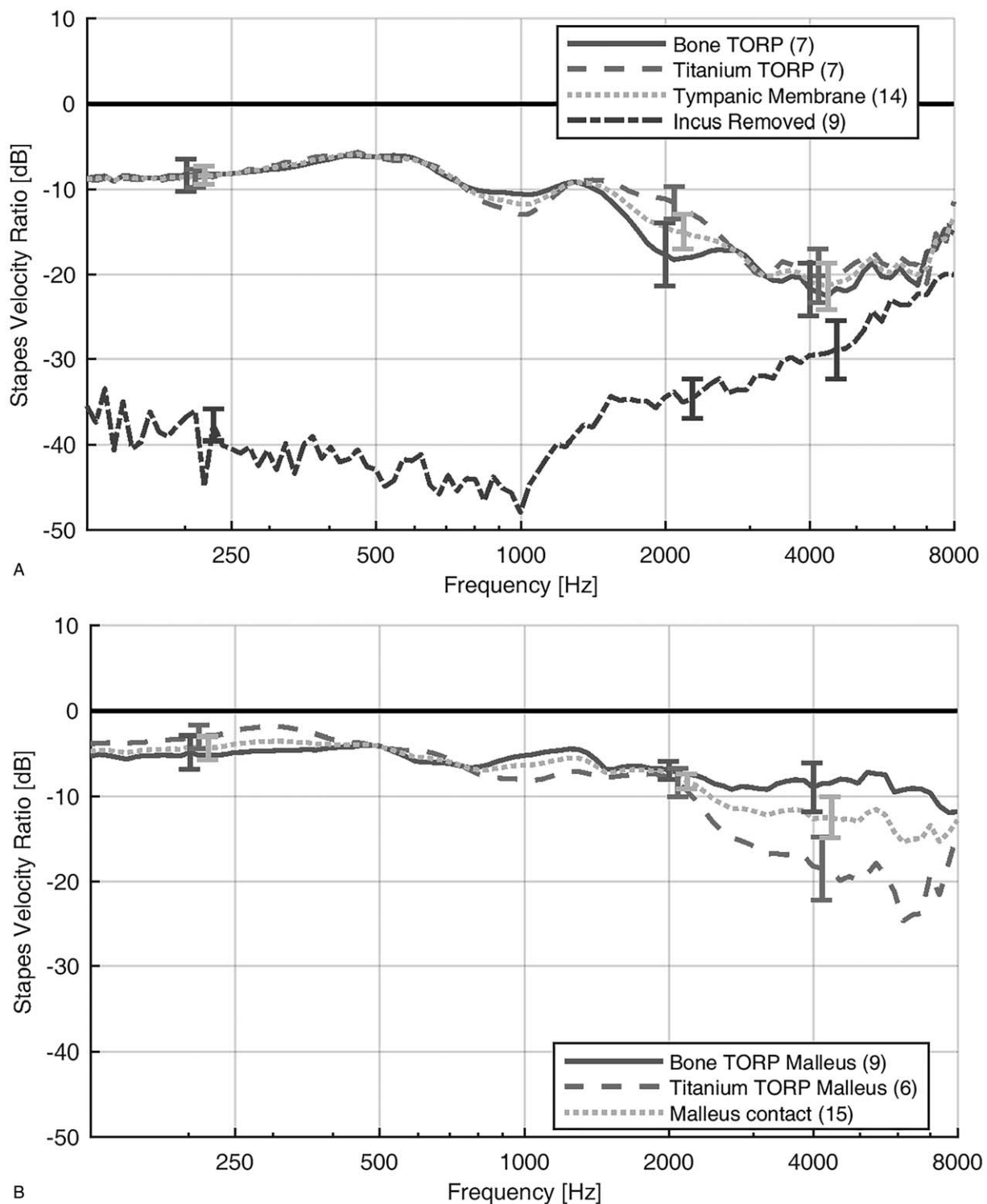


FIG. 4. Average laser Doppler vibrometry (LDV) measurements (expressed as ratios, see the main text). The results from the intact middle ear correspond to the black 0-dB line and the dotted yellow line is the mean of all prostheses measured. The number of prostheses measured for each type is reported within brackets. *A*, It shows prostheses in contact only with the tympanic membrane (TM). The red line shows the results of the prefabricated titanium total ossicular replacement prostheses (TORPs), and the blue line represents the bone TORPs. The lighter plastic prostheses followed the same pattern (data not shown). The “incus removed” group represents the sound transfer to the stapes footplate when the ossicular chain is completely interrupted. *B*, Average LDV measurements of prostheses in contact with both malleus and TM. The blue line shows the results obtained with the bone TORPs, and the red line shows those obtained with titanium TORPs.

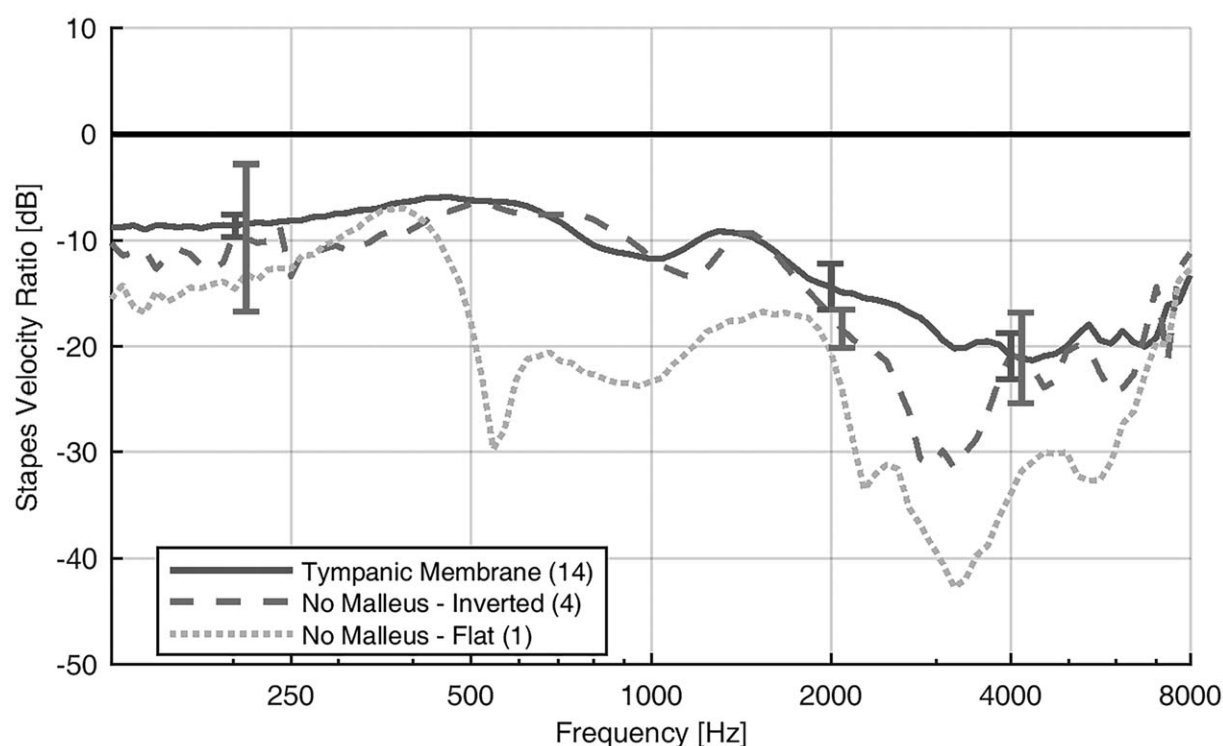


FIG. 5. Average LDV measurements recorded in the following conditions: in the presence of a malleus and with a TORP in contact only with the TM (blue line); after the removal of the malleus (thus obtaining a TM in a flat position) and after the placement of a TORP under the “flat” TM (yellow line); after inserting a long prosthesis, thus creating a bird-type inverted TM (red line).

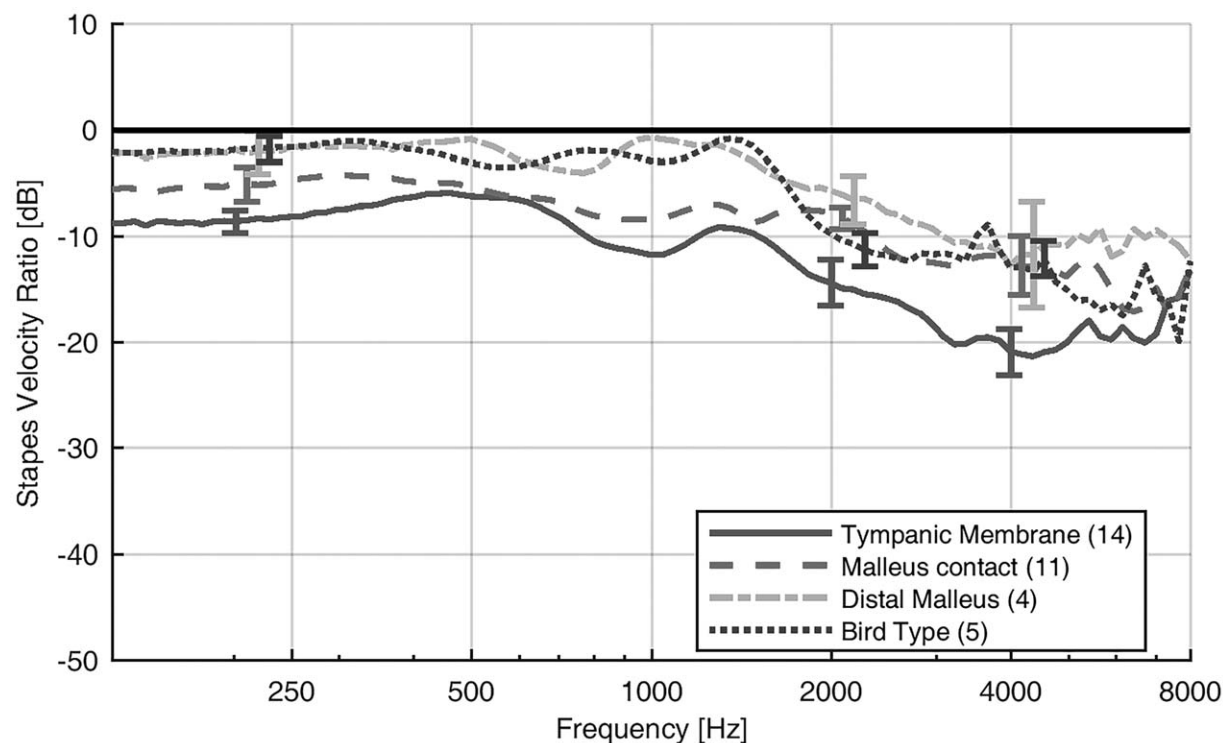


FIG. 6. Comparison of the average LDV measurements recorded for different types of TORPs. All the prostheses in contact with both the TM and the malleus handle (except for the distally placed bone TORPs and bird-type prosthesis) have been here added together under the name “Malleus contact,” since they all showed similar LDV results. The “Tympanic Membrane” group represents the TORPs placed toward the TM without contact to the malleus handle. The “Distal Malleus” group represents the bone TORPs with TM and distal malleus contact. The “Bird-Type” group represents the bird-type prostheses.

type. In fact, their performance greatly declined with only minor position adjustments. It has previously been shown that angulation of a prosthesis can significantly affect the result of the reconstruction (17).

A limitation in the present study is that we did not perform holography measurements to evaluate how the different prostheses affected the TM movement patterns. The motion of the TM surface and how it varies due to sound stimulation at different frequencies is well documented (11–13,18). However, how these movements relate to middle ear sound transmission has been theorized (11) and, to our knowledge, is not fully understood. It has been demonstrated that placing a prosthesis on the surface of the TM leads to significant reductions in the motions of the TM surface adjacent to the prosthesis (18,19) but has little effect on the middle ear sound transmission (18). Since our previous PORP study showed that connection with both the TM and the malleus handle was beneficial (2), we here wanted to investigate if a more extensive TM contact has any advantages. The bird-type prosthesis was made to have a close fit to the malleus handle and a light touch on the TM at three peripheral sites (Fig. 2E). The good results obtained with the bone TORP placed near the umbo and the bird-type prosthesis suggest that TM and distal malleus contact are important, but also that several TM contact points do not seem to improve sound transmission. The bird-type prosthesis provides a stable construction that, without slipping or adverse angulation, allows for both TM and distal malleus handle contact.

LDV measurements determining stapes vibration velocity to assess the sound transmission on freshly frozen human TB have been used in several articles both for evaluation of middle ear pathology and for comparisons between treatment options (5–8). Our previously described TB model (1,2) proved to be an excellent tool for the evaluation of different ossiculoplasty methods and prostheses in vitro. Some advantages of this model are the following: the TM is kept intact; one can obtain perpendicular measurements of the stapes vibrations; and the model gives good access to the middle ear for repeated measurements. With this method, many different prostheses can be compared with one repeatable procedure. Thereby, the number of acoustically suitable treatment options can be reduced, which allows future clinical studies to focus only on the most appropriate alternatives. In the present study, we developed the LDV method by standardizing the amount of soft tissue in the EEC. Since the LDV measurements of the different prostheses were always compared to the normal curve of the same TB, the amount of soft tissue in the EEC should have only little effect on the results. Nevertheless, for further studies using this TB model, we recommend the removal of all soft tissue distal to the bony ear canal. A weakness in this model is that normal healing cannot be evaluated, and it is therefore not certain that the bird-type prosthesis would be tolerated.

In the present study, as well as in our previous report (2), the highest velocities in the low- to mid-frequencies

were obtained with a loosely fitted prosthesis rather than with the firmer fitted ones. However, the velocities in the high-frequency range were lower. Similar results that favor a loose fit have been reported in multiple studies (14,17,19). In an attempt to simulate the healing process after surgery, we previously created a firmer fit by fixating the prostheses with glue (2). With the glue, we obtained increased velocities at the higher frequencies.

In the absence of a malleus, similar velocity responses were obtained both when the TM was funnel shaped (normal form) and when it was inverted (as in birds). This finding may be of importance because the shape of the TM is often flatter or inverted when ossiculoplasty is performed in patients lacking the malleus handle. Thus, in the clinic, when the malleus is absent or needs to be removed, the final shape of the TM covering the prosthesis might not be that significant as long as the TM can vibrate freely.

Removing the malleus from the TM is difficult and generates a risk of altering the fiber structure of the TM, or even perforating it. Therefore, this step was done after all other measurements had been performed. TBs with damaged TMs were not used in the measurements.

In the TB model, the flat position of the TM (Fig. 5) was flaccid, with poor sound transmission. However, in patients after otosurgery a TM in flat position often has normal tension.

The shape and material of the bird-type silver prosthesis made them heavier than their counterparts.

Prosthesis weight did not seem to affect the velocity recordings, although the weight of the TORPs we used ranged from 2.4 mg (plastic material) to 24.0 mg (silver). Similarly, Rosowski et al. (20) predicted that the mass of the prostheses had only a small impact on sound transmission.

However, it has been shown that when masses up to 20 mg were added to a prosthesis, sound transmission was significantly and negatively affected at the higher frequencies (17). A bird-type prosthesis made in a lighter material, such as titanium, might therefore perform better at these frequencies.

The ostrich middle ear was previously used as a comparison to human TBs in an LDV study investigating possible improvements for future TORP development (21). In that study it was found that the main protective mechanism of the ostrich middle ear, under quasistatic stress, was a buckling movement at the intracolumellar connection between the bone base and cartilage tripod of the single-ossicle system. This suggested that the risk of inner ear damage could be reduced with a TORP containing an elastic element (21). The experimental prosthesis in the present study was made with a rigid material to evaluate the sound transferring capabilities of its shape, in comparison with the existing rigid prostheses. A prosthesis with the addition of an elastic element could be also an option for future studies.

The general designs of PORPs and TORPs have not changed over the last 20 years or even more. Our results

show that not only does the bird-type silver prosthesis seem to be equal or even better than the existing prosthesis, but it also has the theoretical advantage of using the existing malleus as a support and protection against the protrusion of the prosthesis. Thereby, protective cartilage covers on the lateral end of the prosthesis toward the TM, which are used with other types of titanium prostheses, might be no longer needed. If our results are translated to the clinical setting, the potential advantages could be a simpler, and thus faster surgery, with less tissue trauma (due to the omitted cartilage harvesting) and better hearing outcome. Furthermore, due to a better visibility in the absence of the cartilage, the risk of missing the formation of cholesteatoma or other middle ear pathologies might be reduced in the clinic. Even at present, some surgeons use the existing titanium prosthesis without the recommended cartilage, due to the abovementioned advantages, thereby probably also increasing the risk of protrusion of the prosthesis (22).

More studies are required before the bird-type prosthesis can be implemented clinically. Our in-vitro LDV findings should be confirmed, and clinical trials should be performed to ascertain long-term stability with this novel type of prosthesis. In a clinical trial, titanium would be a logical choice of material due to its light weight and its well-established function in this type of application.

CONCLUSION

TORPs that are in contact with both the TM and the distal parts of the malleus provide a better sound transmission. This finding suggests that, when possible, surgeons should preserve and use the malleus as to obtain the best hearing outcomes. Also, our data from the bird-type prosthesis suggest that prosthesis design may be further developed to optimize hearing outcomes after surgery.

Acknowledgments: The authors thank Viviana Moroso (M.Sc., Ph.D.) of MV Medical Writing (Luleå, Sweden) for providing editorial support, in accordance with Good Publication Practice (GPP3) guidelines (<http://www.ismpp.org/gpp3>).

REFERENCES

- Niklasson A, Ronnblom A, Muyschondt P, Dirckx J, von Unge M, Tano K. Ossiculoplasty on isolated malleus fractures: A human temporal bone study using laser doppler vibrometry. *Otol Neurotol* 2016;37:895–901.
- Niklasson A, Gladine K, Ronnblom A, von Unge M, Dirckx J, Tano K. An optimal partial ossicular prosthesis should connect both to the tympanic membrane and malleus: A temporal bone study using laser Doppler vibrometry. *Otol Neurotol* 2018;39:333–9.
- Merchant SN, Rosowski JJ, McKenna MJ. JOTIO-H. Surgery N. *Tympanoplasty* 2003;14:224–36.
- Brackmann DE, Sheehy JL, Luxford WM. TORPs and PORPs in tympanoplasty: A review of 1042 operations. *Otolaryngol Head Neck Surg* 1984;92:32–7.
- Nakajima HH, Ravicz ME, Merchant SN, Peake WT, Rosowski JJ. Experimental ossicular fixations and the middle ear's response to sound: Evidence for a flexible ossicular chain. *Hear Res* 2005;204:60–77.
- Alian WA, Majdalawieh OF, Van Wijhe RG, Eijnell H, Bance M. Prosthetic reconstruction from the tympanic membrane to the stapes head or to the stapes footplate? A laser Doppler study. *J Otolaryngol Head Neck Surg* 2012;41:84–93.
- Goode RL, Killion M, Nakamura K, Nishihara S. New knowledge about the function of the human middle ear: Development of an improved analog model. *Am J Otol* 1994;15:145–54.
- Goode RL, Ball G, Nishihara S, Nakamura K. Laser Doppler vibrometer (LDV)—a new clinical tool for the otologist. *Am J Otol* 1996;17:813–22.
- Saunders JC, Duncan RK, Doan DE, Werner YL. The middle ear of reptiles and birds. In: Dooling RJ, Fay RR, Popper AN, editors. *Comparative Hearing: Birds and Reptiles*. New York, NY: Springer; 2000. 13–69.
- Cheng JT, Aarnisalo AA, Harrington E, et al. Motion of the surface of the human tympanic membrane measured with stroboscopic holography. *Hear Res* 2010;263:66–77.
- Cheng JT, Hamade M, Merchant SN, Rosowski JJ, Harrington E, Furlong C. Wave motion on the surface of the human tympanic membrane: Holographic measurement and modeling analysis. *J Acoust Soc Am* 2013;133:918–37.
- Khaleghi M, Lu W, Dobrev I, Cheng JT, Furlong C, Rosowski JJ. Digital holographic measurements of shape and 3D sound-induced displacements of Tympanic Membrane. *Opt Eng* 2013;52:101916.
- De Greef D, Soons J, Dirckx JJJ. Digital stroboscopic holography setup for deformation measurement at both quasi-static and acoustic frequencies. *Int J Optomechatron* 2014;8:275–91.
- Elbrond O, Elpern BS. Reconstruction of ossicular chain in incus defects. An experimental study. *Arch Otolaryngol* 1965;82:603–8.
- Puria S, Kunda LD, Roberson JB Jr, Perkins RC. Malleus-to-footplate ossicular reconstruction prosthesis positioning: Cochleoves-tibular pressure optimization. *Otol Neurotol* 2005;26:368–79.
- Asai M, Heiland KE, Huber AM, Goode RL. Evaluation of a cement incus replacement prosthesis in a temporal bone model. *Acta Otolaryngol* 1999;119:573–6.
- Nishihara S, Goode RL. Experimental study of the acoustic properties of incus replacement prostheses in a human temporal bone model. *Am J Otol* 1994;15:485–94.
- Aarnisalo AA, Cheng JT, Ravicz ME, Furlong C, Merchant SN, Rosowski JJ. Motion of the tympanic membrane after cartilage tympanoplasty determined by stroboscopic holography. *Hear Res* 2010;263:78–84.
- Ulku CH, Cheng JT, Guignard J, Rosowski JJ. Comparisons of the mechanics of partial and total ossicular replacement prostheses with cartilage in a cadaveric temporal bone preparation. *Acta Otolaryngol* 2014;134:776–84.
- Rosowski JJ, Merchant SN. Mechanical and acoustic analysis of middle ear reconstruction. *Am J Otol* 1995;16:486–97.
- Arechvo I, Zahnert T, Bornitz M, et al. The ostrich middle ear for developing an ideal ossicular replacement prosthesis. *Eur Arch Otorhinolaryngol* 2013;270:37–44.
- Pringle MB, Sunkaraneni VS, Tann N. Is cartilage interposition required for ossiculoplasty with titanium prostheses? *Otol Neurotol* 2014;35:482–8.