OA Anatomy
Open Access

Critical review

Gross Anatomy

The aortic valve and its root: the modern Babylonian tower still stands

WP Mistiaen*

Abstract

Introduction

The complexity of the aortic valve and aortic root is appreciated, especially by specialists in medical imaging and by surgeons who devise and perform aortic valve repair. However, the terminology used to describe the components of the valve differs between different specialists and even within one group of specialists. The aim of this review was to discuss the aortic valve and its root.

Discussion

The following structures need proper labelling before the root itself can be described unequivocally: valve leaflets, commissures, sinuses of Valsalva, interleaflet triangles, sinutubular junction and ventriculo-aortic junction. Especially the latter deserves attention since there is an anatomic as well as a haemodynamic junction. The difference between both junctions is the key to understand the aortic valve. Its understanding is also of vital importance for surgeons in performing durable aortic valve reparations.

Conclusion

The differences in terminology of the components of the aortic valve are probably long lasting. Therefore, a clarifying definition of every component described in any scientific manuscript should be provided.

* Corresponding Author
E-mail: wilhelm.mistiaen@uantwerpen.be

University of Antwerp, Faculty of Medicine & Health Sciences, Artesis-Plantijn University College of Antwerp, Dept. of Healthcare Sciences, J De Boeckstr. 10, 2170 Antwerp, Belgium

Introduction

The aortic valve connects the left ventricle (LV) with the arterial circulation. Its main function is ensuring a unidirectional flow of blood: it allows its movement distally during systole, while backflow during diastole is prevented[1]. The valve is more than a passive unidirectional gate: a laminar flow with minimal resistance is maintained during systole. Its superiority over biological and mechanical valve prostheses prompted several investigators to develop techniques to repair diseased aortic valves, whenever possible[2]. To understand the physiological effects of these operations and to compare their results, a set of standardised and consistent definitions of every part of the aortic valve is needed. Recently, a survey revealed that differences exist between cardiac surgeons in labelling the components of the aortic root. This is of importance, since the aortic valve is the second most frequent area of surgical intervention[3]. There is also a risk of variable agreement among untrained data abstractors. Without consistent standardised definitions, aggregate data in clinical databases should be treated with caution[4]. A description of the aortic root in this manuscript is preceded by the description of its components. The preferable terms and their alternatives are summed up in Table 1. Their orientation must also be expressed in a proper way (Table 1). The parts needing description are the leaflets, the sinuses, the sinotubular junction (STJ), the commissures and the interleaflet triangles. The most controversial part is the aortic annulus with the anatomic and haemodynamic ventriculo-aortic junction (VAJ).

Discussion

The components of the aortic root

The leaflets are thin, centrally located, free moving parts of the valve (Figures 1 and 2). This term is preferable above 'cusps'[3]. They have several components[5] including the semilunar attachment, an almost transparent belly and a crescent-shaped lunula at the full length of the free margin, which is the area of coaptation. These lunula close the LV from the aorta and carry at the centre of the nodule of Arantius[1,5–7]. The attachments transmit the stress of the leaflets to the aortic wall through collagen fibres[5]. The length of the free margin and the height of the leaflet are important parameters[6,8,9]. The maximal height of the leaflet is less than the height of the sinuses, but considerable variations between individuals have been reported[10]. Pathological retraction of leaflets makes them unsuitable for repair. However, retraction is not easy to define, and poor measurement of the height may lead to its underestimation[8]. There is no consensus of which leaflet is the largest[1,10], but the observed differences seem statistically not significant[5]. The non-coronary leaflet is exclusively fibrous, whereas both other leaflets can contain small portions of ventricular muscle[1,11]. This could play a role in arrhythmias. The right coronary leaflet attaches to the predominantly muscular region of the LV outflow tract (LVOT). The non-coronary leaflet arises exclusively from the area where the left coronary leaflet is continuous (Figure 2) with the mitral valve[9].

For citation purposes: *Mistiaen WP.* The aortic valve and its root: the modern Babylonian tower still stands. OA Anatomy 2013 Dec 01;1(3):29.

Competing interests: none declared. Conflict of interests: none declared.
All authors contributed to conception and design, manuscript preparation, read and approved the final manuscript.
All authors abide by the Association for Medical Ethics (AME) ethical rules of disclosure.

OA Anatomy
Open Access

Table 1 Names for structures

Preferable	Alternative
Aortic annulus[3]	Virtual or base annulus, VAJ
Aortic valve[3]	
Cusps only	Sinuses + triangles + STJ + attachment of the leaflets to the wall
Aortic root[3]	
- Sinuses + triangles + STJ + commissures + leaflets	- sinuses + triangles + STJ + commissures without leaflets
Leaflets[3,9,13]	Semilunar valvules[5], cusps[2,23]
Leaflet orientation[2,5]	
- Non-coronary	Posterior*, non-adjacent[9]
- Left coronary	Sinistra*, left posterior†
- Right coronary	Dextra*
Leaflet attachment	Semilunar ring, hemodynamic VAJ, crown-like ring[3]
Lunula	Lannula[5]
Semilunar attachment[5]	Hinge-lines[6,13]
Sinuses[6]; advantage of alternatives: abnormal coronary ostia	
- Non-coronary	Right posterior, posterior
- Left coronary	Left posterior
- Right coronary	Anterior
Triangles[3,6]	Trigones, intercommissural trigones or triangles, interleaflet trigone or triangle, fibrous trigones[3,5,6‡]
Orientation terms	
Proximal[5]	Basal[10,13,25]
Distal[5,13]	Ascending[9], apical[10]

*British Terminology Anatomical System.
†International Terminology Anatomica Nomenclatura.
‡The risk of confusion with the intervalvular trigones is clearly present.
STJ, sinotubular junction; VAJ, ventriculo-aortic junction.

The commissures can be defined as the place of attachment of the lunula to the aortic wall[5,12], close to the STJ (Figure 1). These commissures separate the leaflets[1] and are the most distal parts of a crown-like structure. Their fibrous tissue suspend the leaflets[5]. However, some authors consider the commissures only as the peripheral parts where the free edges of the leaflets run parallel and coapt. The majority of surgeons consider both the area of attachment and the coapting parts as commissures[3].

The sinuses of Valsalva (Figures 3 and 5) share the name with the corresponding leaflets[13]. The distal boundary is the STJ and the proximal border is the attachment of the leaflets[5].

Within the interior of the right and left coronary (also called anterior), sinuses are the right and left coronary ostia[10]. The sinuses allow coronary perfusion during diastole and prevent their occlusion during systole[6]. They also show a crescent of ventricular muscle at the base (Figure 2). The non-coronary sinus has only fibrous tissue[1,9,13]. The right coronary sinus is the largest and the left one the smallest[6,14]. The three sinuses are functionally comparable[13] and have a stress-sharing mechanism for the leaflets, which contributes to the durability of the native aortic valve[14,15]. In valve-sparing root replacement surgery, these sinuses can be reconstructed, which could improve the durability of the repair, but these procedures are not standardised[16]. There is a relation to the surrounding structures which has its importance in case of rupturing aneurysms[6].

The triangles, sometimes unjustly called trigones[3], are located between the anatomic VAJ and the semilunar attachment of the leaflets (Figures 2 and 5)[5,10,13]. The latter give the sides a parabolic shape[7]. These triangles only contain fibrous tissue and are extensions of the LVOT and reach the STJ[10] or the commissures[9]. There is a proximity between the most distal parts and the pericardial space. The triangles have a specific height, which reduces with dilated annulus. This can be corrected by annuloplasty[7].

The sinutobular junction[6] forms the distal boundary of the aortic root[5,13]. This is the location of the distal end of the attachment of the leaflets[1]. The STJ plays an integral part of the valve mechanism: dilation of the STJ leads to valve regurgitation[5,12,13]. The shape of the STJ is not perfect circular, but follows the sinuses as a trefoil[6]. Thickening and calcification of the STJ could serve as a marker of atherosclerotic disease[2,17]. The openings of the coronary arteries are closely below the STJ (Figure 2)[6].

The cardiac skeleton supports the aortic valve, which is the centrepiece (Figures 3 and 4). The aorto-mitral continuity (AMC) is located into the roof of the LV. Its fibrous tissue

For citation purposes: *Mistiaen WP.* The aortic valve and its root: the modern Babylonian tower still stands. OA Anatomy 2013 Dec 01;1(3):29.

Competing interests: none declared. Conflict of interests: none declared.
All authors contributed to conception and design, manuscript preparation, read and approved the final manuscript.
All authors abide by the Association for Medical Ethics (AME) ethical rules of disclosure.

OA Anatomy
Open Access

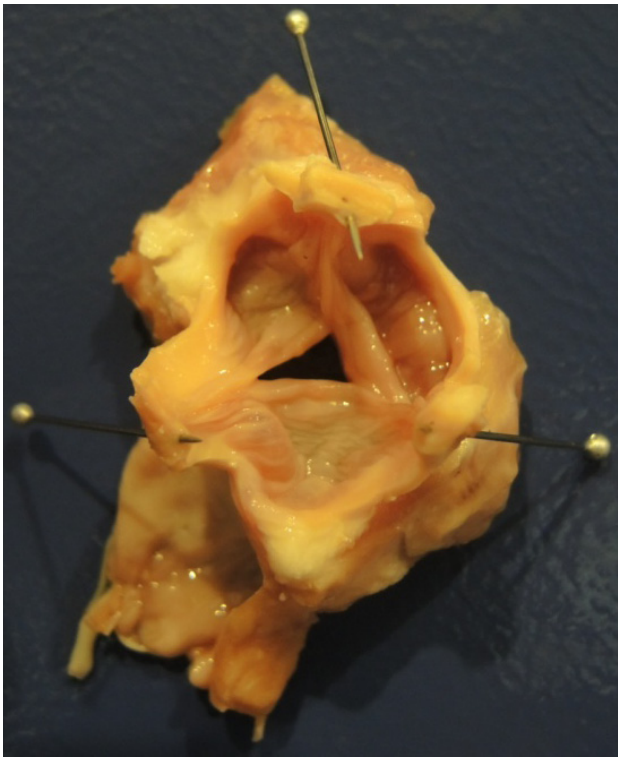

Figure 1: An unfixated aortic valve from cranial view, with the three thin and movable leaflets at its centre. The sinuses with the origins of the coronary arteries have largely been removed for the sake of visibility. The needles fix the most distal points of attachment of the leaflets, the level of the STJ. This area could be called commissures.

Figure 2: An opened aortic valve of a fixated heart in formalin. The arrows show the most proximal area of the attachment of the leaflets. The virtual line connecting these three points can be considered as the inlet of the LVOT into the aorta. The left coronary leaflet (right side) is cut and the AMC can be observed. At the cutting edge, the attachment of the ventricle to the aorta can be observed (*right arrow*). Just above, it is the continues the left ventricular muscle that is responsible for the crescent at the base of the corresponding sinus. Cranially (distally), the opening of the left coronary artery is visible. The part of the leaflets which attach most distally is often called commissure. Between the semilunar attachment are the (intersinusal) triangles. The shape of the attachments gives the sides of these triangles their parabolic shape.

extends into the anterior mitral leaflet (Figures 2 and 5). The strongest portion of the skeleton of the heart is the central fibrous body, the union of the right fibrous trigone, where the aortic, mitral and tricuspid valve connect, and the membranous part of the ventricular septum. The left trigone is smaller and located at the left angle between the two valves. Both trigones are continuous with the fibrous area between the valvar leaflets[6,10].

The conduction system is just below the aortic valve[9,10]. The atrioventriclar node is located between the septal attachment of the tricuspid valve, the orifice of the coronary venous sinus and the membranous septum. It penetrates the central fibrous body and reaches the crest of the muscular ventricular septum. Its most important relationship is the base of the triangle between the right and the non-coronary leaflets. This has its importance in transcatheter valve replacement, since the left bundle can be compromised during the procedure[9,13].

The aortic valve can be considered as a part of the aortic root[5]. Most surgeons restrict the term aortic valve to the three leaflets, the only parts that are replaced by prosthesis. Other authors also include the sinuses, the STJ and the triangles. This is supported by the view that abnormalities that do not include the leaflets (such as dilation of the STJ) render the valve incompetent[3]. The size of all parts can be measured in a reliable way by CT angiography, which has its importance as preparation for transcatheter implantation[18]. However, a standardised approach to the measurement of the aorta is needed, and features suggestive of an underlying connective tissue disorder should be recognised. Radiologists should be aware of the image limitations and clinical implications of reported measurements[19].

The aortic root is the centrepiece[1,6,9] and is wedged between the mitral and tricuspid orifice[5,6,13] and relates to all cardiac cavities[13]. The aortic root contains the commissures, annulus, triangles, sinuses, STJ and leaflets[2,5,13]. It is the continuation of the LVOT[10] and is located between the attachment of the leaflets and the STJ[10,13]. The root supports and surrounds the leaflets[13]

For citation purposes: *Mistiaen WP.* The aortic valve and its root: the modern Babylonian tower still stands. OA Anatomy 2013 Dec 01;1(3):29.

Competing interests: none declared. Conflict of interests: none declared.
All authors contributed to conception and design, manuscript preparation, read and approved the final manuscript.
All authors abide by the Association for Medical Ethics (AME) ethical rules of disclosure.

OA Anatomy
Open Access

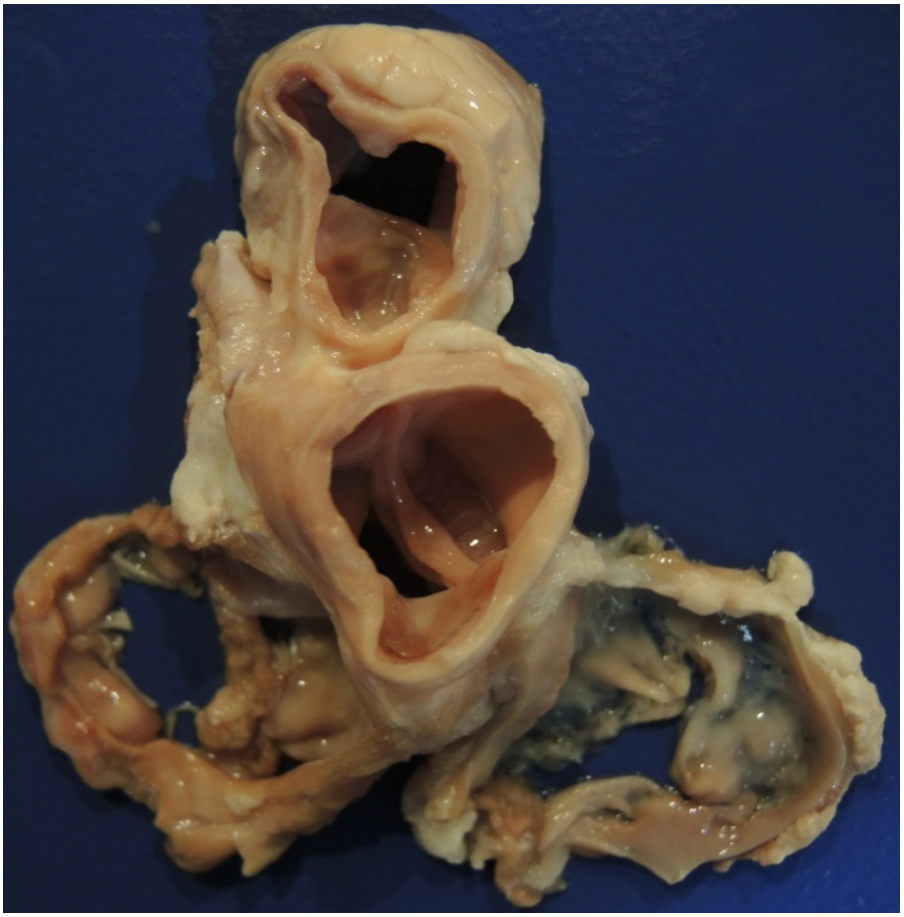

Figure 3: The so-called skeleton of an unfixated heart in cranial view. The aortic valve is the centrepiece with top right clearly visible one of the sinuses of Valsalva. At the lower left side is the mitral annular ring and at the right lower side is the tricuspid annular ring. The leaflets and some tendinous chords are visible. At the top is the pulmonary valve, which is located most anterior.

and is for two-third connected to the muscular ventricular septum and for one-third connected to the AMC; this includes the non-coronary and a part of the left coronary leaflets[10]. With increasing age, the angle between the root and the body of the LV decreases from 135–180° to 90–120°[9,10]. A horizontal aortic root may result in difficulties with transcatheter valve implantation and retrieval of delivery systems in some settings[20].

There are three levels of the root with different diameters (Figure 5): the widest is at the level of the sinuses. The level of the STJ is most narrow, about 75% of the diameter of the sinuses[6], giving the root the shape of a truncated cone. The rates of the diameters have been determined and are also related to the size of the leaflets. Echocardiographic measurement can underestimate the diameters of the root by transecting the wrong plane[10]. These three levels are crossed by the crown-like attachment and can be measured preoperatively. However, it is better to mention the size of the three levels[13]. The shape of the aortic root is considered as ideal for the optimal function of the aortic valve[10,14]. This shape maintains a laminar flow and an optimal coronary perfusion during diastole[5,9]. Changes of the shape throughout the cardiac cycle can be detected using CT angiography with high spatial and temporal resolution[9,21]. An animal experiment has shown a precise chronology: at the end of diastole the aortic root is more as a truncate cone in shape. During systole, the aortic root is more cylindrical because of the changes at commissural level; this facilitates ejection[22], minimises transvalvular turbulence and reduces stress applied on the leaflets[23]. The size of all levels should be measured in preparation of transcatheter valve replacement. Using echocardiography, the planes of transsection should be chosen carefully[10].

No single structure mentioned above should be called the aortic annulus. Some state the aortic annulus does not really exist[6], or do not discern a true fibrous ring[12]. Others call the aortic root 'well defined'[5] or describe it on anatomical or on echocardiographic grounds[9,13,24]. The term annulus means ring, but there are several rings, which are not all anatomically discrete structures[10]. These rings are from proximal to distal in (i) a virtual ring formed by the line connecting most proximal attachment of the leaflets, the inlet from the LVOT into the root[5,7,12,13], (ii) the VAJ, which can be considered as a true anatomical ring, fixed firmly at the LV and at the trigones[5] and (iii) the STJ. The semilunar attachment of the leaflets has the shape of a crown and is located between the first virtual ring and the third ring and crosses the anatomical VAJ[5]. Some authors call this VAJ the annulus[1,16] which can be measured with a Hegar dilator. Others call the crown-shaped attachment the annulus[9] since it can be reconstructed by placing sutures with pledgets along the curves[14]. It seems reasonable to avoid this discussion by labelling the STJ plus the basal ring as the root. It serves as natural stent and needs correction in case of dilation with valve regurgitation[14,25].

For citation purposes: *Mistiaen WP.* The aortic valve and its root: the modern Babylonian tower still stands. OA Anatomy 2013 Dec 01;1(3):29.

Competing interests: none declared. Conflict of interests: none declared.
All authors contributed to conception and design, manuscript preparation, read and approved the final manuscript.
All authors abide by the Association for Medical Ethics (AME) ethical rules of disclosure.

OA Anatomy
Open Access

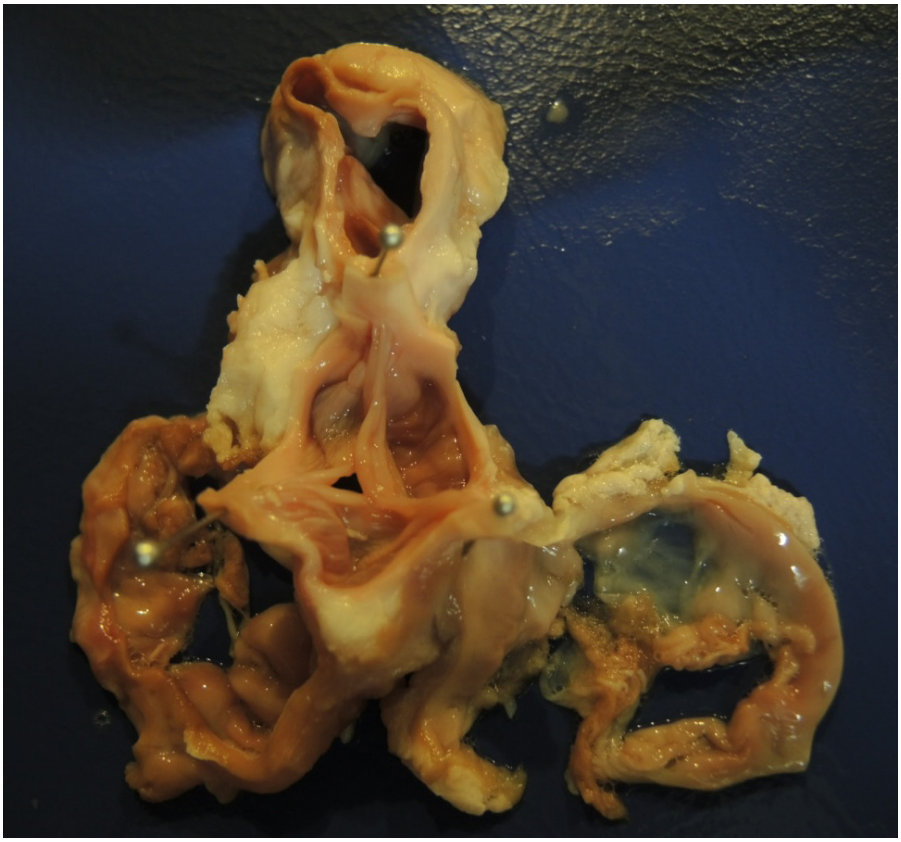

Figure 4: The so-called skeleton of the heart. Centrally located is the aortic valve with the sinuses removed. The leaflets are almost in a closed position. The full length of the attachment of the leaflets is clearly visible. Their most distal end is fixed by needles. The other valves are oriented as in Figure 3.

The crossing of the semilunar attachments of the VAJ results in two different junctions: the anatomical and the haemodynamic junction. This is the key in understanding the clinical anatomy (Figure 5)[6,13]. The anatomical junction is located at the border between the ventricular muscle and the sinuses[1,10,13] and is circular shaped on echocardiography[6,9,11]. Hence, it does not follow the attachment of the leaflets, which cross this anatomic junction[6,13]. It is the place for suturing the aortic valve prosthesis[10,13]. This could define the terms 'intra-annular' and 'supra-annular' valve replacement. The major part of this anatomic junction takes part in the formation of the central fibrous body and the AMC[6]. The haemodynamic junction is formed by the semilunar attachment[1,5,13] or 'hinge-lines'[6]. It extends through the root, from the LV to the STJ. At the proximal side, it is subjected to cyclic pressure changes in the LV and at the distal side it is subjected to arterial pressures[5,13]. The supravalvular component is primarily aortic, but reaches the LV. The subvalvular part is primarily ventricular and supportive but extends to the STJ as the triangles. This implies that the ventricular parts within the aortic sinuses are incorporated functionally within the aorta while the interleaflet triangles are haemodynamically part of the LV[6,10]. The importance of coronet-shaped attachment is illustrated by surgical suspension of the effective height of the cusps[14,16].

Mathematical models allow the construction of the complex 3D geometry of the root with a small margin of error. It could serve as an alternative for difficult 3D imaging[26] in preparation for surgical repair[7]. Individual variability as well as changes during the cardiac cycle have to be taken into account[22,23]. However, application of geometric formula seems less important than surgical skills in restoring the valve-sparing aortic root. Moreover, preoperative measuring of the various components with subsequent tailoring of the graft seems more accurate[14]. ECG-triggered MRI and CT imaging also might offer 3D constructions which take the motion during the cardiac cycle into account. There must be sufficiently high temporal and spatial resolution[26]. This has profound implications for reparative surgery of the aortic valve, since the dynamic behaviour of the root after reparation affects the movements of the leaflets[2].

Conclusion

The differences in terminology and hence the potential for confusion are probably to stay. For this reason, each author should define every structure mentioned in scientific manuscripts. Some etymological differences such as 'cusp – leaflet' do cause serious difficulties. Defining the aortic annulus is much more problematic and has much more implications.

Abbreviations list

AMC, aorto-mitral continuity; LV, left ventricle; LVOT, LV outflow tract; STJ, sinotubular junction; VAJ, ventriculo-aortic junction

References

1. Prodromo J, D'Ancona G, Amaducci A, Pilato M. Aortic valve repair for aortic insufficiency: A review. J Cardiothorac Vasc Anesth. 2012 Oct;26(5):923–32.
2. Yacoub MH, Kilner PJ, Birks EJ, Misfeld M. The aortic outflow and root: a

For citation purposes: *Mistiaen WP.* The aortic valve and its root: the modern Babylonian tower still stands. OA Anatomy 2013 Dec 01;1(3):29.

Competing interests: none declared. Conflict of interests: none declared.
All authors contributed to conception and design, manuscript preparation, read and approved the final manuscript.
All authors abide by the Association for Medical Ethics (AME) ethical rules of disclosure.

OA Anatomy
Open Access

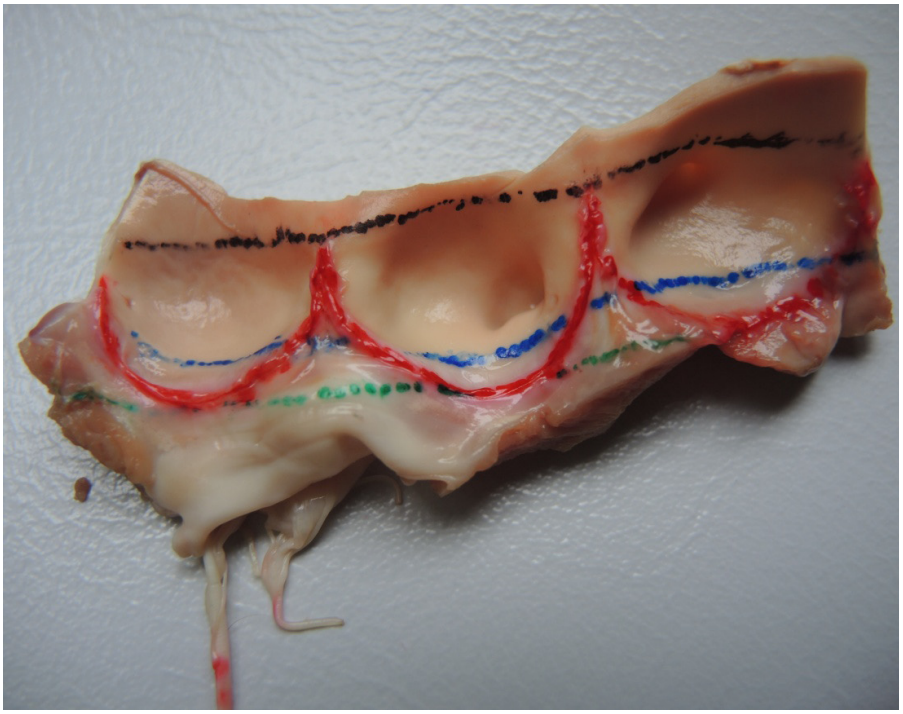

Figure 5: The three sinuses of Valsalva while the aortic root is open. The top line (black) shows the STJ. The red line represents the attachment of the leaflets, which is also the hemodynamic VAJ. When the aorta is closed, they form the so-called crown-shaped junction. The blue line indicates where the muscle of the LV gives way to the fibrous tissue of the aortic root. This is the anatomic VAJ. The virtual green line connects the most basal parts of the attachment of the leaflets, and hence of the sinuses. Understanding the significance of these different 'rings' is essential for understanding the function of the aortic valve. The triangles are indicated by the red lines (the parabolic sides) and the blue line (bottom side). The aorto-mitral continuity can be observed at the left side.

tale of dynamism and crosstalk. Ann Thorac Surg. 1999 Sep;68(3 Suppl): S37–43.
3. Sievers HH, Hemmer W, Beyersdorf F, Moritz A, Moosdorf R, Lichtenberg A, et al. The everyday used nomenclature of the aortic root components: the tower of Babel? Eur J Cardiothorac Surg. 2012 Mar;41(3):478–82.
4. Brown ML, Lenoch JR, Schaff HV. Variability in data: the Society of Thoracic Surgeons National Adult Cardiac Surgery Database. J Thorac Cardiovasc Surg. 2010 Aug;140(2):267–73.
5. Misfeld M, Sievers HH. Heart valve macro- and microstructure. Philos Trans R Soc. 2007 Aug;362(1484):1421–36.
6. Ho SY. Structure and anatomy of the aortic root. Eur J Echocardiogr. 2009 Jan;10(1):i3–10.
7. Mangini A, Lemma MG, Soncini M, Votta E, Contino M, Vismara R, et al. The aortic interleaflet triangles annuloplasty: a multidisciplinary appraisal. Eur J Cardiothorac Surg. 2011 Oct;40(4):851–7.
8. Schäefers HJ, Schmied W, Marom G, Aicher D. Cusp height in aortic valves. J Thorac Cardiovasc Surg. 2013 Aug;146(2):269-74.
9. Bateman MG, Hill AJ, Quill JL, Iazzo PA. The clinical anatomy and pathology of the human arterial valves: implications for repair or replacement. J Cardiovasc Trans Res. 2013 Apr;6(2):166–75.
10. Piazza N, de Jaegere P, Schultz C, Becker AE, Serruys PW, Anderson RH. Anatomy of the aortic valvar complex and its implications for transcatheter implantation of the aortic valve. Circ Cardiovasc Interv. 2008 Aug;1(1):74–81.
11. Gami AS, Noheria A, Lachman N, Edwards WD, Friedman PA, Talreja D, et al. Anatomical correlates relevant to ablation above the semilunar valves for the cardiac electrophysiologist: a study of 603 hearts. J Interv Card Electrophysiol. 2011 Jan;30(1):5–15.
12. Carr JA, Savage EB. Aortic valve repair for aortic insufficiency in adults: a contemporary review and comparison with replacement techniques. Eur J Cardiothorac Surg. 2004 Jan;25(1): 6–15.
13. Anderson RH. The surgical anatomy of the aortic root. Multimedi Man Cardiothoracic Surg. 2007 Jan;2007(102):mmcts.2006.002527.
14. Kollar AC, Lick SD, Conti VR. Valve-sparing aortic root reconstruction using in situ three-dimensional measurements. Ann Thorac Surg. 2009 Jun;87(6): 1795–800.
15. Dweck MR, Boon NA, Newby DE. Calcific aortic stenosis. A disease of the valve and the myocardium. J Am Coll Cardiol. 2012 Nov;60(19):1854–63.
16. Lansac E, Di Centa I, Sleilaty G, Crozat EA, Bouchot O, Hacini R, et al. An aortic ring: from physiologic reconstruction of the root to a standardised approach for aortic valve repair. J Thorac Cardiovasc Surg. 2010 Dec;140(6 Suppl): S28–35.
17. Loukas M, Wartmann CT, Tubbs RS, Apaydin N, Louis Jr. RG, Easter L, et al. The clinical anatomy of the sinutubular junction. Anat Sci Int. 2009 Apr;84(1–2): 27–33.
18. Del Valle-Fernàndez R, Jelnin V, Panagopoulos G, Dudiy Y, Schneider L, de Jaegere P, et al. A method for standardised computed tomography angiography-based measurement of aortic valvar structures. Eur Heart J. 2010 Sep;31(17): 2170–8.
19. Freeman LA, Young PM, Foley TA, Williamson EE, Bruce CJ, Greason KL. CT and MRI assessment of the aortic root and ascending aorta. AJR Am J Roentgenol. 2013 Jun;200(6):W581–92.
20. Chan PH, Alegria-Barrero E, Di Mario C. Difficulties with horizontal aortic root in transcatheter aortic valve implantation. Catheter Cardiovasc Interv. 2013 Mar;81(4):630–5.
21. Gaztanaga J, Pizarro G, Sanz J. Evaluation of cardiac valves using multidetector CT. Cardiol Clin. 2009 Nov;27(4): 633–44.

For citation purposes: *Mistiaen WP.* The aortic valve and its root: the modern Babylonian tower still stands. OA Anatomy 2013 Dec 01;1(3):29.

Competing interests: none declared. Conflict of interests: none declared.
All authors contributed to conception and design, manuscript preparation, read and approved the final manuscript.
All authors abide by the Association for Medical Ethics (AME) ethical rules of disclosure.

22. Lansac E, Lim HS, Shomura Y, Lim KH, Rice NT, Goetz W, et al. A four-dimensional study of the aortic root dynamics. Eur J Cardiothorac Surg. 2002 Oct;22(4):497–503.
23. Cheng A, Dagum P, Miller DC. Aortic root dynamics and surgery: from craft to science. Phil Trans R Soc Lond B Biol Sci. 2007 Aug;362(1484):1407–19.
24. Berdajs D, Lajos P, Turina M. The anatomy of the aortic root. Cardiovasc Surg. 2002 Aug;10(4):320–7.
25. El Khoury G, Glineur D, Rubay J, Verhelst R, d'Acoz Yd, Poncelet A, et al. Functional classification of aortic root/valve abnormalities and their correlation with etiologies and surgical procedures. Curr Opin Cardiol. 2005 Mar;20(2): 115–21.
26. Haj-Ali R, Marom G, Ben Zekry S, Rosenfeld M, Raanani E. A general three-dimensional parametric geometry of the native aortic valve and root for biomechanical modeling J Biomech. 2012 Sep;45(14):2392–7.

For citation purposes: *Mistiaen WP.* The aortic valve and its root: the modern Babylonian tower still stands. OA Anatomy 2013 Dec 01;1(3):29.

Competing interests: none declared. Conflict of interests: none declared.
All authors contributed to conception and design, manuscript preparation, read and approved the final manuscript.
All authors abide by the Association for Medical Ethics (AME) ethical rules of disclosure.