JBR–BTR, 2014, 97: 316.

IMAGES IN CLINICAL RADIOLOGY

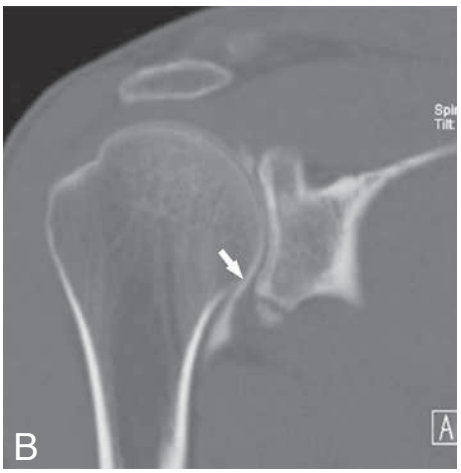

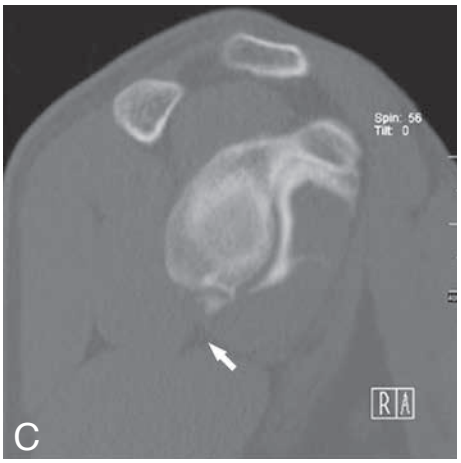

Proximal avulsion fracture of the long head of the triceps brachii muscle.

M. Vansevenant[1,2], F.M. Vanhoenacker[1,2,3], T. Wauters[4]

A 27-year-old male and indoor soccer goalkeeper presented at the private practice of the orthopaedic surgeon with pain in the posterior right shoulder. Two months previously, he felt sudden pain and loss of function in his shoulder when throwing a ball, more specifically during ball release. After 6 weeks of rest, there was almost complete recovery. He started playing indoor soccer again and fell on his right shoulder with relapse of the pain. He never experienced dislocation of the shoulder. Clinically there was full range of motion of his shoulder and no muscle atrophy. Resistance tests of the triceps brachii muscle caused pain in the posterior shoulder.

A plain film of the right shoulder showed a bony fragment at the inferior rim of the glenoid (Fig. A, arrow). A CT-arthrography (Fig. B, C) and MR-arthrography showed a sclerotic delineated avulsion fragment at the infraglenoid tubercle, but showed no concomitant lesion of the antero-inferior labrum (Fig. B, arrow). There was no Hill-Sachs lesion and the rotator cuff was normal. There was no tendon retraction of the long head of the triceps brachii muscle (Fig. C, arrow).

Based on the clinical presentation and imaging findings, the diagnosis of a proximal avulsion fracture of the long head of the triceps brachii muscle was made. The patient was treated conservatively with relative rest and nonsteroidal analgetics. After 3 months of follow-up, the patient was pain-free during his daily activities and could restart his indoor soccer training with throwing-exercises.

Comment

The triceps brachii muscle consists of three muscular heads: a lateral head with its origin on the latero-posterior side of the humeral diaphysis, a medial head originating from the medio-posterior side of the humeral diaphysis and superficial of these two heads the long head with its origin on the infraglenoid tubercle. These three heads join at the distal triceps tendon inserting on the olecranon. The function of the triceps brachii muscle is extension of the elbow and adduction of the arm by the long head.

A traumatic tear or avulsion fracture of the triceps tendon is uncommon, accounting for less than 1% of all tendon injuries. Most triceps tendon injuries are located at the distal insertion of the tendon into the olecranon. Proximal triceps tendon injuries are even rarer.

The probable trauma mechanism in our case consists of a bony avulsion that occurred when throwing a ball, more specifically at the end of the extension of the elbow.

In case of proximal triceps tendon injury, plain films may show an avulsion fragment at the infraglenoid tubercle, which may be confirmed on Computed Tomography (CT) or CT-arthrography. MR-arthrography is less suited for demonstrating osseous avulsions without labrum lesions. The differential diagnosis includes a bony Bankart lesion and a Bennet's lesion. A bony Bankart lesion occurs during an antero-inferior shoulder dislocation and is associated with a lesion of the antero-inferior labrum. A Bennet's lesion is a calcium deposition in the posterior capsule of the shoulder, seen in professional baseball pitchers. The latter does not provoke acute pain. Typical location at the inferior rim of the glenoid and the absence of a cartilaginous labrum lesion are the clues to the correct diagnosis.

Avulsion of the long head of the triceps muscle can be treated conservatively with nonsteroidal analgetics and relative rest. If conservative treatment fails, surgical intervention may be required.

Reference

1. Clifford P.D., Posada A., Hancock C.R.: Isolated long-head triceps brachii tendon avulsion in a surfer detected at MR imaging. *Skeletal Radiol,* 2009, 38: 77-80.

1. Department of Radiology, AZ Sint Maarten, Mechelen-Duffel, 2. Department of Radiology, Ghent University Hospital (UZ Gent), 3. Department of Radiology, Antwerp University Hospital (UZA), 4. Orthopedic Surgery, Mechelen.