

Triplane ankle fracture in a young adolescent

Published on 28.03.2024

DOI: 10.35100/eurorad/case.18510

ISSN: 1563-4086

Section: Musculoskeletal system

Area of Interest: Anatomy Bones Musculoskeletal bone

Musculoskeletal joint Musculoskeletal soft tissue

Paediatric

Imaging Technique: Conventional radiography

Imaging Technique: CT

Special Focus: Trauma Case Type: Clinical Case

Authors: Rutger Desmadryl 1,2, Arnaud R. Goossens

1,3, Filip M. Vanhoenacker 1,4,5, Peter Boone 1

Patient: 14 years, female

Clinical History:

A 14-year-old girl presents at the emergency department with a swollen left ankle and weight-bearing inability after falling 2 meters from a playground tower. The fall caused an inversion/supination trauma of the ankle, resulting in significant tenderness of the distal tibia during examination.

Imaging Findings:

Conventional radiographs of the left ankle revealed an oblique tibial fracture running from lateral to medial on the anteroposterior (AP) and mortise views, distal to the physis, without significant displacement nor intra-articular gap (Figure 1a). The lateral view, however, showed a subtle vertical fracture line, through the posterior malleolus with intra-articular hydrops and soft tissue swelling (Figure 1b).

To evaluate the extent of involvement of the physis, subsequent computer tomography (CT) was performed and revealed three distinct fracture lines. The first fracture runs para-sagittally in the epiphysis of the lateral distal tibia, extending to the anterior physis with an intra-articular gap (Figure 2a). The coronal plane showed a second fracture line, running from the anterior central physis to the joint's medial aspect (Figure 2b). Lastly, a vertical fracture line separated the posterior malleolus from the ankle joint on the posterior aspect of the distal tibia (Figure 2c).

Discussion:

A triplane ankle fracture, also known as a Marmor–Lynn fracture, is a type of fracture of the distal tibia that predominantly affects children between the ages of 12 and 15. It is most commonly caused by sports or playground injuries [1]. This epiphyseal fracture has fracture lines in three planes: sagittal, coronal and axial. This triplanar nature is a result of the sequence of distal tibial physis closure during early adolescence, commencing anteromedially at Kump's bump, and extending medially before finishing laterally towards the syndesmosis (Figure 3). During this time, unfused segments of the growth plate are prone to fracture, while the fused parts become relatively stable in trauma. Due to the importance of ongoing physeal closure, this fracture type is also referred to as a "transitional fracture" [1–3].

The intricate triplanar pattern does not allow complete visualisation using conventional AP and lateral radiographs. These fractures mimic Salter–Harris type III fractures on an AP view and Salter–Harris type II fractures on lateral view, making it challenging to estimate displacement accurately. Further evaluation, diagnosis, and pre-operative planning require CT [1,2,4,5].

When intra-articular displacement is limited to 2mm, conservative treatment using cast immobilisation is an option. Any greater displacement, however, requires open reduction and internal fixation, either using lag screws (which can sometimes be placed percutaneously) or plate osteosynthesis[1,2]. Thus, CT imaging is indispensable for pre-operative planning. According to a study conducted by Eismann et al., in up to 41% of cases, surgeons changed their proposed strategy for internal fixation after analysis of the CT images[5].

Triplane ankle fractures continue to pose a challenge for emergency physicians, radiologists, and orthopaedic surgeons. Fractures involving the distal tibia growth plate in adolescents demand careful consideration, and when uncertainty arises, additional evaluation through CT imaging is essential to avoid overlooking indications for surgery. Existing literature emphasises the importance of using multiplanar imaging techniques in nearly all cases of triplane fractures, as they enhance diagnostic accuracy and pre-operative decision-making[2,4,5].

Written informed patient consent for publication has been obtained.

Differential Diagnosis List: Salter–Harris type II distal tibia fracture, Salter–Harris type III distal tibia fracture, Tillaux fracture, Lateral triplane fracture of the distal tibia, Medial triplane fracture

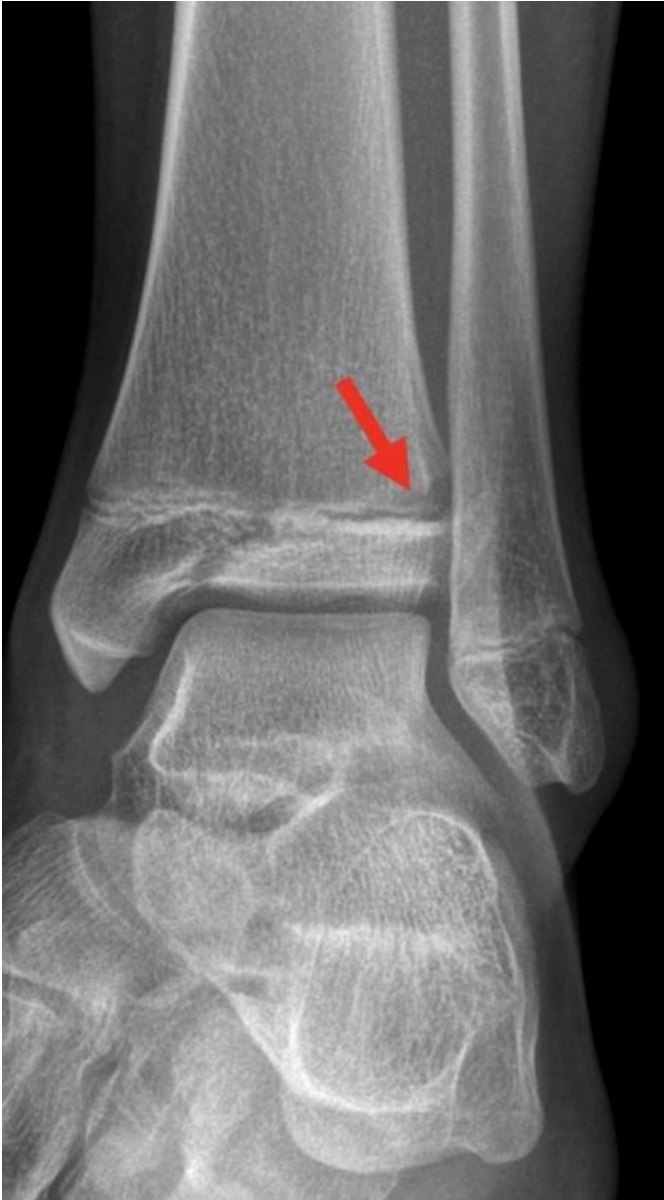Final Diagnosis: Lateral triplane fracture of the distal tibia

References:

- Schnetzler KA, Hoernschemeyer D (2007) The pediatric triplane ankle fracture. *J Am Acad Orthop Surg* 15(12):738-47. doi: 10.5435/00124635-200712000-00007. (PMID: [18063714](#))
- Wuerz TH, Gurd DP (2013) Pediatric physeal ankle fracture. *J Am Acad Orthop Surg* 21(4):234-44. doi: 10.5435/JAAOS-21-04-234. (PMID: [23545729](#))
- De Brucker Y, Jager T, Devos H, Boulet CG, Kichouh M, De Maeseneer M, Shahabpour M, de Mey J (2014) Trauma mechanism in ankle fracture: Let's do the twist!. [Poster]. ECR 2014 EPOS Poster C-2340. doi: 10.1594/ecr2014/C-2340
- Schneidmueller D, Sander AL, Wertebroek M, Wutzler S, Kraus R, Marzi I, Laurer H (2014) Triplane fractures: do we need cross-sectional imaging? *Eur J Trauma Emerg Surg* 40(1):37-43. doi: 10.1007/s00068-013-0338-7. (PMID: [26815775](#))
- Eismann EA, Stephan ZA, Mehlman CT, Denning J, Mehlman T, Parikh SN, Tamai J, Zbojniec A (2015) Pediatric Triplane Ankle Fractures: Impact of Radiographs and Computed Tomography on Fracture Classification and Treatment Planning. *J Bone Joint Surg Am* 97(12):995-1002. doi: 10.2106/JBJS.N.01208. (PMID: [26085533](#))

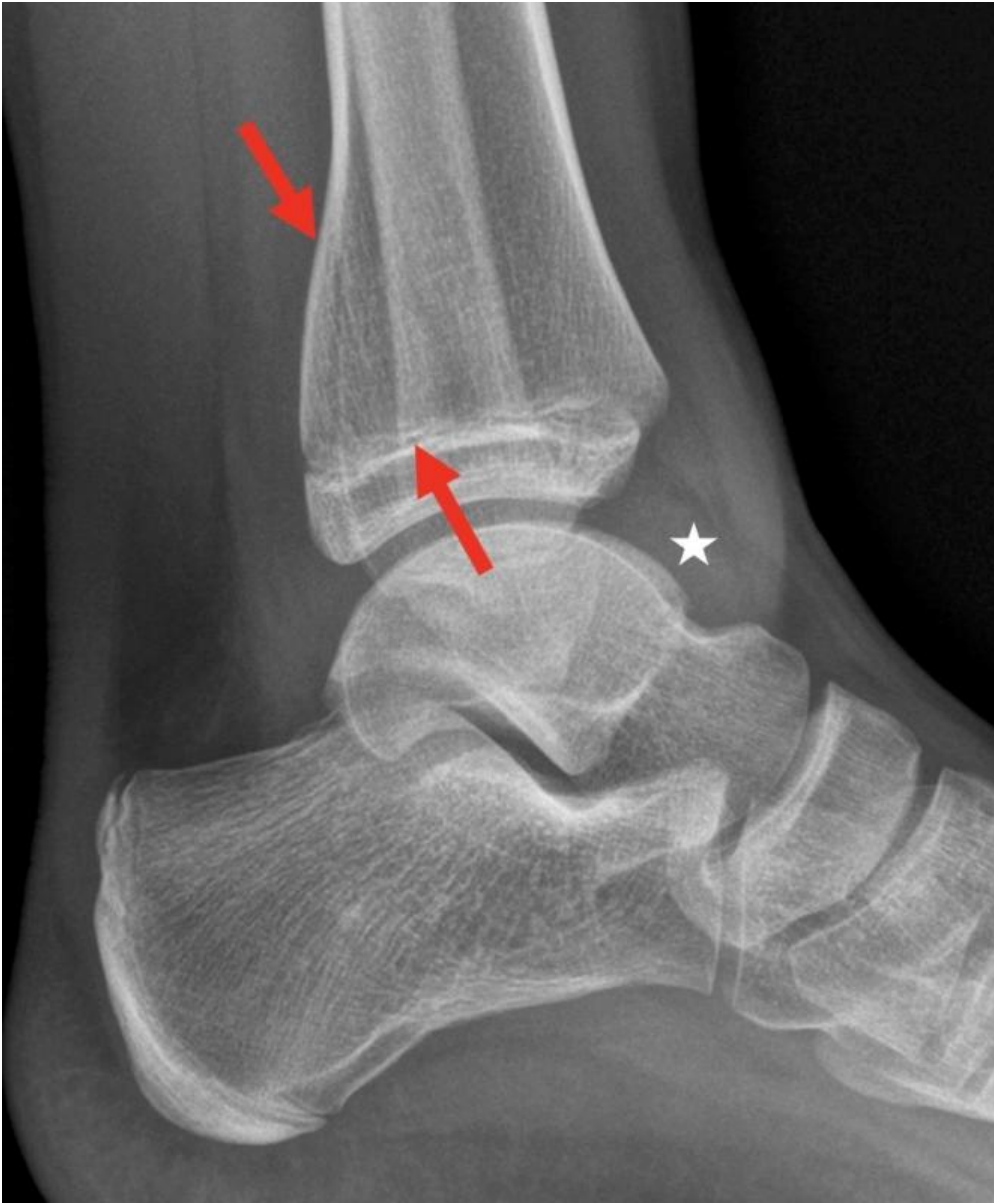Figure 1

a



Description: Conventional X-ray of the ankle, mortise view. Oblique fracture in the distal tibial epiphysis and passing through the growth plate. Notice the slight physeal broadening (arrows) and the subtle osseous rarefaction on the lateral aspect of the tibial metaphysis, suspicious of transphyseal extension of the fracture in keeping with a Salter–Harris fracture type III. **Origin:** © Department of Radiology, AZ Sint-Maarten, Mechelen, Flanders, Belgium, 2023

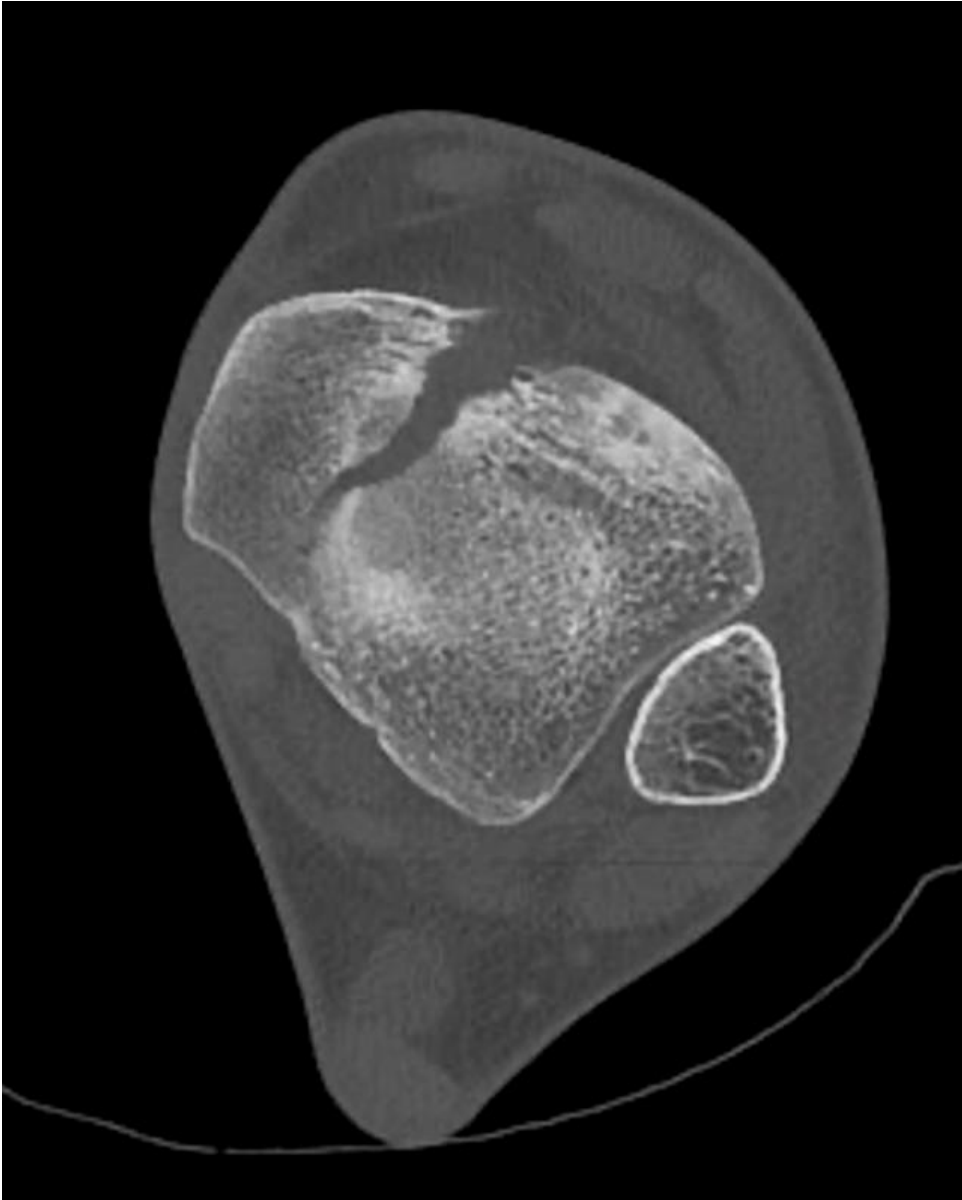
b



Description: Conventional X-ray of the ankle, lateral view. Vertical fracture through the malleolus tertius (arrows) with joint effusion in the anterior recess of the tibiotalar joint (asterisk). **Origin:** © Department of Radiology, AZ Sint-Maarten, Mechelen, Flanders, Belgium, 2023

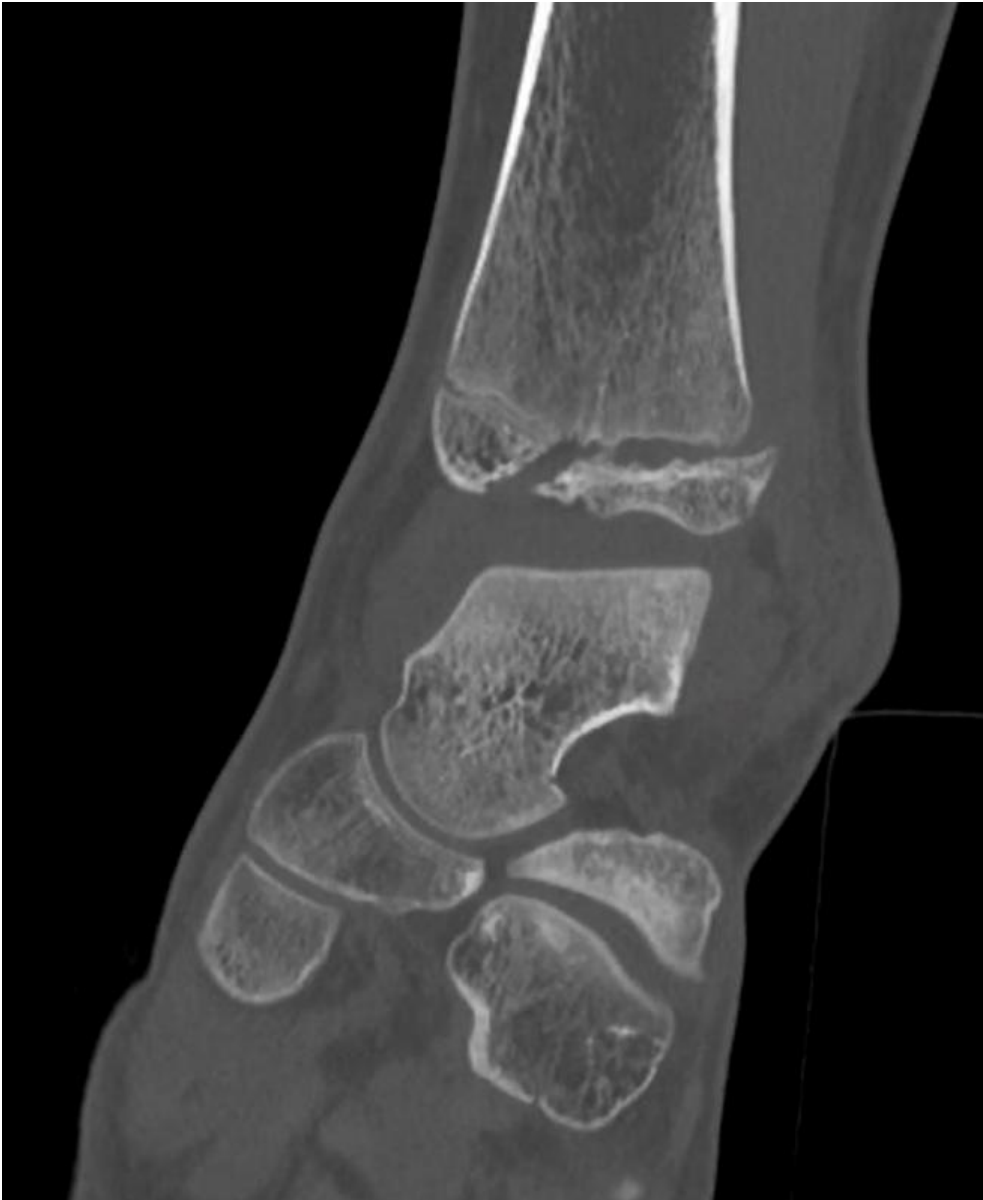Figure 2

a



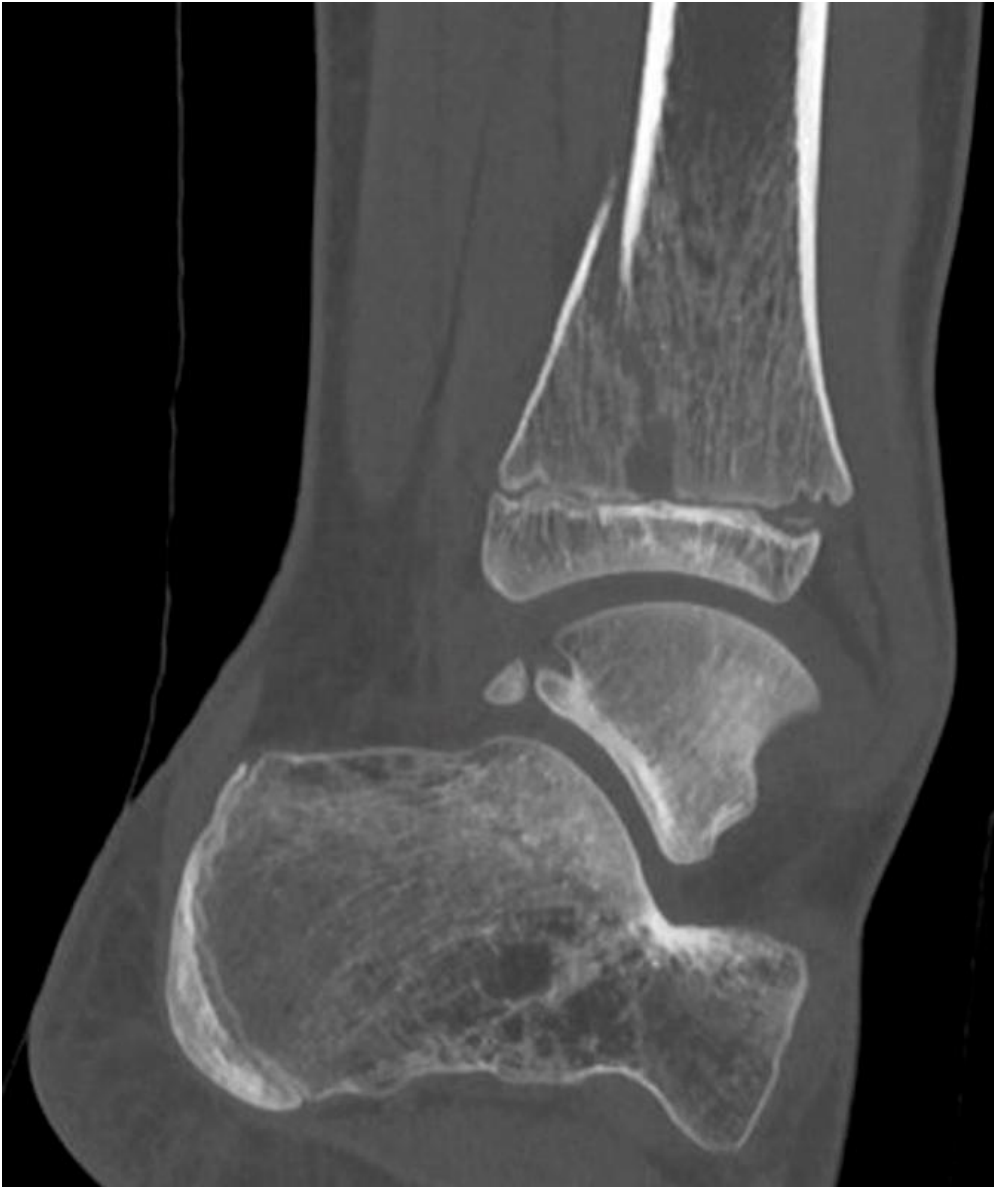Description: Transverse CT scan of the ankle on the level of the distal tibial epiphysis. The first fracture line runs obliquely in the parasagittal plane from medial-posterior to lateral-anterior into the physis, with a significant intra-articular gap (> 2mm). **Origin:** © Department of Radiology, AZ Sint-Maarten, Mechelen, Flanders, Belgium, 2023

b



Description: Coronal CT of the ankle. The second fracture line runs in the axial plane from the medial aspect up to the anterolateral margin of the physis. Notice a slightly widened growth plate with lateral translation due to epiphysiolysis. **Origin:** © Department of Radiology, AZ Sint-Maarten, Mechelen, Flanders, Belgium, 2023

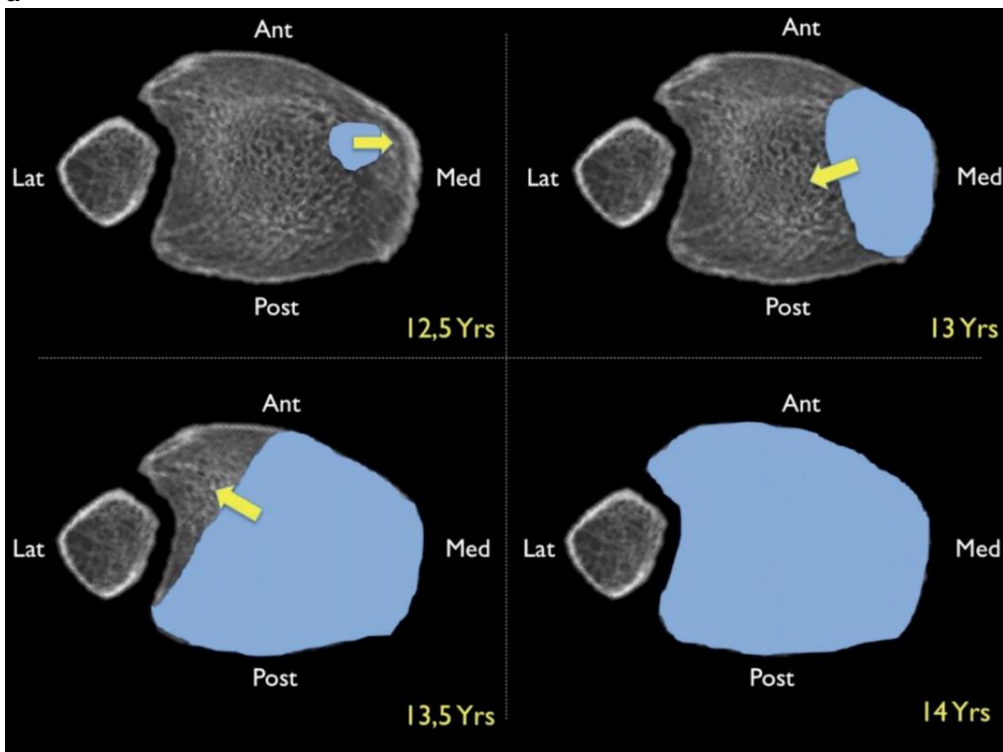
c



Description: Sagittal CT of the ankle. The third fracture line runs in the coronal plane through the posterior third of the metaphysis of the tibia above the level of the physis. **Origin:** © Department of Radiology, AZ Sint-Maarten, Mechelen, Flanders, Belgium, 2023

Figure 3

a



Description: Fusion of the distal tibial growth plate starts anteromedially at an average age of 12.5 years old. Over a period of 18 months, the fusion progresses further medially, then posteriorly and laterally, and finally anterolaterally. This explains that the anterolateral part remains the most vulnerable to fractures until complete growth plate fusion. **Origin:** © De Brucker Y, Jager T, Devos H, et al (2014) Trauma mechanism in ankle fracture: Let's do the twist!. [Poster]. ECR 2014 EPOS Poster C-2340. doi: 10.1594/ecr2014/C-2340. Reprinted with permission from Dr. Y. De Brucker.