Update on the role of bone biopsy in the management of patients with CKD-MBD

Reference:
Evenepoel P., Behets Geert, Laurent M. R., d' Haese Patrick C..- Update on the role of bone biopsy in the management of patients with CKD-MBD
Journal of nephrology - ISSN 1121-8428 - Heidelberg, Springer heidelberg, 30:5(2017), p. 645-652
Full text (Publisher's DOI): https://doi.org/10.1007/S40620-017-0424-8
To cite this reference: http://hdl.handle.net/10067/1467120151162165141

Update on the role of bone biopsy in the management of patients with CKD-MBD

Evenepoel P.[1], Behets G.J.S.[2], Laurent MR[3] and D'Haese P.C.[2]

1. KU Leuven – University of Leuven, Department of Immunology and Microbiology, Laboratory of Nephrology and University Hospitals Leuven, Department of Nephrology and Renal Transplantation, B-3000 Leuven, Belgium, pieter.evenepoel@uzleuven.be
2. Antwerp University, Department of Biomedical Sciences, Laboratory of Pathophysiology, B-2610 Wilrijk, Belgium, patrick.dhaese@uantwerpen.be
3. University Hospitals Leuven, Centre for Metabolic Bone Diseases and KU Leuven, Department of Clinical and Experimental Medicine, Gerontology and Geriatrics section, B-3000 Leuven, Belgium, michael.laurent@uzleuven.be

***Word count manuscript*:** 3500 (max 3000)

Word count abstract: (max 250)

***Number of figures and tables*:** 6

Address for correspondence: P. Evenepoel, MD, PhD

Nephrology

University Hospitals Leuven

Herestraat 49

B-3000 Leuven

BELGIUM

Tel. +32-16-344591

Fax. +32-16-344599

e-mail: Pieter.Evenepoel@uzleuven.be

COI statement
[1-2]The authors declare no funding or conflicts of interest.
The results presented in this paper have not been published previously in whole or part, except in abstract format.

Abstract

Patients with chronic kidney disease (CKD) are at increased risk of fractures. The fracture risk steadily increases along with the progression of renal disease to become several-fold higher end stage renal disease patients as compared to age and sex-matched controls. Renal osteodystrophy (ROD) is a heterogeneous group of metabolic bone diseases complicating progressive chronic kidney disease. Bone biomarkers and bone imaging techniques may help to assess bone health and predict fractures in CKD, but do have important inherent limitations. The gold standard for the diagnosis and specific classification of renal osteodystrophy (ROD) remains the (quantitative) histomorphometrical analysis of the bone biopsy. By informing on bone turnover and mineralization, a bone biopsy may help to guide prevention and treatment of ROD and its consequences. This review aims to present an update on epidemiological and procedural aspects, clinical indications, and histomorphometric analysis of bone biopsies and to define the role of bone biopsy in contemporaneous CKD-MBD care.

Introduction

Chronic kidney disease (CKD) is a significant public health problem, affecting ±11% of the world population(1). Renal bone disease occurs early in the course of CKD and becomes very common in patients at advanced stages. It is increasingly recognized that renal bone disease involves multiple organ systems and is associated with cardiovascular events, death and fractures. In 2006, the term CKD–mineral and bone disorder (CKD-MBD) was coined as a systemic disturbance of mineral and bone metabolism caused by CKD, and manifested by either one or the combination of the following: (a) laboratory abnormalities of bone and mineral metabolism, (b) abnormalities in bone turnover, mineralization, volume, linear growth, or strength and/or (c) bone disease and vascular and other soft-tissue calcifications(2). This more general definition of renal bone disease recognizes that its pathophysiology extends beyond the skeleton and that there are links between abnormal bone remodeling activity and the risk for soft tissue and vascular calcification. In this new construct, the term “renal osteodystrophy” (ROD) is limited to the specific changes in bone histology that accompany moderate and end-stage CKD and is defined according to histomorphometric criteria.

Patients with CKD are at increased risk of fractures. The fracture risk steadily increases along with the progression of renal disease to become 4 times as high in end stage renal disease patients as compared to healthy controls(3). The risk further increases following renal transplantation, at least transiently (4). Compared to CKD patients without fractures, those with fractures experience a multifold increased risk of mortality(5). Both a high fall risk and an impaired bone strength account for the increased fracture risk in CKD (6). Bone strength is determined by bone quantity and bone quality. Several lines of evidence indicate that CKD is a state of low bone mass and accelerated bone loss(7). Since adjustment for bone mineral density (BMD) (as a proxy of bone mass) does not nullify the association between CKD and increased fracture risk, CKD may be equally considered a state of impaired bone quality. Both low and high turnover bone disease may compromise bone quality, albeit through different mechanisms(8).

Defining the optimal therapeutic strategy in patients with osteoporosis in the presence of CKD-MBD is challenging (9;10). This complexity often paralyzes nephrologists, in part due to the lack of evidence from large randomized trials in this population. Renal nihilism ('renalism') may thus not only be problematic with regard to the prevention and treatment of cardiovascular disease in CKD patients, but even more so with regard to fractures. Yet in recent years, there is growing awareness of the high fracture burden in CKD and an expanding armamentarium to tackle bone disease (bone antiresorptives, bone anabolics, calcimimetics, vitamin D analogs, …).

Monitoring parathyroid hormone (PTH) levels is routine clinical practice in nephrology care. Much has been inferred from raised PTH values, both in terms of skeletal integrity and fractures and in terms of clinical outcomes for patients. However, recent data from epidemiological and intervention studies have questioned the validity of PTH as a consistent outcome biomarker and therapeutic target in CKD. Altered PTH metabolism and PTH hyporesponsiveness along with a high biological variability may explain why a circulating PTH level, unless at the extremes, performs poor as a biomarker(11). Other biomarkers, though promising, so far have failed to prove superior to PTH(12). Thus at present, the gold standard for the diagnosis and specific classification of renal osteodystrophy (ROD) remains the (quantitative) histomorphometrical analysis of the bone biopsy.

This review aims to present an update on epidemiological and procedural aspects, clinical indications, and histomorphometric analysis of bone biopsies and to define the role of bone biopsy in contemporaneous CKD-MBD care. As such, this review elaborates on previous excellent reviews on this topic (13-15).

Bone biopsy practice across Europe

Despite being considered the gold standard to evaluate ROD, a bone biopsy is only performed in a limited number of patients in a limited number of centers across Europe. According to a recent European survey among nephrologists with expertise in CKD-MBD, only half of them reported to have performed bone biopsies in the past 5 years; moreover, the total number of bone biopsy procedures per respondent over the last 5 years was low, being less than 10 (16). The following constraints of bone biopsies were identified: laborious and/or painful sampling procedure, time consuming and costly histopathological analysis, and missing histopathological expertise. Reimbursement, moreover, is also lacking in several countries. Importantly, most respondents disagreed with the statement that a bone biopsy is mainly a research tool with little clinical added value. Clearly, nephrologists are aware of the threat of an ongoing negative spiral which could ultimately result in the complete disappearance of bone biopsy expertise(16) .

Bone biopsy technique

The iliac crest is the preferred site when doing a bone biopsy, because it is easily accessible, has been proven safe and associated with minimal morbidity. Bone biopsies at the iliac crest can be obtained in either a vertical or a horizontal direction. The vertical approach allows the

assessment of subcortical cancellous and deep cancellous bone without size restrictions. The use of a horizontal direction provides information on the outer and inner cortices, yet the sample size is limited, though sufficient in the great majority of cases, by the thickness of the iliac bone. The horizontal transiliac technique is currently the most widely applied approach with a 5 cm isolateral triangular area (Bordier's triangle) located behind the anterior superior iliac spine and below the iliac crest border being the most suitable biopsy site(14). This site shows the closest relation to the lumbar bone mass (17). Still, variation in trabecular microarchitecture of the iliac crest, showing highest bone mass within the anterior part and lower values for the medial and dorsal parts (17), may partly account for the large differences in bone volume between repeat biopsies and the low correlation with BMD as assessed by DXA.

Operator skills and the use of appropriate instruments determine the quality of bone sampling. At least in Europe, most bone biopsies are performed with a manual trochar. Less than 10% of the bone biopsies procedures are performed using an electric drill (Evenepoel et al. NDT 2017).

A sufficient bone sample size should be obtained with minimal surgical invasiveness. An important question is: what is the minimal sample size to allow accurate qualitative and quantitative bone histomorphometry? While previously, only bone samples of ± 8 mm in diameter and 1.5 to 2.0 cm in length were considered appropriate, current knowledge indicates that bone samples with a diameter between 4.0 to 4.5 mm may be sufficient. This explains why small (inner diameter < 5mm) trephines are gaining popularity (almost 40% penetrance) at the expense of the large, non-disposable trephine needles (Bordier, Bedford, …). The small trephine needles are disposable, obviating the need for sterilization and sharpening of the teeth of the trephine in between bone biopsy procedures. A major asset of using smaller needles is decreased procedural pain. It may furthermore be anticipated that the complication rate, already low with the Bordier and Bedford type needles (< 1%) (14)(15), is further reduced with the smaller trephines. The use of small needles also obviates the need to interrupt antiplatelet agents or to modify the anticoagulation regimen of the dialysis session preceding and following the bone biopsy, unless being scheduled on the same day. Altogether, using the small needles, the bone biopsy procedure for evaluating ROD is almost indistinguishable from the procedure performed in the work-up of a hematology disorder. It may reasonably be assumed however, that using needles with small inner diameter might increase the risk of damaging the bone and introducing artifacts. As with all technical procedures, there is a learning curve. In our hands (> 500 bone biopsy procedures since 2010) failure rates dropped from almost 20% in the early days to less than 5% in most recent series (Evenepoel, unpublished results). Artifacts are seldom seen when overzealous use of physical force is avoided. The transiliac biopsy can be repeated, preferably on the opposite side. A time interval of 1 year is advocated between 2 bone biopsy procedures at the same iliac side to avoid bias from the preceding procedure.

Most bone biopsies are performed in outpatient minor surgery facilities with local anaesthesia. If oxygen saturation and blood pressure can be monitored, light sedation with midazolam can be considered to further enhance the procedural comfort of the patient.

To obtain information about dynamic parameters such as bone formation rate and mineralization state, double labeling of the bone surface with flurochrome compounds such as demeclocycline or tetracycline needs to be performed prior to the bone biopsy procedure. These compounds are incorporated into newly mineralized bone. The usual schedule consists of 2 dosing periods, 3 days on (e.g. 500 mg Tetracycline BID), 10 days off, and 3 days on (e.g. 500 mg Tetracycline BID), after which the biopsy is performed within the next 4 to 14 days. In case of emergency, the labeling of bone can be shortened to a 1-day-on (e.g. 1000 mg Tetracycline) , 4-6-days-off, and 1-day-on schedule (e.g. 1000 mg Tetracycline). Although patients generally tolerate double tetracycline labeling, some side effects, such as gastrointestinal discomfort, allergic reaction or photosensivity might be observed. Non-adherence and decreased bioavailability (related to ingestion with meals, antacids, phosphate binders) may explain lack of fluorescent labels or evidence of only one label on bone slides. Patients ingesting phosphate binding agents should be advised to discontinue their phosphate binders during the days tetracyclines are taken. In some countries, demeclocycline or tetracycline are (increasingly) hard to obtain. Stocks are shrinking as these 'old' antibiotics are taken out of production as a consequence of a declining clinical demand.

Sample handling, processing and analysis

After the biopsy procedure, the sample should immediately be transferred to 70 % ethanol for fixation and stored at 4°C (not frozen). Samples may be shipped to the lab at environmental temperature pending histomorphometric analysis. Samples are then embedded in methylmethacrylate. Primary measurement of 'static' and 'dynamic' bone parameters is then performed on respectively 5 µm thick Goldner-stained (Figure 1 & 3) and 10 µm unstained (Figure 2) histological sections. Alternatively, a toluidine blue staining may be used for measurement of static parameters.

On each tissue section, the analysis will be performed in adjacent microscopic fields (magnification of 200x) (Figure 1) covering the entire width of the section. A separation of 1 field between the measurement area and either cortical bone or growth plate will be kept, in order to avoid co-analysis of the endosteal surface and the primary spongiosa. Sample preparation for quantitative histomorphometric analysis of bone is rather laborious and time consuming and necessitates specific histopathological expertise which is not widely available. A (minimal) time interval of around 4 weeks between arrival of the biopsy and the lab report needs to be taken into account.

Complementary information upon bone histomorphometric data can be gained with other techniques such as Quantitative Backscattered Electron Imaging (qBEI), Nanoindention, Fourier Transform Infrared (FTIR) Spectroscopy, Micro Computed Tomography (µ-CT) and Finite Element Modelling (FEM).

qBEI is a high resolution technique that allows visualization and quantification of the degree of the bone matrix mineralization and provides a reliable and reproducible way of assessing bone material properties (18).

In recent years, nanoindentation has emerged as a powerful technique for investigating the micromechanical properties of bone. With the nanoindentation technique, a tip penetrates

the material while the reaction forces and the depth of penetration are recorded. From this data, parameters related to the stiffness and strength of the indented region can be determined (19).

FTIR spectroscopy quantifies bone material properties at multiple hierarchical levels such as mineral to matrix ratio, mineral maturity/crystallinity, and collagen maturity (expressed as the ratio of two of the major Type I bone collagen crosslinks) (20) .

µ-CT is a high-resolution imaging modality that is capable of analyzing bone structure with a voxel size on the order of 10 µm. With the development of *in vivo* micro-CT, where disease progression and treatment can be monitored in a living animal over a period of time, this modality has become a standard tool for preclinical assessment of bone architecture during disease progression and treatment. The technique however, also allows to analyze bone structure *ex vivo* of bone biospies (21). Further adaptations such as nanoCT allow assessment at the submicron level and visualization of additional fine structures such as osteocyte lacunae and vascular channels. Synchrotron-based imaging or alternatives may even visualize osteocyte canaliculi in 3D, but these techniques are very exclusive (22).

FEM is a computational technique used to study bone biomechanics i.e., analysis of stress and strain, estimation of mechanical properties, fracture fixation design (implants), and fracture load prediction. Other techniques for biomechanical testing of bone are the 3-point bending test and compression test.

Nomenclature and classification of ROD

The standardization of nomenclature in 1987 (with an update in 2012) markedly improved the ability of histomorphometrists to communicate with each other and with nonhistomorphometrists, leading to a broader understanding and appreciation of histomorphometric data (23). Classical static and dynamic histomorphometric parameters are summarized in **Tables 1** and **2**. The classic description of the histologic abnormalities of ROD includes hyperparathyroid bone disease (osteitis fibrosa), adynamic bone disease, osteomalacia, and mixed uremic osteodystrophy.

High-turnover bone disease caused by excess PTH is characterized by an increased bone formation rate, a greater number and size of osteoclasts and an increase in the number of resorption lacunae with scalloped trabeculae, as well as abnormally high numbers of osteoblasts. There is an increased amount of osteoid (unmineralized bone), which may have a woven appearance that reflects a disordered collagen arrangement under conditions of rapid matrix deposition. High-turnover bone disease often is further characterized by the presence of marrow fibrosis (osteitis fibrosa).

In the past *mixed uremic bone disease* was simply defined as a bone pathology presenting features of both hyperparathyroidism and osteomalacia. At present differentiation is often made between type 1 mixed uremic bone disease characterized by an increased amount of osteoid, normal or increased bone formation rate with or without fibrosis and type 2 mixed uremic fibrosis having a normal amount of osteoid, normal bone formation rate with fibrosis. With the type 1 form the excess in osteoid surface that accompanies the increased bone

turnover may reflect a normal response to increased turnover rather than superimposed defective mineralization.

Osteomalacia is characterized by prolongation of the mineralization lag time as well as by increased thickness, surface area, and volume of osteoid. Osteomalacia was formerly linked to aluminum toxicity from both contamination of water in dialysates and use of aluminum-based phosphate binders. In case of aluminum-induced osteomalacia the number of (active) osteoblasts and osteoclasts is dramatically reduced. Other causes of osteomalacia that may be present in CKD patients include 25-hydroxyvitamin D deficiency, metabolic acidosis (which also inhibits both osteoblasts and osteoclasts), and hypophosphatemia.

Adynamic bone disease is a low-turnover bone state. In this disorder, the amount of osteoid thickness is normal or reduced, and there is no mineralization defect. The main findings are decreased numbers to even almost total absence of osteoclasts and osteoblasts and very low rates of bone formation. The main risk factors for adynamic bone disease are peritoneal dialysis, older age, corticosteroid use, and diabetes. It is thought that adynamic bone disease is not a naturally occurring separate disease, but rather a consequence of overtreatment of hyperparathyroidism with calcium (24), calcitriol, and/or calcimimetics. It may thus represent a state of relative (or functional) hypoparathyroidism. Other risk factors include ageing, diabetes, hypogonadism, peritoneal dialysis (25) and antiresorptive therapies. Aluminum overload, once a common cause of osteomalacia as well as adynamic bone disease has now almost completely disappeared as a consequence of proper water treatment and withdrawal or at least safe use of aluminum-based phosphate binding agents(26).

In 2006, the KDIGO consensus conference agreed on a new classification of renal osteodystrophy that addresses the most important bone abnormalities, which include changes in bone turnover (T), mineralization (M), and volume (V). The TMV classification is consistent with the classically used classification system(2).

Epidemiology of ROD

Renal bone disease occurs early in the course of CKD to become universal in patients with advanced stage disease. ROD is best characterized in patients with end stage renal disease. In these patients, for reasons which are not completely clear, a shift has been observed over recent decades from predominantly high (26) to predominantly low bone turnover disease. In recent large cohort studies (12;27), up to 60% of CKD stage 5(D) patients were shown to exhibit low bone turnover. Interestingly, low bone turnover is significantly more prevalent among whites as compared to blacks. Different from turnover, mineralization is only occasionally disturbed in contemporaneous dialysis patients. High, normal and low cancellous bone volume, finally, are observed in equal proportions of dialysis patients, at least among whites(27). Bone histomorphometry data in CKD patients not yet on dialysis are scarce. Studies dating back to the 1970's and 1990's pointed to high bone turnover disease as the most prevalent type of ROD in predialysis CKD (28-31). Literature data show that also in predialysis CKD a trend to lower bone turnover is occurring(32). Bone histomorphometry data in renal transplant recipients are equally scare and, overall, show a heterogeneous picture.

According to a recent prospective cohort study, bone turnover seems to further decline following successful renal transplantation(33). It should be acknowledged that there is heterogeneity of histologic abnormalities observed in patients with CKD, and that patients may develop different lesions as CKD progresses.

Bone biopsy indications

Bone biomarkers, imaging and histomorphometry may help to assess bone health (Evenepoel, Cavalier, D'Haese in press 2017). All these techniques have inherent limitations and provide complementary information and therefore should be considered in concert rather than alone in the management of complex metabolic bone diseases such as ROD. European experts in CKD-MBD agreed upon the following clinical indications for performing a bone biopsy: low impact fracture, unexplained bone pain, prior to parathyroidectomy (to confirm high bone turnover) or initiation of antiresorptive drugs (to exclude low bone turnover), unexplained hypercalcemia or radiologic abnormality, and suspected or proven overload or toxicity from heavy or rare metals(16). Also, a discordance between PTH and alkaline phosphatase level is considered an indication for a bone biopsy by almost 50% of the respondents. The KDIGO 2016 clinical practice guideline update on diagnosis, evaluation, prevention and treatment of CKD-MBD states that "in patients with CKD stage 3a-5D, it is reasonable to perform a bone biopsy if knowledge of type of ROD will impact treatment decisions (Not Graded)" (www.kdigo.org). More specifically, a bone biopsy should be considered in patients presenting with inconsistent PTH trends, unexplained fractures, refractory hypercalcemia, suspicion of osteomalacia, an atypical response to standard therapies for elevated PTH, or progressive decrease in BMD despite standard therapy. The goal of a bone biopsy would be to: (a) rule out atypical or unexplained bone pathology; (b) determine if patient has high or low turnover disease which may alter treatment choices (e.g. initiate or discontinue calcimimetics, vitamin D[analogs]); or (c) identify a mineralization defect that would imply specific treatment options. As an increasing body of evidence indicates that antiresorptive therapies are effective even in patients with CKD stage 3-4, the updated guideline no longer suggests a bone biopsy be performed prior to initiating antiresorptive therapy.

Conclusions

As a diagnostic procedure, a bone biopsy is characterized by several strengths, weaknesses, opportunities and threats (***figure 4***). The expansion of the therapeutic armamentarium to tackle bone disease calls for a greater use of bone sampling to ensure more effective and directed therapy. By adopting small needles and light sedation, procedural morbidity can be decreased substantially without losing diagnostic power and accuracy. This may lower the threshold for performing a bone biopsy. However, only when other perceived constraints such as lack of specialized centers with the expertise to interpret bone biopsies and time delay between biopsy and pathologic report are overcome, a bone biopsy may become a common practice in daily clinical care.

Tables:

Table 1: Primary Bone Histomorphometric Parameters

Measured static parameters – Goldner staining

Abbreviation	*Parameter*	*Unit*
Ab.Tt.Ar	Absolute Total Area	mm^2
Ab.B.Ar	Absolute Bone Area (mineralized + osteoid)	mm^2
Ab.O.Ar	Absolute Osteoid Area	mm^2
Ab.O.Pm	Absolute Osteoid Perimeter	mm
Ab.E.Pm	Absolute Eroded Perimeter	mm
Ab.Q.Pm	Absolute Quiescent Perimeter	mm
Ab.Ob.Pm	Absolute Osteoblast Perimeter	mm
Ab.Oc.Pm	Absolute Osteoclast Perimeter	mm

Measured Primary dynamic parameters - Tetracycline labels

Abbreviation	*Parameter*	*Unit*
Ab.Tt.Ar:	Absolute Total Area	mm^2
Ab.Tt.Pm:	Absolute Total Perimeter	mm
Ir.L.t	Labeling interval	days
Ir.L.Di:	Inter-Label Distance	µm
dL.Pm:	Double-Labeled Perimeter	µm
sL.Pm:	Single Labeled Perimeter	µm

Table 2: Secondary Bone Histomorphometric Parameters

Static parameters derived from primary measured parameters

Abbreviation	*Parameter*	*Unit*
B.Ar	Bone Area	%
O.Ar	Osteoid Area	%
O.Wi	Osteoid Width	µm
O.Pm	Osteoid Perimeter	%
E.Pm	Eroded Perimeter	%
Ob.Pm	Osteoblast perimeter	%
Oc.Pm	Osteoclast perimeter	%
Tb.Th	Trabecular Thickness	µm
Tb.N	Trabecular Number	mm^{-1}
Tb.Sp	Trabecular Separation	µm

Static parameters derived from primary measured parameters

Abbreviation	*Parameter*	*Unit*
sL.Pm	Single-labeled perimeter	%
dL.Pm	Double-labeled perimeter	%
MAR	Mineral Apposition Rate	µm/day
AjAr	Adjusted Apposition Rate	µm/day
BFR	Bone Formation Rate	$\mu m^2/mm^2/day$
Mlt	Mineralisation Lag Time	Days
Omt	Osteoid Maturation Time	Days

Figure: Bone biopsy: a SWOT analysis

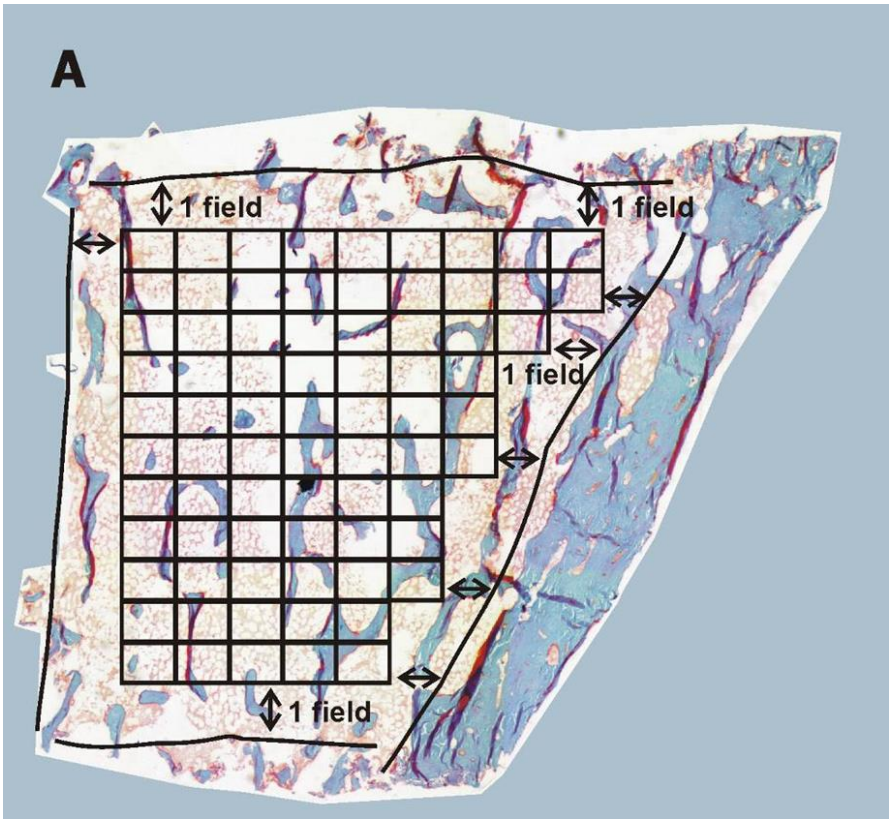

Figure 1: Goldner stained bone section. Mineralized bone stains blue, while osteoid is stained red. For histomorphometric measurement a microscopic field is kept between the measured region and the cortical bone and the edge of the biopsy. Adjacent fields are measured until the entire section is measured. Adjacent sections are analyzed in case the number of fields/section is insufficient. Adapted from G.J Behets(34)

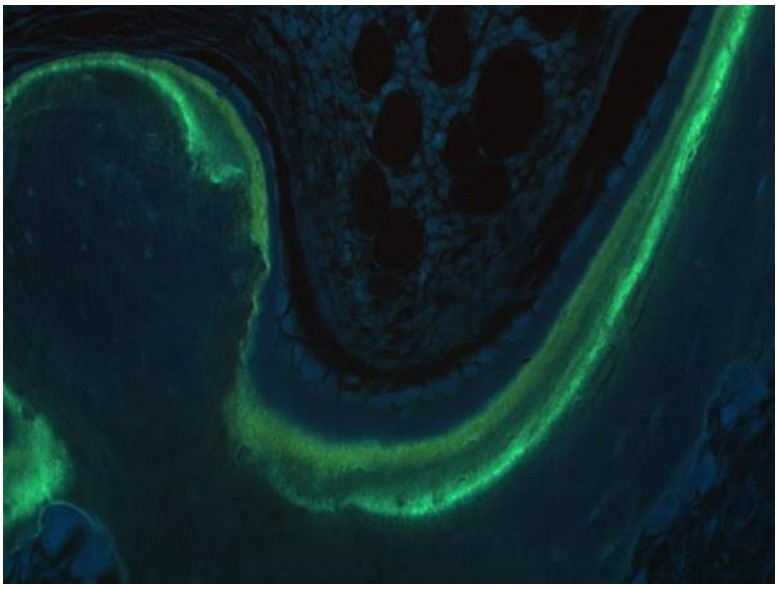

Figure 2: Tetracycline fluorescence. The tetracyclins are incorporated into the bone during active mineralization and form distinct bands that can be visualized under fluorescence microscopy. To further aid the visual recognition of the labels, two different tetracyclins which fluoresce with different colours can be used. Adapted from G.J Behets(34).

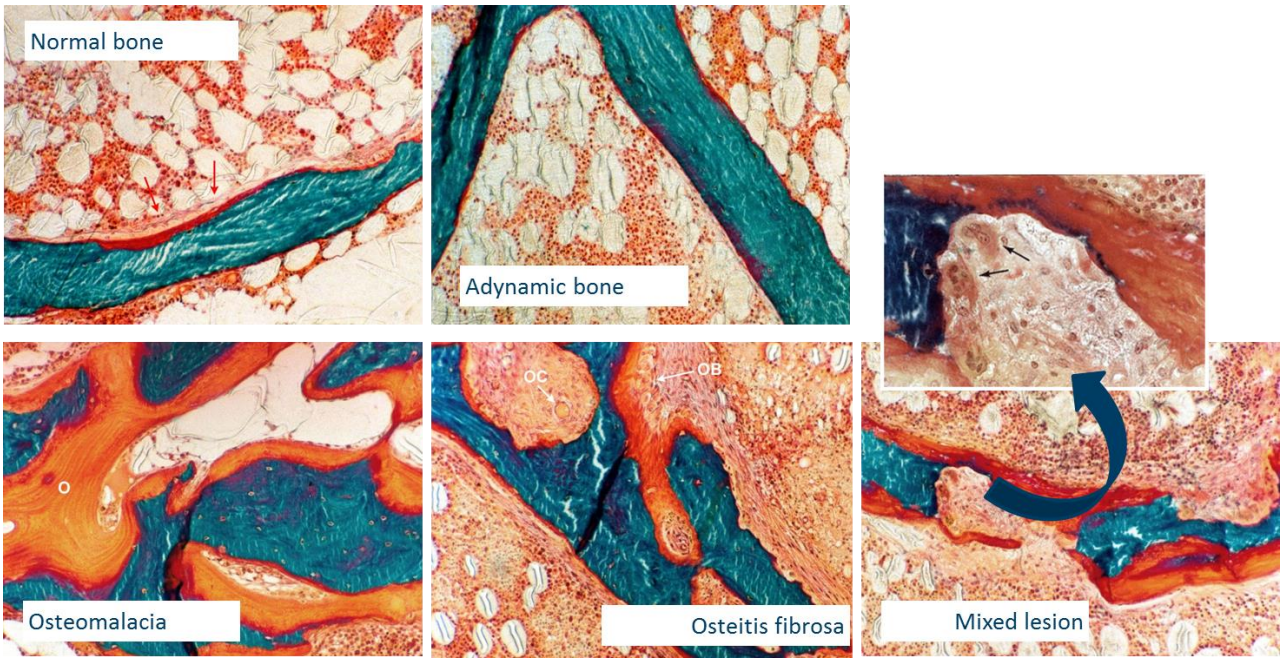

Figure 3: Histological features of the different types of renal osteodystrophy. Normal bone (red arrows): osteoblasts depositing osteoid; Osteomalacia (O): osteoid; Osteitis fibrosa (OB): enlarged active osteoblasts, (OC) osteoclast; Mixed lesion (inset): active multinucleated osteoclasts resorbing bone. Adapted from G.J Behets (34).

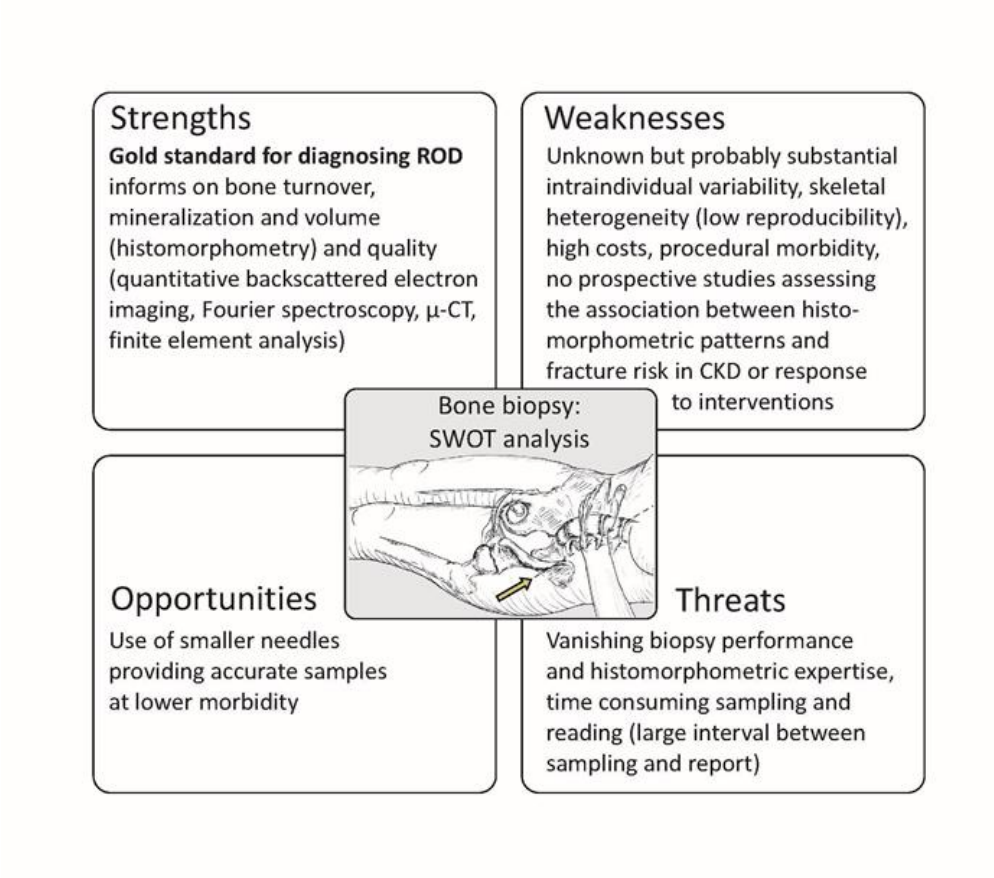

Figure 4: Bone biopsy: a SWOT analysis

Reference List

1. Coresh J, Selvin E, Stevens LA et al. Prevalence of Chronic Kidney Disease in the United States. JAMA 2007; 298(17):2038-2047.

2. Moe S, Drueke T, Cunningham J et al. Definition, evaluation, and classification of renal osteodystrophy: A position statement from Kidney Disease: Improving Global Outcomes (KDIGO). kidney int 2006; 69(11):1945-1953.

3. Jadoul M, Albert JM, Akiba T et al. Incidence and risk factors for hip or other bone fractures among hemodialysis patients in the Dialysis Outcomes and Practice Patterns Study. kidney int 2006; 70(7):1358-1366.

4. Ball AM, Gillen DL, Sherrard D et al. Risk of Hip Fracture Among Dialysis and Renal Transplant Recipients. JAMA 2002; 288(23):3014-3018.

5. Tentori F, McCullough K, Kilpatrick RD et al. High rates of death and hospitalization follow bone fracture among hemodialysis patients. Kidney Int 2014; 85(1):166-173.

6. Naylor KL, McArthur E, Leslie WD et al. The three-year incidence of fracture in chronic kidney disease. Kidney Int 2014; 86(4):810-818.

7. Nickolas TL, Stein EM, Dworakowski E et al. Rapid cortical bone loss in patients with chronic kidney disease. J Bone Miner Res 2013; 28(8):1811-1820.

8. Malluche HH, Porter DS, Monier-Faugere MC, Mawad H, Pienkowski D. Differences in bone quality in low- and high-turnover renal osteodystrophy. J Am Soc Nephrol 2012; 23(3):525-532.

9. Miller PD. The role of bone biopsy in patients with chronic renal failure. Clin J Am Soc Nephrol 2008; 3 Suppl 3:S140-S150.

10. Wilson LM, Rebholz CM, Jirru E et al. Benefits and Harms of Osteoporosis Medications in Patients With Chronic Kidney Disease: A Systematic Review and Meta-analysis. Ann Intern Med 2017.

11. Evenepoel P, Bover J, Urena TP. Parathyroid hormone metabolism and signaling in health and chronic kidney disease. Kidney Int 2016; 90(6):1184-1190.

12. Sprague SM, Bellorin-Font E, Jorgetti V et al. Diagnostic Accuracy of Bone Turnover Markers and Bone Histology in Patients With CKD Treated by Dialysis. Am J Kidney Dis 2016; 67(4):559-566.

13. Malluche HH, Monier-Faugere MC. The role of bone biopsy in the management of patients with renal osteodystrophy. J Am Soc Nephrol 1994; 4(9):1631-1642.

14. Torres PU, Bover J, Mazzaferro S, de Vernejoul MC, Cohen-Solal M. When, how, and why a bone biopsy should be performed in patients with chronic kidney disease. Semin Nephrol 2014; 34(6):612-625.

15. Hernandez JD, Wesseling K, Pereira R, Gales B, Harrison R, Salusky IB. Technical approach to iliac crest biopsy. Clin J Am Soc Nephrol 2008; 3 Suppl 3:S164-S169.

16. Evenepoel P, D'Haese P, Bacchetta J et al. Bone biopsy practice patterns across Europe: the European renal osteodystrophy initiative-a position paper. Nephrol Dial Transplant 2017.

17. Amling M, Herden S, Posl M, Hahn M, Ritzel H, Delling G. Heterogeneity of the skeleton: comparison of the trabecular microarchitecture of the spine, the iliac crest, the femur, and the calcaneus. J Bone Miner Res 1996; 11(1):36-45.

18. Sutton-Smith P, Beard H, Fazzalari N. Quantitative backscattered electron imaging of bone in proximal femur fragility fracture and medical illness. J Microsc 2008; 229(Pt 1):60-66.

19. Casanova M, Balmelli A, Carnelli D, Courty D, Schneider P, Muller R. Nanoindentation analysis of the micromechanical anisotropy in mouse cortical bone. R Soc Open Sci 2017; 4(2):160971.

20. Paschalis EP, Mendelsohn R, Boskey AL. Infrared assessment of bone quality: a review. Clin Orthop Relat Res 2011; 469(8):2170-2178.

21. Campbell GM, Sophocleous A. Quantitative analysis of bone and soft tissue by micro-computed tomography: applications to ex vivo and in vivo studies. Bonekey Rep 2014; 3:564.

22. Dierolf M, Menzel A, Thibault P et al. Ptychographic X-ray computed tomography at the nanoscale. Nature 2010; 467(7314):436-439.

23. Dempster DW, Compston JE, Drezner MK et al. Standardized nomenclature, symbols, and units for bone histomorphometry: a 2012 update of the report of the ASBMR Histomorphometry Nomenclature Committee. J Bone Miner Res 2013; 28(1):2-17.

24. Ok E, Asci G, Bayraktaroglu S et al. Reduction of Dialysate Calcium Level Reduces Progression of Coronary Artery Calcification and Improves Low Bone Turnover in Patients on Hemodialysis. J Am Soc Nephrol 2016; 27(8):2475-2486.

25. de Oliveira RA, Barreto FC, Mendes M et al. Peritoneal dialysis per se is a risk factor for sclerostin-associated adynamic bone disease. Kidney Int 2015; 87(5):1039-1045.

26. Ballanti P, Wedard BM, Bonucci E. Frequency of adynamic bone disease and aluminum storage in Italian uraemic patients--retrospective analysis of 1429 iliac crest biopsies. Nephrol Dial Transplant 1996; 11(4):663-667.

27. Malluche HH, Mawad HW, Monier-Faugere MC. Renal osteodystrophy in the first decade of the new millennium: analysis of 630 bone biopsies in black and white patients. J Bone Miner Res 2011; 26(6):1368-1376.

28. Malluche HH, Ritz E, Lange HP et al. Bone histology in incipient and advanced renal failure. Kidney Int 1976; 9(4):355-362.

29. Hamdy NA, Kanis JA, Beneton MN et al. Effect of alfacalcidol on natural course of renal bone disease in mild to moderate renal failure. Br Med J 1995; 310(6976):358-363.

30. Coen G, Ballanti P, Bonucci E et al. Renal osteodystrophy in predialysis and hemodialysis patients: comparison of histologic patterns and diagnostic predictivity of intact PTH. Nephron 2002; 91(1):103-111.

31. Lindergard B, Johnell O, Nilsson BE, Wiklund PE. Studies of bone morphology, bone densitometry and laboratory data in patients on maintenance hemodialysis treatment. Nephron 1985; 39(2):122-129.

32. Spasovski GB, Bervoets ARJ, Behets GJS et al. Spectrum of renal bone disease in end-stage renal failure patients not yet on dialysis. Nephrol Dial Transplant 2003; 18(6):1159-1166.

33. Evenepoel P, Behets GJ, Viaene L, D'Haese PC. Bone histomorphometry in de novo renal transplant recipients indicates a further decline in bone resorption 1 year posttransplantation. Kidney Int 2017; 91(2):469-476.

34. Behets GJ. Lanthanum carbonate and bone. University of Leiden, The Netherlands, 2005.