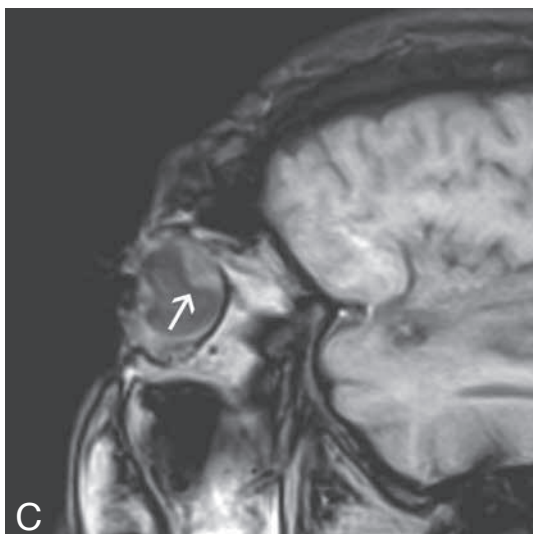
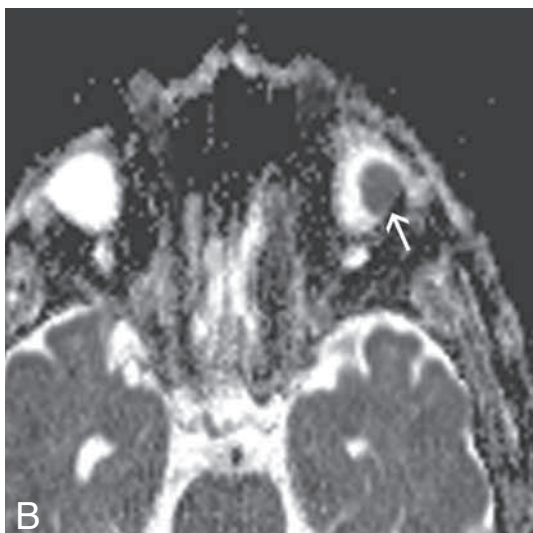
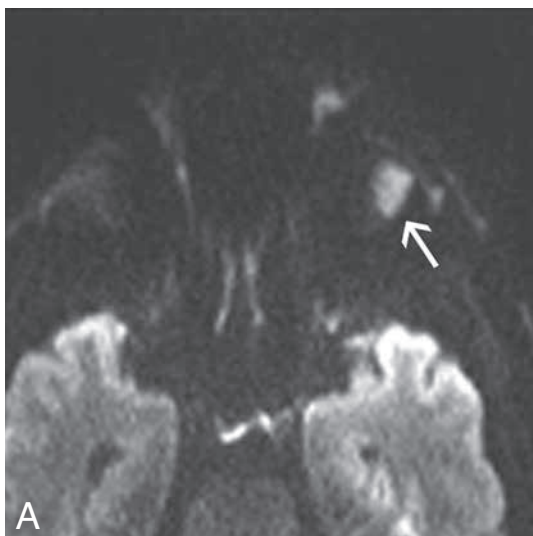


## IMAGES IN CLINICAL RADIOLOGY



### *Diffusion restriction of posterior uveal melanoma on MR imaging*

R. Semnic<sup>1,2</sup>, D. Kozic<sup>1,2</sup>, K. Petrovic<sup>2,3</sup>, F. M. Vanhoenacker<sup>4,5,6</sup>

A 55-year-old male with clinical and ophthalmological signs of retinal ablation was referred for orbital magnetic resonance imaging (MRI). MR scan revealed a small tumor nodule in the posterolateral part of left eye globe as a cause of ablation. Tumor showed high signal on transverse diffusion weighted image (DWI) (Fig. A, arrow), low signal on apparent diffusion coefficient image (Fig. B, arrow), consistent with restricted diffusion. The nodule had intermediate signal on T1 sagittal weighted unenhanced image (Fig. C, arrow). The patient underwent left eye enucleation with histopathologically proved uveal melanoma.

#### *Comment*

Uveal melanomas are classified into anterior – when tumor arises from the iris and posterior if arises from the choroid or ciliary body. Origin of the posterior uveal melanoma is choroidal pigment cells. For the diagnosis of these tumors, standard MRI plays a major role, showing in most cases tumor paramagnetic melanin content. However, in case of tumor necrosis or the presence of blood degradation products, DWI, as a non-contrast sequence, may provide additional signal information. DWI is routinely used for brain tumor differentiation but just lately is used for evaluation of orbital masses. Restricted diffusion in uveal melanomas could represent new, potentially reliable signal intensity marker, not yet well known in literature.

#### *Reference*

1. Erb-Eigner K., Willerding G., Taupitz M., Hamm B., Asbach P.: Diffusion-weighted imaging of ocular melanoma. *Invest Radiol*, 2013, 48: 702-707.

---

1. Institute of Oncology, Sremska Kamenica, 2. Faculty of Medicine, University Of Novi Sad, Serbia, 3. Centre of Radiology, Faculty of Medicine, University of Novi Sad, Serbia. 4. Department of Radiology, AZ Sint-Maarten Duffel-Mechelen, Mechelen, 5. Department of Radiology, Antwerp University Hospital, Edegem, 6. University of Ghent, Faculty of Medicine and Health sciences, Ghent.