

# Monoclonal gammopathy of renal significance (MGRS): histopathologic classification, diagnostic workup, and therapeutic options

K. Amaador<sup>1</sup>, H. Peeters<sup>2</sup>, M.C. Minnema<sup>3</sup>, T.Q. Nguyen<sup>4</sup>, A. Dendooven<sup>5,6,7</sup>, J.M.I. Vos<sup>8</sup>, A.J. Croockewit<sup>9</sup>, N.W.C.J. van de Donk<sup>10</sup>, J.F.M. Jacobs<sup>11</sup>, J.F.M. Wetzels<sup>12</sup>, B. Sprangers<sup>2,13</sup>, A.C. Abrahams<sup>1\*</sup>

<sup>1</sup>Department of Nephrology and Hypertension, University Medical Centre Utrecht, Utrecht, the Netherlands; <sup>2</sup>Department of Nephrology, University Hospitals Leuven, Leuven, Belgium; <sup>3</sup>Department of Haematology, University Medical Centre Utrecht Cancer Centre, Utrecht, the Netherlands; <sup>4</sup>Department of Pathology, University Medical Centre Utrecht, Utrecht, the Netherlands; <sup>5</sup>Department of Pathology, University Hospital of Antwerp, Belgium; <sup>6</sup>University of Antwerp, Belgium; <sup>7</sup>University Hospital of Ghent, Belgium; <sup>8</sup>Department of Haematology, Amsterdam University Medical Centre, Amsterdam Medical Centre, Amsterdam, the Netherlands; <sup>9</sup>Department of Haematology, Radboud University Medical Centre, Nijmegen, the Netherlands; <sup>10</sup>Department of Haematology, Amsterdam University Medical Centre, Free University Amsterdam, Amsterdam, the Netherlands; <sup>11</sup>Department of Laboratory Medicine, Radboud University Medical Centre, Radboud Institute for Molecular Life Sciences, Nijmegen, the Netherlands; <sup>12</sup>Department of Nephrology, Radboud University Medical Centre, Nijmegen, the Netherlands; <sup>13</sup>Department of Microbiology and Immunology, Laboratory of Experimental Transplantation, KU Leuven, Leuven, Belgium.

\*Corresponding author: A.C.Abrahams@umcutrecht.nl

## ABSTRACT

Monoclonal gammopathy of renal significance (MGRS) includes all kidney disorders caused by a monoclonal protein (M-protein) secreted by a small plasma cell clone or other B-cell clones in patients who do not meet the diagnostic criteria for multiple myeloma or other B-cell malignancies. The underlying disorder in patients with MGRS is generally consistent with monoclonal gammopathy of undetermined significance (MGUS). MGRS-associated kidney disorders are various and the list is still expanding. The kidney disorders can manifest as glomerular diseases, tubulopathies, and vascular involvement with varying clinical presentations.

Diagnosis is often challenging because of the wide spectrum of MGRS, and it is difficult to establish a pathogenic link between the presence of the M-protein or serum free light chains and kidney diseases; further complicating accurate diagnosis is the high incidence of MGUS and/or kidney disorders, independent of MGRS, in elderly patients. However, MGRS can significantly impair kidney function. Because treatment can stop and also reverse kidney disease, early recognition is

of great importance. A combined haematologic and nephrologic approach is crucial to establish the causative role of the M-protein in the pathogenesis of kidney disease. Clone-directed therapy, which may include autologous stem cell transplantation in eligible patients, often results in improved outcomes. In this review, we discuss the histopathologic classification of MGRS lesions, provide a renal and haematologic diagnostic workup, discuss treatment options for MGRS, and introduce a Benelux MGRS Working Group.

## KEYWORDS

MGRS, MGUS, paraproteinaemia-associated kidney disease, plasma cell dyscrasia, monoclonal immunoglobulin, free light chain

## INTRODUCTION

A circulating monoclonal protein (M-protein) is present in approximately 3% of people aged 50 years and older

and increases to 5% after 70 years of age.<sup>1,2</sup> Patients with this circulating M-protein are diagnosed with monoclonal gammopathy of undetermined significance (MGUS) if the M-protein is < 30 g/l and a bone marrow (BM) examination shows < 10% monoclonal plasma cells with absence of end organ damage or other multiple myeloma defining events.<sup>2,3</sup> Monoclonal gammopathies can be completely asymptomatic in the case of MGUS, but monoclonal gammopathy is sometimes associated with potentially severe organ damage whereby the criteria for overt multiple myeloma (MM) or other malignant lymphoproliferative disorders such as B-cell non-Hodgkin

lymphoma, including Waldenström's macroglobulinaemia (WM) or chronic lymphocytic leukaemia (CLL), are not met (table 1).

Therefore in 2012, the term monoclonal gammopathy of renal significance (MGRS) was introduced by the International Kidney and Monoclonal Gammopathy Research Group (IKMG) to describe a spectrum of kidney diseases due to M-protein secreted by a small B-cell, lymphoplasmacytic, or plasma cell clone not meeting any current haematologic criteria for specific therapy.<sup>4</sup> The term MGRS was recently updated by the IKMG and now

**Table 1.** Definitions of B-cell and plasma cell proliferative disorders

Plasma cell disorder	Criteria
Multiple myeloma	Clonal plasma cells in BM $\geq$ 10% or biopsy-proven bony or extramedullary plasmacytoma, and any one or more of the following myeloma defining events <sup>1</sup> : - Hypercalcaemia: serum calcium > 0.25 mmol/l higher than upper limit of normal or > 2.75 mmol/l - Renal insufficiency: creatinine clearance < 40 ml per min or serum creatinine > 177 $\mu$ mol/l - Anaemia: (Hb < 6.2 mmol/l) - Bone lesions: one or more bone lesions on skeletal radiography, CT, or PET-CT Or any of the following biomarkers of progression <sup>2</sup> : - Clonal BM plasma cells $\geq$ 60% - 'Involved:uninvolved serum free light chain ratio' $\geq$ 100 - > 1 focal lesions on MRI studies
Smoldering multiple myeloma	Serum M-protein $\geq$ 30 g/l or urinary M-protein $\geq$ 500 mg/24 h and/or clonal BM plasma cells 10–60% Absence of SLiM-CRAB or amyloidosis
Waldenström's macroglobulinaemia	Lymphoplasmacytic infiltrate in BM $\geq$ 10% Serum monoclonal IgM of any level Symptoms of tumour mass/infiltration (adenopathy, anaemia etc) IgM-mediated symptoms can be present
Smoldering Waldenström's macroglobulinaemia	Lymphoplasmacytic infiltrate in BM $\geq$ 10% Serum monoclonal IgM of any level Absence of symptomatic tumour mass/infiltration (adenopathy, anaemia etc)
Non-IgM MGUS	Serum M-protein < 30 g/l Clonal plasma cells in BM < 10% Absence of SLiM-CRAB or amyloidosis
IgM MGUS	Serum IgM M-protein < 30 g/l BM involvement with lymphoplasmacytoid cells < 10% Absence of anaemia, constitutional symptoms, hyperviscosity, lymphadenopathy, hepatosplenomegaly, or any organ damage attributed to the lymphoproliferative disorder
Chronic lymphocytic leukaemia	Presence of $\geq$ 5x10 <sup>9</sup> /l clonal B lymphocytes in peripheral blood Phenotype: CD5+, CD19+, CD23+, CD20+/-, sIg +/-
Monoclonal B lymphocytosis	Clonal B lymphocytes < 5x10 <sup>9</sup> /l in peripheral blood Presence of CLL phenotype No evidence of lymphoma, infection, or autoimmune conditions

<sup>1</sup>Myeloma defining events: organ damage attributed to the underlying plasma cell disorder often abbreviated as 'CRAB' (hypercalcaemia, renal failure, anaemia, and bone disease).

<sup>2</sup>These three biomarkers are abbreviated to 'SLiM' (S  $\geq$  60% clonal plasma cells in BM; Li = light chains, kappa-to-lambda or lambda-to-kappa ratio  $\geq$  100; M  $\geq$  1 focal lesion by MRI).

BM = bone marrow; MGUS = monoclonal gammopathy of undetermined significance; M-protein = monoclonal protein; CLL = chronic lymphocytic leukaemia; Hb = haemoglobin; CT = computed tomography; PET-CT = positron emission tomography-computed tomography; MIR = magnetic resonance imaging; IgM = Immunoglobulin M; CD = cluster of differentiation; sIg = surface immunoglobulin

includes all B-cell or plasma cell proliferative disorders that produce a nephrotoxic M-protein such as smoldering MM, smoldering WM, and monoclonal B-cell lymphocytosis (MBL). Low-grade B-cell lymphomas and low-grade CLL with associated renal disease are also included in the updated definition of MGRS. M-proteins secreted by this clone can be directly nephrotoxic and also indirectly nephrotoxic by complement activation. In addition to kidney involvement, these small B-cell or plasma cell clones can also involve other organs such as skin and peripheral nerves and therefore, the concept of monoclonal gammopathy of clinical significance (MGCS) was recently introduced.<sup>4</sup>

The current treatment guidelines do not recommend anti-tumour therapy in patients with MGUS and smoldering myeloma or asymptomatic WM. These patients are usually monitored as they can remain asymptomatic for years and only in the case of developing or impending symptoms can therapy be introduced.<sup>3,5</sup> In patients with MGRS, this approach may be inadequate, as the M-protein plays a direct role in the pathogenesis of kidney disease despite the absence of high tumour burden. In these cases, the monoclonal gammopathy is of known significance as kidney disease is present with increased risk of progression to end stage renal disease (ESRD). In addition, cases of recurrence after kidney transplantation have been described.<sup>6-15</sup>

In this review, we illustrate the spectrum of MGRS with the histopathologic classification, present a renal and haematologic diagnostic workup that may assist in the diagnosis of MGRS, and discuss treatment options for the underlying haematologic disorder to improve renal and patient outcome. Ideally, patients with MGRS should be evaluated by a multidisciplinary team that includes nephrologists, haematologists, and nephropathologists with expertise in these conditions and therefore, we have established a Benelux MGRS Working Group (Belgium, Netherlands, Luxemburg) that can be consulted in cases of suspected or proven MGRS.

## EPIDEMIOLOGY OF MONOCLONAL GAMMOPATHY OF RENAL SIGNIFICANCE

Little is known about the epidemiology of most MGRS disorders. Shaik et al. reported a prevalence of MGRS of 6% in individuals diagnosed with MGUS in the United States<sup>16</sup> and Steiner et al. reported a prevalence of 1.5% of MGRS in 2935 patients diagnosed with MGUS.<sup>17</sup> Regarding specific disease data, amyloid light chain (AL amyloidosis) was the cause of ESRD in 1.15% of patients in the Netherlands who started dialysis in 2016.<sup>18</sup> Renal biopsy registries show that a diagnosis of light chain deposition disease (LCDD) is made in 0.3-0.5% of all kidney biopsies, with an identified underlying MGUS in approximately 41% of these cases.<sup>19,20</sup> All other types of MGRS have unknown incidence and/or

prevalence as they are only described in the form of case reports and small case series. Although the recognition of MGRS as a new entity has increased in recent years, under-reporting of this disease still exists.

## PATHOPHYSIOLOGY AND HISTOPATHOLOGIC CLASSIFICATION

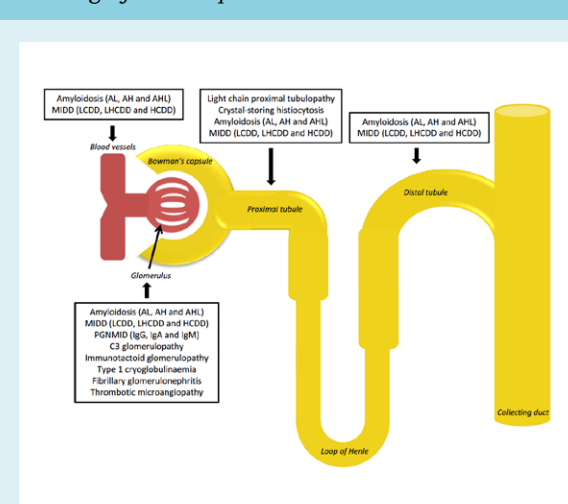
Kidney diseases associated with monoclonal gammopathy are various and the list of recognized disease entities is still expanding. Renal lesions associated with MGRS can be classified by localisation (figure 1) and include glomerular, tubulointerstitial, and vascular patterns of injury, single or in combination.<sup>21-23</sup>

In addition to a direct toxic effect of M-protein deposits, M-proteins can also have autoantibody activity which results in complement activation and subsequent deposition of complement factors in the kidney (indirect mechanism). The type of kidney injury seems to be dependent on the characteristics of the M-protein.<sup>24,25</sup>

### Light chain (AL), heavy chain (AH), and heavy and light chain (AHL) amyloidosis

Extracellular deposition of amyloid in glomeruli, tubules, and/or vessels is characteristic for renal amyloidosis. In most cases, the M-protein-related amyloidosis is derived from fragments of monoclonal light chains

**Figure 1. Spectrum of monoclonal gammopathy of renal significance by localisation**



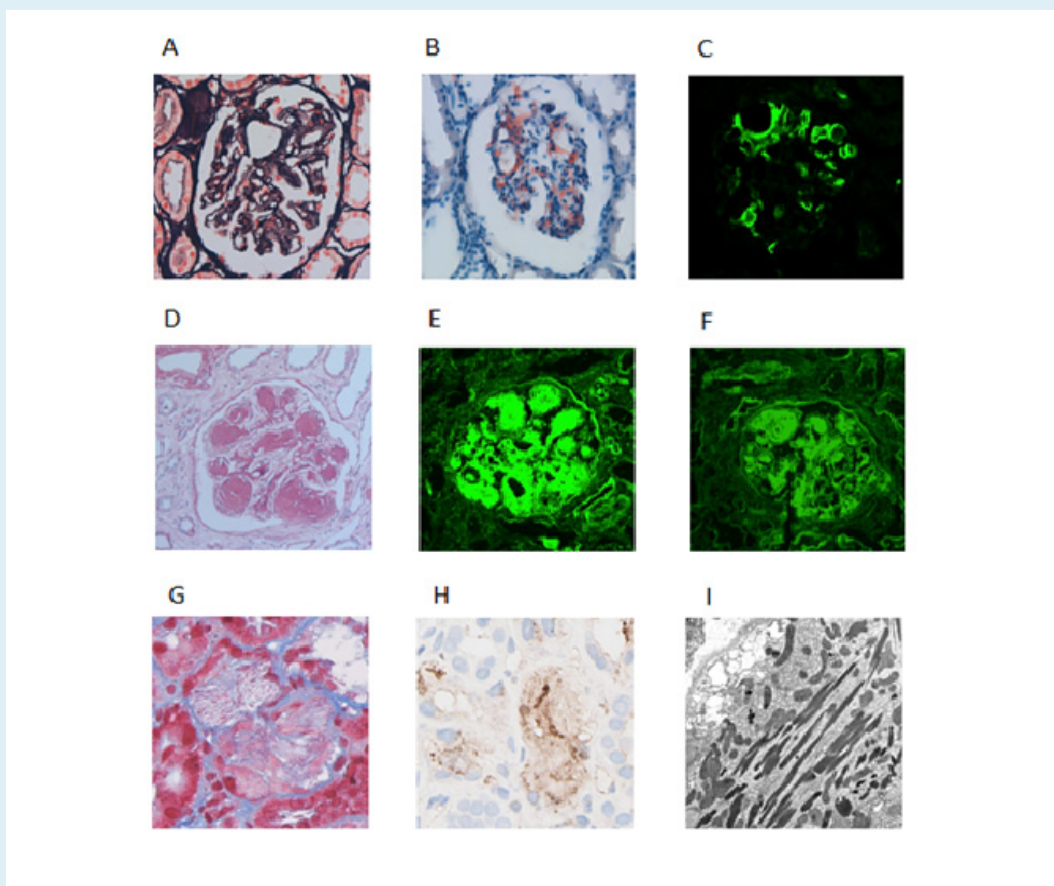
AL = light chain amyloidosis; AH = heavy chain amyloidosis; AHL = heavy and light chain amyloidosis; MIDD = monoclonal immunoglobulin deposition disease; LCDD = light chain deposition disease; LHCCDD = light and heavy chain deposition disease; HCDD = heavy chain deposition disease; PGNMID = proliferative glomerulonephritis with monoclonal immunoglobulin deposits

(LCs), which are more often of the  $\lambda$  than  $\kappa$  isotype<sup>26</sup>, and rarely from fragments of intact immunoglobulin (Ig) or heavy chains only. With light microscopy (LM) amyloid appears as acellular deposits that stain pale eosinophilic on haematoxylin and eosin, periodic acid–Schiff (PAS)-negative or weak, trichrome-blue or gray, and silver-negative (figure 2A). Amyloid is the only MGRS lesion that is Congo red-positive and identified by apple green birefringence under polarised light (figure 2B). With immunofluorescence (IF) microscopy, monotypic staining of the amyloid deposits can be present (figure 2C). With electron microscopy (EM), amyloid deposits in the kidney appear as nonbranching fibrils that are randomly arranged with a thickness between 7 and 14 nm and can be seen

within the mesangium, glomerular or tubular basement membranes, interstitium, and vessels.<sup>21</sup> AL/AH/AHL amyloidosis is a systemic disease and most patients present with two to four organs involved.<sup>27</sup>

**Monoclonal immunoglobulin deposition disease (MIDD)**  
MIDD includes three subtypes depending on the composition of the deposits. Light chain deposition disease (LCDD) is the most common subtype, primarily the  $\kappa$  type. The kidneys are almost always affected and extrarenal involvement is common in the heart, liver, and lungs.<sup>21</sup> Under LM, a nodular glomerulosclerosis pattern is classic for MIDD and nodular mesangial expansion along with thickening of the glomerular and tubular basement

**Figure 2.** Selected cases of MGRS identified by renal biopsy



- A. Subtle silver-lucency of the mesangium in a case of amyloidosis.  
 B. Corresponding Congo red staining highlighting mesangial amyloid deposition. Applegreen birefringence was present (not shown).  
 C. Corresponding lambda light chain immunofluorescence. Kappa was negative, as well as immunofluorescence for the heavy chains.  
 D. PAS staining of a case of light- and heavy chain deposition disease (LHCDD) showing nodular glomerulosclerosis.  
 E. Corresponding IgG immunofluorescent staining of LHCDD.  
 F. Kappa showed similar staining.  
 G. A case of light chain proximal tubulopathy. Masson trichrome stain showed acute tubular damage with fuchsinophilic crystal formation in the proximal tubules.  
 H. Kappa staining was positive in the cytoplasm of proximal tubules. Lambda staining was negative (not shown).  
 I. Electron microscopy showed proximal tubules with abundant needle-shaped crystals.  
 MGRS = monoclonal gammopathy of renal significance; PAS = periodic acid–Schiff; LHCDD = light- and heavy chain deposition disease; IgG = immunoglobulin G

membranes (GBM and TBM) is also present (figure 2D). A variable degree of tubular atrophy, interstitial fibrosis, and inflammation can also be present as nonspecific findings.

With IF, LCDD presents with monotypical linear amorphous LC deposits in the mesangium, and along the glomerular and tubular basement membranes. In light and heavy chain deposition disease (LHCDD) and heavy chain deposition disease (HCDD), linear deposition of monotypic  $\gamma$ ,  $\alpha$ , or  $\mu$  HC along the GBM and TBM are seen (figure 2E, F). The granular deposits appear nonfibrillar and electron-dense and are located in the glomerular subendothelium and mesangium, and on the outer aspect of the tubular basement membrane, as observed by EM.<sup>21,28,29</sup>

#### **Proliferative glomerulonephritis with monoclonal immunoglobulin deposits (PGNMID)**

PGNMID is the result of glomerular deposition of monoclonal IgG or rarely, IgA or IgM. LM shows predominantly endocapillary proliferation and/or membranoproliferative glomerulonephritis (MPGN), with or without membranous features. As seen by IF, the IgG deposits are confined to glomeruli and consist of a single light chain isotype and a single heavy chain subtype, most commonly IgG $\kappa$ . Positive staining for C3 and C1q indicates activation of complement system. Granular, non-organized deposits, typically in a subendothelial and mesangial distribution are characteristic findings with EM.<sup>21,30-32</sup>

#### **Monoclonal gammopathy-associated C3 glomerulopathy (C3GP)**

C3GP results in kidney dysfunction via an indirect mechanism. In most cases, the mechanism by which the presence of an M-protein, mostly IgG, predisposes to C3GP is not clear. A possible mechanism has been suggested whereby the M-protein acts as an autoantibody to C3 convertase or as an autoantibody to other complement-regulating proteins which results in dysregulation of the alternative complement pathway.<sup>15,33</sup>

C3GP is characterized by glomerular deposition of the complement component C3 fragment at least two orders of intensity stronger than any combination of IgG, IgM, IgA, and C1q. Mesangial proliferative, membranoproliferative, or endocapillary proliferative glomerulonephritis are the usual patterns on LM. Electron-dense deposits located in the mesangium and subendothelium can be seen with EM.<sup>34</sup>

#### **Immunotactoid glomerulopathy (ITG)**

ITG is often monoclonal in nature, in contrast to fibrillary glomerulonephritis (FGN).<sup>9</sup> ITG is characterized by either an MPGN or diffuse proliferative pattern as

observed with LM. Organized and parallel-oriented microtubular M-protein deposits with either  $\kappa$  or  $\lambda$  light chain restrictions are seen. These microtubular glomerular deposits are mostly composed of IgG, are Congo red-negative, contain distinct hollow centers, and stain for complement (C3) by IF. They are focally arranged in parallel arrays and are usually greater than 30-90 nm in diameter as seen by EM.<sup>21,35</sup>

#### **Cryoglobulinaemia-associated glomerulonephritis (CGG)**

Cryoglobulinaemia (CG) is composed of three types of which type I and type II are associated with monoclonal proteins. Type I CG is characterized by precipitation of M-protein when exposed to a temperature lower than 37°C and dissolve once the serum is heated. It can cause CGG or vasculitis. With LM, the characteristic finding of CG is a MPGN with endocapillary proliferation. Numerous intracapillary infiltrating leukocytes and large PAS-positive intraluminal immune deposits (protein hyaline thrombi) can be seen with LM. Intraluminal Ig and deposition of C3, C4, C1q are seen with IF and substructures like microtubules, fibrils, and finger print deposits can be observed with EM.<sup>21,31,36</sup> In type II CG, the monoclonal Ig is bound to the constant domain of polyclonal Ig heavy chains forming a complex. The most common cause of type II CG is hepatitis C infection. Approximately 10-30% of cases are not related to hepatitis C infection but to B-cell lymphoproliferative disorders.<sup>37</sup>

#### **Paraprotein-associated fibrillary glomerulonephritis (FGN)**

Although FGN is often polyclonal in nature, it can also be associated with organized glomerular M-protein deposits which have a fibrillary amyloid-like appearance as observed with EM. An MPGN pattern is commonly seen with LM. Unlike amyloid, lesions are Congo red-negative.<sup>38</sup> IF staining for IgG (mostly IgG $\lambda$ , sometimes IgG $\mu$ ) and C3 is common in these fibrils, which have a diameter ranging from 16 to 24 nm, as observed with EM.<sup>35</sup>

#### **Monoclonal gammopathy-associated thrombotic microangiopathy (TMA)**

TMA associated with monoclonal gammopathy is a relatively new entity with few cases described in the literature. TMA with no other cause than gammopathy was first described in three cases that were part of a large cohort of patients with WM and a number of single case reports.<sup>39</sup> The causal relation between the gammopathy and TMA was further supported by an unexpected high occurrence of monoclonal gammopathy in patients with TMA reported by Ravindran et al.,<sup>40</sup> with an incidence of 21% in patients aged 50 and older. How monoclonal gammopathy induces TMA is not fully understood and remains to be elucidated. Kidney injury

in TMA is characterised by thrombus in the glomerular capillaries, swelling of the endothelium, mesangiolysis with microaneurysms, and double-contour formation of the glomerular capillary walls. Acute tubular injury with differing degrees of tubulointerstitial scarring and thrombus in the arteries and arterioles can also be seen.<sup>40</sup>

#### Light chain proximal tubulopathy (LCPT)

LCPT is characterised by proximal tubular dysfunction secondary to cytoplasmic inclusions of LCs as crystals within the endolysosomal compartment of proximal tubular cells. The accumulated LCs are almost always of the  $\kappa$  class and are rod- or rhomboid-shaped hypereosinophilic and PAS-negative under LM (figure 2G, H). For the visualization of the intracytoplasmic crystalline inclusions of  $\kappa$  LC in proximal tubular cells by IF, pronase digestion might be necessary.<sup>41</sup> The electron-dense intracytoplasmic inclusions can be seen with EM (figure 2I). Some inclusions appear to be membrane-bound within the endosomes or lie free in the cytosol.<sup>42</sup> Recently, it was shown that LCPT without crystal formation is actually more common than LCPT with crystal formation and is usually associated with accumulation of  $\lambda$  LCs. LCPT with crystal formation seems to be more frequent in younger patients and is associated with Fanconi's syndrome (FS) and a worse kidney function compared with noncrystalline LCPT, as reported in one study.<sup>42</sup> However, little is known about the clinical significance of crystalline vs noncrystalline deposits because of their rarity.<sup>43</sup> It could be argued whether noncrystalline LCPT is pathologic, given the physiologic reabsorption of LCs occurring in the proximal tubule.

#### Crystal-storing histiocytosis (CSH)

In CSH, the M-protein crystals accumulate within the lysosomes of histiocytes accumulated in the interstitium. LM shows that the crystal-containing histiocytes are accompanied by interstitial fibrosis and tubular atrophy and IF demonstrates that the accumulated crystals are almost always LCs of the  $\kappa$  class. Diagnosis of CSH can be challenging since the crystalline inclusions cannot always be identified by IF and pronase-digested tissue or the immunoperoxidase method may be required.<sup>41,44</sup> CSH can occur simultaneously with LCPT. If this is the case, organized cytoplasmic inclusions of needle- or oval-shaped crystals in proximal tubular cells are seen with EM.<sup>21,45</sup>

## DIAGNOSIS OF MGRS

#### When should MGRS be considered?

Clinical manifestations depend on the affected segment of the nephron. Patients present with a progressive decline in kidney function, microscopic haematuria,

proteinuria (ranging from subnephrotic to overt nephrotic syndrome), and/or proximal tubular dysfunction.<sup>21</sup> The proximal tubular dysfunction can result in FS which is characterised by normoglycaemic glycosuria, hyperphosphaturia resulting in hypophosphataemia, proteinuria, aminoaciduria, hyperuricosuria, and urinary wasting of bicarbonate. Incomplete FS has also been reported.<sup>31</sup>

Therefore, MGRS should be considered in every patient with renal manifestations combined with an M-protein, especially when classical cardiovascular risk factors or diseases, such as diabetes mellitus, hypertension, and atherosclerosis are absent or well controlled. MGRS should also be considered in patients presenting with C<sub>3</sub>GP and TMA, which are known to have a strong association with M-protein and kidney disease, for example, in elderly patients. Although MGRS is commonly seen in patients of 50 years and older<sup>14,46</sup>, it has also been reported in younger patients.<sup>9-11,14,47</sup>

Extrarenal manifestations are common in AL amyloidosis and MIDD, with the heart and liver often affected, which could serve as a clinical clue. In type 1 CG, the skin is the most affected organ.<sup>48</sup> However, these patients are difficult to recognize and diagnosis often requires extensive consultation between nephrologist and haematologist.

In the diagnosis of MGRS there are two important objectives: 1) one should try to identify the circulating M-protein and 2) one should try to establish a causal relationship between the M-protein and the observed renal abnormality. Therefore, kidney biopsy is essential and should be performed in all cases of suspected MGRS. Laboratory evaluation in patients suspected of having MGRS is summarised in table 2.

#### Monoclonal protein testing

Typically, MGRS exhibits low levels of circulating M-protein reflecting the small size of the underlying B-cell or plasma cell clone.<sup>21</sup> With detection limits of 500-2000 mg/l, serum protein electrophoresis (SPE) has insufficient sensitivity to detect low levels of M-protein, particularly free light chains (FLCs) because of their lower half-life compared to intact Ig (table 3).<sup>49,51</sup> Kyle et al. found that an M-protein cannot be detected by routine SPE in > 50% of the patients with AL amyloidosis.<sup>52</sup> Serum immunofixation electrophoresis (IFE) is approximately 10-fold more sensitive than SPE, yet urine IFE and/or serum free light chain assay (sFLC assay) are usually necessary to detect an M-protein.<sup>49</sup>

An sFLC assay utilizes antibodies directed against epitopes that are exposed in "free" LCs but hidden in intact Ig molecules. This assay provides a quantitative measurement of both  $\kappa$  and  $\lambda$  FLCs with a sensitivity of < 5 mg/l, and calculation of a  $\kappa/\lambda$  ratio can detect unbalanced LC synthesis as a surrogate marker for a monoclonal gammopathy.<sup>49,50</sup> Studies evaluating the diagnostic performance of this test have documented detection of

**Table 2.** Laboratory evaluation of suspected MGRS

Serum measurements
Creatinine
Potassium
Bicarbonate
Calcium <sup>a</sup>
Phosphate <sup>b</sup>
Glucose <sup>b</sup>
Uric acid <sup>b</sup>
M-protein diagnostics including free light chains
2. Urinalysis
Creatinine
Total protein
Albumine
Phosphate <sup>b</sup>
Glucose <sup>b</sup>
Uric acid <sup>b</sup>
Microscopic evaluation urine sediment
3. 24-hour urine collection
Creatinine
Sodium
Total protein
Albumin
Bence Jones protein
Total volume
<b>Note:</b> The abovementioned parameters need to be performed to assess kidney function, acid-base status, and possible metabolic complications in the context of chronic kidney disease. <sup>a</sup> Presence of hypercalcaemia should prompt further investigation of possible multiple myeloma. <sup>b</sup> To detect proximal tubular dysfunction/Fanconi syndrome. MGRS = monoclonal gammopathy of renal significance.

abnormal  $\kappa/\lambda$  ratios in 100% of patients with LC MM<sup>49,52</sup>, in 76-98% of patients with AL amyloidosis<sup>52-55</sup>, and in 92-100% of patients with LCDD.<sup>56-58</sup> For more than 10 years, sFLC quantification has been performed by an immunonephelometric assay based on polyclonal antibodies (Freelite®, The Binding Site, Birmingham, UK). In recent years, novel assays based on monoclonal antibodies have entered clinical practice.<sup>51,59,60</sup> The Freelite FLC assay and one of the novel assays (N Latex FLC assay®, Siemens Healthcare Diagnostic Products GmbH, Marburg, Germany) seem to have similar diagnostic performance, though current data indicate that they are not interchangeable, especially in monitoring response to therapy.<sup>59, 61,62</sup>

Reference intervals for the Freelite serum FLC were defined by Katzmann et al. (normal range  $\kappa$ : 3.3-19.4 mg/l;  $\lambda$ : 5.7-26.3 mg/l;  $\kappa/\lambda$  ratio: 0.26-1.65).<sup>56</sup> Since FLCs are filtered by the glomerulus and metabolised in the proximal tubules, caution is required when interpreting this assay in the context of renal impairment. As glomerular filtration rate (GFR) significantly declines, the removal of FLCs by reticuloendothelial pinocytosis becomes more important resulting in a prolonged FLC half-life and polyclonal increase in both  $\kappa$  and  $\lambda$  FLCs.<sup>63</sup> In patients with normal GFR, the increased physiological production of polyclonal  $\kappa$  LCs (molecular weight (MW) 22.5 kDa) is masked by the more rapid clearance of this monomeric LC compared to larger dimeric  $\lambda$  LCs (MW 45-50 kDa).<sup>64</sup> As the differential ability to clear  $\kappa$  and  $\lambda$  LCs by the kidney is lost, the  $\kappa/\lambda$  ratio can slightly increase and, for this reason, adaptation of the normal range to 0.37-3.17 increases the reliability of the Freelite FLC assay in patients with renal impairment.<sup>65</sup> In the BeNeLux region, most clinical laboratories make use of the Freelite FLC assay, which has an adjusted FLC ratio reference range of 0.37-3.17. In terms of M-protein diagnostics, a patient with MGRS and renal impairment would reach complete response (CR) in case of negative IFE in serum and urine. Provided that CR criteria are met and clonal cells in bone marrow are absent, the patient reaches serum CR when the adjusted FLC ratio is normal.

On the contrary, when using the N Latex FLC assay, there is no need for a separate renal reference range since the  $\kappa/\lambda$  ratio in patients with kidney disease does not differ from the normal values in healthy controls.<sup>66</sup> Adaptation of the  $\kappa/\lambda$  ratio in the first assay and the unadapted  $\kappa/\lambda$  ratio in the second assay, illustrate the heterogeneity that exists in FLC measurement. Therefore, follow-up of FLC measurements should be performed using the same assay and the same platform.<sup>62</sup>

International guidelines recommend using an sFLC assay along with SPE and IF as an initial screening panel for monoclonal gammopathies, because of the incremental sensitivity and potential limitations of urinary assessment in this setting.<sup>67,68</sup> Since FLCs only appear in the urine when the proximal tubular reabsorption capacity is overwhelmed, low-level serum FLCs will not be detected by urine tests.<sup>49</sup> Furthermore, urine analysis can be unreliable due to errors in carrying out a correct 24-hour urine collection, or due to inaccurate interpretation of EP results in concentrated urine samples or nephrotic-range proteinuria.<sup>49</sup> On the other hand, several studies have proven the necessity to perform both serum and urine IF for optimal sensitivity in AL amyloidosis and LCDD.<sup>54</sup> In addition, since 24-hour urine collection is necessary to calculate the GFR more precisely and measure the amount of proteinuria, urine IF and EP can be performed on this sample.

**Table 3.** Overview of methods for monoclonal FLC detection

	Serum protein EP	Urine protein EP	Serum IF	Urine IF	sFLC assay
<b>Quantitative or qualitative</b>	Semi-quantitative	Semi-quantitative	Qualitative	Qualitative	Quantitative: independent measurement of $\kappa$ and $\lambda$ FLC + calculation of a $\kappa/\lambda$ ratio
<b>FLC detection limit (sensitivity)</b>	500-2000 mg/l	20-50 mg/l	150-500 mg/l	20-50 mg/l	$\kappa$ : 1.5 mg/l $\lambda$ : 3 mg/l
<b>Advantages</b>	Inexpensive; Easy to perform.	Inexpensive; Easy to perform.	10x more sensitive than serum PE.	-	Valuable as prognostic factor; Valuable for monitoring response to therapy.
<b>Disadvantages</b>	Low sensitivity for detection of low levels M-proteins, FLCs in particular.	FLCs in urine only when tubular reabsorptive capacity is overwhelmed; 24-hour urine collection required; Identification of monoclonal FLCs is a subjective interpretation of EP results; Difficult interpretation of EP results in concentrated urine or proteinuria.	-	FLCs in urine only when tubular reabsorptive capacity is overwhelmed 24-hour urine collection required.	More expensive; FLC assays are not accurate and measurements results are not equivalent between different methods; Assay reactivity of monoclonal and polyclonal $\kappa$ and $\lambda$ FLC in specific disease groups needs improvement.

EP = electrophoresis; IF = immunofixation; FLC = free light chain; sFLC = serum free light chain

### Kidney biopsy

A kidney biopsy is crucial for the diagnosis of MGRS to determine whether the M-protein is an innocent bystander or the cause of the renal disease. Detailed IF, immunohistochemistry (IHC), and EM studies to identify deposit composition and ultrastructural organisation pattern should be applied. In this respect, it is important to emphasize that EM should be part of the standard work up, since FGN, ITG, type 1 CG and crystalline LCPT can only be diagnosed with EM. An exception can be made for patients with suspected AL amyloidosis, in whom other tissue specimens (e.g., abdominal fat) can be sufficient for diagnosis if clinical criteria for renal involvement are met.<sup>69</sup>

In selected cases, more sophisticated techniques such as immunogold EM or proteomics via laser microdissection and by mass spectrometry (LMD/MS) are required to characterise the component proteins of dense deposits.<sup>70,71</sup> LMD/MS is not only considered the gold standard for accurate typing of amyloidosis, it has also proven to be extremely useful for correct diagnosis and understanding of other MGRS.<sup>72,73</sup> The use of these advanced techniques may require sending the biopsy sample to a specialised centre and is therefore usually reserved for equivocal results or difficult cases.

### Bone marrow

In order to identify the underlying B-cell or plasma cell clone, which is essential to determine treatment strategy, a detailed haematologic evaluation should be performed in all cases.<sup>21,37</sup> Overt MM or WM should be excluded, and BM aspirate and biopsy generally show only a small increase in plasma cells or B-cells (by definition < 10%) without morphologic abnormalities.<sup>21,37,74</sup> A Congo red stain performed on the BM biopsy could demonstrate amyloidosis which is present in approximately 60% of AL amyloidosis cases.<sup>75</sup> IHC and/or flow cytometry is mandatory to establish clonality and to make the connection between the circulating M-protein and the presence of this M-protein in the kidney.<sup>21,37</sup>

### TREATMENT OF MGRS

The aim of the treatment in MGRS is to preserve or improve organ function by targeting the B-cell or plasma cell clone that is responsible for production of M-protein and organ damage. Achieving complete haematologic response will lead to better organ response and thereby prevent progression of organ damage.<sup>37</sup> Current evidence strongly supports the strategy of clone-directed therapy.



Except for amyloidosis, very few data regarding treatment options exist for the other MGRS (sub)types and there are currently no evidence-based recommendations. Based on literature concerning MM and AL amyloidosis, it can be assumed that when treating MGRS, the best results are achieved by targeting the underlying MGUS clone and aiming for a deep and prolonged haematologic response. Treatment depends on the isotype of the underlying clone in the BM (IgG, IgA, or LCs only versus IgM clone), the renal metabolism and potential renal toxicity of the therapy, and presence of neuropathy in the patient.<sup>37</sup>

#### Plasma cell dyscrasia with IgG, IgA, or LCs only

In case of an IgG, IgA, or LC-only-producing plasma cell clone (non-IgM MGUS), therapy directed at eradication of the plasma cell clone with anti-myeloma agents should be considered to preserve kidney function. The most important drug in the treatment of MGRS associated with a plasma cell clone is the proteasome inhibitor bortezomib. Bortezomib has a nonrenal metabolism and is usually given in combination with dexamethasone. Other proteasome inhibitors are currently available, but bortezomib has the most robust data in the treatment of MGRS. In MM patients with renal impairment, bortezomib-containing regimens have demonstrated rapid reduction of tumour load and improved kidney function. In addition, in a study with 27 dialysis patients with MM, bortezomib was used as induction therapy and showed a higher overall response rate compared to induction therapy with conventional chemotherapy, and reduced the transplant-related mortality.<sup>76,77</sup> Bortezomib has been demonstrated to be a highly effective drug in AL amyloidosis and seems to be the most effective agent in MIDD as high rates of CR/very good partial response (VGPR) have been described after treatment with bortezomib-based regimens and melphalan-conditioned autologous stem cell transplantation (ASCT).<sup>12,77-79</sup> Furthermore, integration of bortezomib both before and after ASCT overcomes the negative impact of renal failure in AL amyloidosis.<sup>80-81</sup>

For an optimal treatment strategy, it is important to determine whether patients are eligible for ASCT since this therapy can deepen and prolong the duration of remission. Similar to MM, ASCT is preceded by high-dose therapy with melphalan. The melphalan dose is normally reduced in cases of GFR of < 40 ml/min. Induction therapy prior to ASCT can be omitted in cases of a small clone, but proves to be beneficial for patients with a poor performance status due to MGRS. The treatment-related mortality of ASCT is < 1%.

Determination of eligibility for ASCT differs across countries and institutions. However, the decision to undergo ASCT should be made on a case-by-case basis by reviewing the risk-benefit assessment, and the needs and wishes of the patient. In general, patients younger

than 70 years of age, with sufficient cardiac function (ejection fraction > 45%), sufficient pulmonary function, a systolic blood pressure of > 90 mmHg, World Health Organisation performance score < 2, and New York Heart Association scores I-II, are eligible for ASCT. Interestingly, kidney disease is not a contraindication to ASCT, although it is crucial that the renal function is stable. Kidney disease has no adverse effects on the quality of stem cell collection or their engraftment and ASCT is possible in dialysis patients.<sup>82-88</sup> However, the procedure is associated with increased risk of transplant-related mortality for patients with kidney disease compared to those with normal kidney function.<sup>86</sup> Patients who do not meet the abovementioned criteria and who also have an active infection are not eligible for ASCT. Overall survival is strongly dependent on the haematologic response according to most AL amyloidosis data.<sup>86,87</sup> Since MGRS is more similar to MGUS with regard to few plasma cells in the bone marrow, it would be fitting to treat patients who are ineligible for ASCT, with six to eight courses of bortezomib in combination with dexamethasone and cyclophosphamide, or bortezomib plus melphalan-prednisone. Treatment with immunomodulatory drugs (IMiD) such as thalidomide and lenalidomide can be used as an alternative, and in a relapse setting, pomalidomide can be used. Unlike lenalidomide, thalidomide and pomalidomide are not excreted by the kidneys and dose modifications are therefore not needed.<sup>89,90</sup> However, lenalidomide has been shown to be more effective than thalidomide and is thus the preferred alternative to bortezomib.

#### B-cell clone with IgM M-protein

Since IgM MGUS is rare, there is little evidence supporting the choice of treatment in MGRS-related to IgM M-protein. When the underlying BM clone is an IgM M-protein-producing and CD20-expressing B-cell or lymphoplasmacytic clone, rituximab-based therapy is the first choice of treatment. Rituximab can be combined with dexamethasone and cyclophosphamide or bendamustine in MGRS associated with IgM-MGUS. Rituximab can be safely administered without dose modification in patients with decreased kidney function.<sup>91</sup> Approximately 60% of cyclophosphamide is eliminated through the kidneys. Studies describe an increase of cyclophosphamide exposure in patients with kidney disease, however, dose adjustments in these patients remain variable in the literature.<sup>90,92</sup> Bendamustine does not appear to alter the pharmacokinetics in moderate renal impairment but limited data suggest toxicity increases in patients with GFR < 40 ml/min.<sup>93</sup> The benefit of ASCT in these patients has not been demonstrated but since a deep haematologic response is most likely beneficial, this option should also be considered.

The optimal treatment strategy of an IgM-related MGRS disorder should be constructed with the consultation of experts on MGRS, for example, the multidisciplinary Benelux MGRS Working Group, with experience in the use of these drugs.

### Supportive care

In all patients, hypertension and/or proteinuria should be treated, preferably with renin-angiotensin system (RAS) inhibitors combined with salt restriction. Diuretics can have an extra antihypertensive and/or antiproteinuric effect. In case of AL amyloidosis, treatment with RAS blockade should be prescribed with caution as these patients have a tendency towards hypotension. In FS, prevention of osteomalacia with bicarbonate, phosphate, and vitamin D supplementation should be considered.<sup>22</sup>

### Response to therapy

In MGRS, assessment of the haematologic response to treatment is crucial because the renal response is dependent on the haematologic response. For example, renal response rate in AL amyloidosis was significantly higher in patients with > 90% suppression of the nephrotoxic M-protein.<sup>87</sup> In MIDD, achieving haematologic complete response showed similar benefits for the kidney.<sup>79</sup> In AL amyloidosis, measurement of the sFLC is an essential tool for the assessment of a haematologic response. The response criteria used in AL amyloidosis are CR, VGPR, partial response (PR), and no response (NR)<sup>94</sup>, and it seems logical to use these same response criteria in the other MGRS disorders. The use of sFLC assay for response has been suggested for all MGRS involving LCs only.<sup>22</sup> In cases of an undetectable or difficult to measure M-protein, the haematologic response can be assessed with repeated bone marrow examinations using sensitive multicolor flow cytometry. Sometimes, the GFR and proteinuria can be the only parameters used to assess disease activity.<sup>94</sup> It is important to note that the renal response is usually delayed. In one study, a minimum duration of 12 months of haematologic response was needed until onset of renal response was seen in patients with AL amyloidosis.<sup>95</sup>

### CONCLUSION

In summary, MGRS consists of a variety of kidney diseases that are caused by the production of an M-protein resulting in kidney deposits and/or autoimmune activity. Histopathologic identification and classification are crucial for determining the optimal treatment for MGRS. For the diagnosis of MGRS, it is important to identify the circulating M-protein and to establish a causal relationship between the M-protein and the renal damage. A kidney

biopsy with detailed examination by LM, IHC, IF, and EM is needed in the diagnosis and aids in characterising the MGRS lesion.

Clone-directed therapy is currently the most effective treatment strategy. Choice of therapy will depend on type of clone, eligibility for ASCT, side effects, and scarce literature support. Preferably, patients should be managed by a multidisciplinary team consisting of nephrologists, haematologists, and nephropathologists, with expertise in MGRS for optimal care. In cases of suspected or proven MGRS, the Benelux MGRS Working Group can be consulted during diagnosis and treatment of possible MGRS patients.

### DISCLOSURES

All authors declare no conflicts of interest. No funding or financial support was received.

### REFERENCES

1. Rajkumar SV, Dimopoulos MA, Palumbo A. International Myeloma Working Group updated criteria for the diagnosis of multiple myeloma. *Lancet Oncology* 2014 Nov;15:548.
2. Kyle RA, Therneau TM, Rajkumar SV, et al. Prevalence of monoclonal gammopathy of undetermined significance. *N Engl J Med* 2006 Mar 30;354(13):1362-1369.
3. van de Donk NW, Palumbo A, Johnsen HE, et al. The clinical relevance and management of monoclonal gammopathy of undetermined significance and related disorders: recommendations from the European Myeloma Network. *Haematologica* 2014 Jun;99(6):984-996.
4. Feraud JP, Bridoux F, Dispenzieri A, et al. Monoclonal gammopathy of clinical significance: a novel concept with therapeutic implications. *Blood* 2018 Oct 4;132(14):1478-1485.
5. Kyle RA, Durie BG, Rajkumar SV, et al. Monoclonal gammopathy of undetermined significance (MGUS) and smoldering (asymptomatic) multiple myeloma: IMWG consensus perspectives risk factors for progression and guidelines for monitoring and management. *Leukemia* 2010 Jun;24(6):1121-1127.
6. Angioi A, Amer H, Fervenza FC, Sethi S. Recurrent Light Chain Proximal Tubulopathy in a Kidney Allograft. *Am J Kidney Dis* 2016 Sep;68(3):483-487.
7. Roth RM, Benson D, Hebert LA, et al. Progressive renal light chain amyloidosis with the absence of detectable free monoclonal light chains after an autologous hematopoietic stem cell transplant for amyloid light chain amyloidosis. *Arch Pathol Lab Med* 2013 Sep;137(9):1304-1308.
8. Miyazaki D, Yazaki M, Gono T, et al. AL amyloidosis associated with an immunoglobulin heavy chain variable region (VH1) fragment: a case report. *Amyloid* 2008 Jun;15(2):125-128.
9. Mallett A, Tang W, Hart G, et al. End-Stage Kidney Disease Due to Fibrillary Glomerulonephritis and Immunotactoid Glomerulopathy - Outcomes in 66 Consecutive ANZDATA Registry Cases. *Am J Nephrol* 2015;42(3):177-184.
10. Sathyan S, Khan FN, Ranga KV. A case of recurrent immunotactoid glomerulopathy in an allograft treated with rituximab. *Transplant Proc* 2009 Nov;41(9):3953-3955.
11. Neel A, Perrin F, Decaux O, et al. Long-term outcome of monoclonal (type 1) cryoglobulinemia. *Am J Hematol* 2014 Feb;89(2):156-161.
12. Sayed RH, Wechalekar AD, Gilbertson JA, et al. Natural history and outcome of light chain deposition disease. *Blood* 2015 Dec 24;126(26):2805-2810.

13. Nambirajan A, Bhowmik D, Singh G, Agarwal SK, Dinda AK. Monoclonal gammopathy of renal significance with light chain deposition disease diagnosed postrenal transplant: a diagnostic and therapeutic challenge. *Transpl Int* 2015 Mar;28(3):375-379.
14. Nasr SH, Sethi S, Cornell LD, et al. Proliferative glomerulonephritis with monoclonal IgG deposits recurs in the allograft. *Clin J Am Soc Nephrol* 2011 Jan;6(1):122-132.
15. Lloyd IE, Gallan A, Huston HK, et al. C3 glomerulopathy in adults: a distinct patient subset showing frequent association with monoclonal gammopathy and poor renal outcome. *Clin Kidney J* 2016 Dec;9(6):794-799.
16. Shaik M, Al-Janadi A. Long Term Survival of Monoclonal Gammopathy of Renal Significance (MGRS): An Analysis of Nhanes III. *Blood* 2014;124(21):4849.
17. Steiner N, Gobel G, Suchecki P, Prokop W, Neuwirt H, Gunsilius E. Monoclonal gammopathy of renal significance (MGRS) increases the risk for progression to multiple myeloma: an observational study of 2935 MGUS patients. *Oncotarget* 2017 Dec 18;9(2):2344-2356.
18. Nefrodata - Nefrovisie [Internet]. Nefrovisie. 2018 [cited 25 November 2018]. Available at: [://www.nefrovisie.nl/nefrodata/](http://www.nefrovisie.nl/nefrodata/).
19. Kasagi T, Nobata H, Suzuki K, et al. Light Chain Deposition Disease Diagnosed with Laser Micro-dissection, Liquid Chromatography, and Tandem Mass Spectrometry of Nodular Glomerular Lesions. *Intern Med* 2017;56(1):61-66.
20. Nasr SH, Valeri AM, Cornell LD, et al. Renal monoclonal immunoglobulin deposition disease: a report of 64 patients from a single institution. *Clin J Am Soc Nephrol* 2012 Feb;7(2):231-239.
21. Bridoux F, Leung N, Hutchison CA, et al. Diagnosis of monoclonal gammopathy of renal significance. *Kidney Int* 2015 Apr;87(4):698-711.
22. Fermand JP, Bridoux F, Kyle RA, et al. How I treat monoclonal gammopathy of renal significance (MGRS). *Blood* 2013 Nov 21;122(22):3583-3590.
23. Kapoulas S, Raptis V, Papaioannou M. New aspects on the pathogenesis of renal disorders related to monoclonal gammopathies. *Nephrol Ther* 2015 Jun;11(3):135-143.
24. Doshi M, Lahoti A, Danesh FR, Batuman V, Sanders PW. American Society of Nephrology Onco-Nephrology Forum. Paraprotein-Related Kidney Disease: Kidney Injury from Paraproteins-What Determines the Site of Injury? *Clin J Am Soc Nephrol* 2016 Dec 7;11(12):2288-2294.
25. Solomon A, Weiss DT, Kattine AA. Nephrotoxic potential of Bence Jones proteins. *N Engl J Med* 1991 Jun 27;324(26):1845-1851.
26. Dember LM. Amyloidosis-associated kidney disease. *J Am Soc Nephrol* 2006 Dec;17(12):3458-3471.
27. Wechalekar AD, Gillmore JD, Hawkins PN. Systemic amyloidosis. *Lancet* 2016 Jun 25;387(10038):2641-2654.
28. Komatsuda A, Ohtani H, Sawada K, Joh K, Wakui H. Proliferative glomerulonephritis with discrete deposition of monoclonal immunoglobulin gamma1 CH 2 heavy chain and kappa light chain: a new variant of monoclonal immunoglobulin deposition disease. *Pathol Int* 2013 Jan;63(1):63-67.
29. Rane S, Rana S, Mudrabettu C, Jha V, Joshi K. Heavy chain deposition disease: a morphological, immunofluorescence and ultrastructural assessment. *Clin Kidney J* 2012 Oct;5(5):383-389.
30. Vignon M, Cohen C, Faguer S, et al. The clinicopathologic characteristics of kidney diseases related to monoclonal IgA deposits. *Kidney Int* 2017 Mar;91(3):720-728.
31. Sethi S, Fervenza FC, Rajkumar SV. Spectrum of manifestations of monoclonal gammopathy-associated renal lesions. *Curr Opin Nephrol Hypertens* 2016 Mar;25(2):127-137.
32. Hussain SM, Sureshkumar KK. Proliferative glomerulonephritis with monoclonal IgG deposits; an unusual cause of de novo disease in kidney allograft. *J Nephrol Pathol* 2017 Jul;6(3):220-224.
33. Zand L, Kattah A, Fervenza FC, et al. C3 glomerulonephritis associated with monoclonal gammopathy: a case series. *Am J Kidney Dis* 2013 Sep;62(3):506-514.
34. Motwani SS, Herlitz L, Monga D, Jhaveri KD, Lam AQ. American Society of Nephrology Onco-Nephrology Forum. Paraprotein-Related Kidney Disease: Glomerular Diseases Associated with Paraproteinemias. *Clin J Am Soc Nephrol* 2016 Dec 7;11(12):2260-2272.
35. Alpers CE, Kowalewska J. Fibrillary glomerulonephritis and immunotactoid glomerulopathy. *J Am Soc Nephrol* 2008 Jan;19(1):34-37.
36. Hiramatsu R, Hoshino J, Suwabe T, et al. Membranoproliferative glomerulonephritis and circulating cryoglobulins. *Clin Exp Nephrol* 2014 Feb;18(1):88-94.
37. Leung N, Bridoux F, Hutchison CA, et al. Monoclonal gammopathy of renal significance: when MGUS is no longer undetermined or insignificant. *Blood* 2012 Nov 22;120(22):4292-4295.
38. Rosenstock JL, Markowitz GS, Valeri AM, Sacchi G, Appel GB, D'Agati VD. Fibrillary and immunotactoid glomerulonephritis: Distinct entities with different clinical and pathologic features. *Kidney Int* 2003 Apr;63(4):1450-1461.
39. Vos JM, Gustine J, Renke HG, et al. Renal disease related to Waldenström macroglobulinaemia: incidence, pathology and clinical outcomes. *Br J Haematol* 2016 Nov;175(4):623-630.
40. Ravindran A, Go RS, Fervenza FC, Sethi S. Thrombotic microangiopathy associated with monoclonal gammopathy. *Kidney Int* 2017 Mar;91(3):691-698.
41. Nasr SH, Galgano SJ, Markowitz GS, Stokes MB, D'Agati VD. Immunofluorescence on pronase-digested paraffin sections: a valuable salvage technique for renal biopsies. *Kidney Int* 2006 Dec;70(12):2148-2151.
42. Larsen CP, Bell JM, Harris AA, Messias NC, Wang YH, Walker PD. The morphologic spectrum and clinical significance of light chain proximal tubulopathy with and without crystal formation. *Mod Pathol* 2011 Nov;24(11):1462-1469.
43. Stokes MB, Valeri AM, Herlitz L, et al. Light Chain Proximal Tubulopathy: Clinical and Pathologic Characteristics in the Modern Treatment Era. *J Am Soc Nephrol* 2016 May;27(5):1555-1565.
44. Marzilli LA, Golden TR, Cotter RJ, Woods AS. Peptide sequence information derived by pronase digestion and ammonium sulfate in-source decay matrix-assisted laser desorption/ionization time-of-flight mass spectrometry. *J Am Soc Mass Spectrom* 2000 Nov;11(11):1000-1008.
45. El Hamel C, Thierry A, Trouillas P, et al. Crystal-storing histiocytosis with renal Fanconi syndrome: pathological and molecular characteristics compared with classical myeloma-associated Fanconi syndrome. *Nephrol Dial Transplant* 2010 Sep;25(9):2982-2990.
46. Nasr SH, Satoskar A, Markowitz GS, et al. Proliferative glomerulonephritis with monoclonal IgG deposits. *J Am Soc Nephrol* 2009 Sep;20(9):2055-2064.
47. Smit PM, Abrahams AC, Schutgens RGE, Notermans NC, Minnema MC. Unexpected symptoms of monoclonal gammopathy. *Ned Tijdschr Geneesk* 2017;161:D1741.
48. Mughtar E, Magen H, Gertz MA. How I treat cryoglobulinemia. *Blood* 2017 Jan 19;129(3):289-298.
49. Jenner E. Serum free light chains in clinical laboratory diagnostics. *Clin Chim Acta* 2014 Jan 1;427:15-20.
50. Nowrousian MR, Brandhorst D, Sammet C, et al. Serum free light chain analysis and urine immunofixation electrophoresis in patients with multiple myeloma. *Clin Cancer Res* 2005 Dec 15;11(24 Pt 1):8706-8714.
51. Campbell JP, Heaney JL, Shemar M, et al. Development of a rapid and quantitative lateral flow assay for the simultaneous measurement of serum kappa and lambda immunoglobulin free light chains (FLC): inception of a new near-patient FLC screening tool. *Clin Chem Lab Med* 2017 Mar 1;55(3):424-434.
52. Kyle RA, Gertz MA. Primary systemic amyloidosis: clinical and laboratory features in 474 cases. *Semin Hematol* 1995 Jan;32(1):45-59.
53. Bradwell AR, Carr-Smith HD, Mead GP, Harvey TC, Drayson MT. Serum test for assessment of patients with Bence Jones myeloma. *Lancet* 2003 Feb 8;361(9356):489-491.
54. Palladini G, Russo P, Bosoni T, et al. Identification of amyloidogenic light chains requires the combination of serum-free light chain assay with immunofixation of serum and urine. *Clin Chem* 2009 Mar;55(3):499-504.
55. Lachmann HJ, Gallimore R, Gillmore JD, et al. Outcome in systemic AL amyloidosis in relation to changes in concentration of circulating free immunoglobulin light chains following chemotherapy. *Br J Haematol* 2003 Jul;122(1):78-84.
56. Katzmam JA, Abraham RS, Dispenzieri A, Lust JA, Kyle RA. Diagnostic performance of quantitative kappa and lambda free light chain assays in clinical practice. *Clin Chem* 2005 May;51(5):878-881.

57. Katzmann JA, Clark RJ, Abraham RS, et al. Serum reference intervals and diagnostic ranges for free kappa and free lambda immunoglobulin light chains: relative sensitivity for detection of monoclonal light chains. *Clin Chem* 2002 Sep;48(9):1437-1444.
58. Katzmann JA, Kyle RA, Benson J, et al. Screening panels for detection of monoclonal gammopathies. *Clin Chem* 2009 Aug;55(8):1517-1522.
59. te Velthuis H, Knop I, Stam P, et al. N Latex FLC - new monoclonal high-performance assays for the determination of free light chain kappa and lambda. *Clin Chem Lab Med* 2011 Aug;49(8):1323-1332.
60. Lutteri L, Jacobs JFM. Reference ranges of the Sebia free light chain ratio in patients with chronic kidney disease. *Clin Chem Lab Med* 2018 Aug 28;56(9):e232-e234.
61. Milani P, Palladini G, Merlini G. Serum-free light chain analysis in diagnosis and management of multiple myeloma and related conditions. *Scand J Clin Lab Invest Suppl* 2016;245:S113-8.
62. Jacobs JF, Tate JR, Merlini G. Is accuracy of serum free light chain measurement achievable? *Clin Chem Lab Med* 2016 Jun 1;54(6):1021-1030.
63. Tosi P, Tomassetti S, Merli A, Polli V. Serum free light chain assay for the detection and monitoring of multiple myeloma and related conditions. *Ther Adv Hematol* 2013 Feb;4(1):37-41.
64. Wochner RD, Strober W, Waldmann TA. The role of the kidney in the catabolism of Bence Jones proteins and immunoglobulin fragments. *J Exp Med* 1967 Aug 1;126(2):207-221.
65. Hutchison CA, Plant T, Drayson M, et al. Serum free light chain measurement aids the diagnosis of myeloma in patients with severe renal failure. *BMC Nephrol* 2008 Sep 22;9:11-2369-9-11.
66. Jacobs JF, Hoedemakers RM, Teunissen E, Te Velthuis H. N Latex FLC serum free light chain assays in patients with renal impairment. *Clin Chem Lab Med* 2014 Jun;52(6):853-859.
67. Anderson KC, Alsina M, Bensinger W, et al. NCCN clinical practice guidelines in oncology: multiple myeloma. *J Natl Compr Canc Netw* 2009 Oct;7(9):908-942.
68. Dispenzieri A, Kyle R, Merlini G, et al. International Myeloma Working Group guidelines for serum-free light chain analysis in multiple myeloma and related disorders. *Leukemia* 2009 Feb;23(2):215-224.
69. Gillmore JD, Hawkins PN. Pathophysiology and treatment of systemic amyloidosis. *Nat Rev Nephrol* 2013 Oct;9(10):574-586.
70. Herrera GA, Turbat-Herrera EA. Ultrastructural immunolabeling in the diagnosis of monoclonal light- and heavy chain-related renal diseases. *Ultrastruct Pathol* 2010 May;34(3):161-173.
71. Sethi S, Theis JD, Leung N, et al. Mass spectrometry-based proteomic diagnosis of renal immunoglobulin heavy chain amyloidosis. *Clin J Am Soc Nephrol* 2010 Dec;5(12):2180-2187.
72. Vrana JA, Gamez JD, Madden BJ, Theis JD, Bergen HR 3<sup>rd</sup>, Dogan A. Classification of amyloidosis by laser microdissection and mass spectrometry-based proteomic analysis in clinical biopsy specimens. *Blood* 2009 Dec 3;114(24):4957-4959.
73. Sedor JR. Tissue proteomics: a new investigative tool for renal biopsy analysis. *Kidney Int* 2009 May;75(9):876-879.
74. Guidelines Working Group of UK Myeloma Forum, British Committee for Standards in Haematology, British Society for Haematology. Guidelines on the diagnosis and management of AL amyloidosis. *Br J Haematol* 2004 Jun;125(6):681-700.
75. Dimopoulos MA, Sonneveld P, Leung N, et al. International Myeloma Working Group Recommendations for the Diagnosis and Management of Myeloma-Related Renal Impairment. *J Clin Oncol* 2016 May 1;34(13):1544-1557.
76. Breitzkreutz I, Heiss C, Perne A, et al. Bortezomib improves outcome after SCT in multiple myeloma patients with end-stage renal failure. *Bone Marrow Transplant* 2014 Nov;49(11):1371-1375.
77. Scheid C, Sonneveld P, Schmidt-Wolf IG, et al. Bortezomib before and after autologous stem cell transplantation overcomes the negative prognostic impact of renal impairment in newly diagnosed multiple myeloma: a subgroup analysis from the HOVON-65/GMMG-HD4 trial. *Haematologica* 2014 Jan;99(1):148-154.
78. Cohen C, Royer B, Javaugue V, et al. Bortezomib produces high hematological response rates with prolonged renal survival in monoclonal immunoglobulin deposition disease. *Kidney Int* 2015 Nov;88(5):1135-1143.
79. Hassoun H, Flombaum C, D'Agati VD, et al. High-dose melphalan and auto-SCT in patients with monoclonal Ig deposition disease. *Bone Marrow Transplant* 2008 Sep;42(6):405-412.
80. Huang X, Wang Q, Chen W, et al. Induction therapy with bortezomib and dexamethasone followed by autologous stem cell transplantation versus autologous stem cell transplantation alone in the treatment of renal AL amyloidosis: a randomized controlled trial. *BMC Med* 2014 Jan 6;12:2-7015-12-2.
81. Santhorawala V, Brauneis D, Shelton AC, et al. Induction Therapy with Bortezomib Followed by Bortezomib-High Dose Melphalan and Stem Cell Transplantation for Light Chain Amyloidosis: Results of a Prospective Clinical Trial. *Biol Blood Marrow Transplant* 2015 Aug;21(8):1445-1451.
82. Lee CK, Zangari M, Barlogie B, et al. Dialysis-dependent renal failure in patients with myeloma can be reversed by high-dose myeloablative therapy and autotransplant. *Bone Marrow Transplant* 2004 Apr;33(8):823-828.
83. Parikh GC, Amjad AI, Saliba RM, et al. Autologous hematopoietic stem cell transplantation may reverse renal failure in patients with multiple myeloma. *Biol Blood Marrow Transplant* 2009 Jul;15(7):812-816.
84. San Miguel JF, Lahuerta JJ, Garcia-Sanz R, et al. Are myeloma patients with renal failure candidates for autologous stem cell transplantation? *Hematol J* 2000;1(1):28-36.
85. Badros A, Barlogie B, Siegel E, et al. Results of autologous stem cell transplant in multiple myeloma patients with renal failure. *Br J Haematol* 2001 Sep;114(4):822-829.
86. Santhorawala V, Sun F, Quillen K, Sloan JM, Berk JL, Seldin DC. Long-term outcome of patients with AL amyloidosis treated with high-dose melphalan and stem cell transplantation: 20-year experience. *Blood* 2015 Nov 12;126(20):2345-2347.
87. Pinney JH, Lachmann HJ, Bansi L, et al. Outcome in renal AL amyloidosis after chemotherapy. *J Clin Oncol* 2011 Feb 20;29(6):674-681.
88. Yadav P, Cook M, Cockwell P. Current Trends of Renal Impairment in Multiple Myeloma. *Kidney Dis (Basel)* 2016 Mar;1(4):241-257.
89. Eriksson T, Hoglund P, Turesson I, et al. Pharmacokinetics of thalidomide in patients with impaired renal function and while on and off dialysis. *J Pharm Pharmacol* 2003 Dec;55(12):1701-1706.
90. Kintzel PE, Dorr RT. Anticancer drug renal toxicity and elimination: dosing guidelines for altered renal function. *Cancer Treat Rev* 1995 Jan;21(1):33-64.
91. Vieira CA, Agarwal A, Book BK, et al. Rituximab for reduction of anti-HLA antibodies in patients awaiting renal transplantation: 1. Safety, pharmacodynamics, and pharmacokinetics. *Transplantation* 2004 Feb 27;77(4):542-548.
92. Haubitz M, Bohnstengel F, Brunkhorst R, Schwab M, Hofmann U, Busse D. Cyclophosphamide pharmacokinetics and dose requirements in patients with renal insufficiency. *Kidney Int* 2002 Apr;61(4):1495-1501.
93. Nordstrom BL, Knopf KB, Teltsch DY, Engle R, Beygi H, Sterchele JA. The safety of bendamustine in patients with chronic lymphocytic leukemia or non-Hodgkin lymphoma and concomitant renal impairment: a retrospective electronic medical record database analysis. *Leuk Lymphoma* 2014 Jun;55(6):1266-1273.
94. Palladini G, Dispenzieri A, Gertz MA, et al. New criteria for response to treatment in immunoglobulin light chain amyloidosis based on free light chain measurement and cardiac biomarkers: impact on survival outcomes. *J Clin Oncol* 2012 Dec 20;30(36):4541-4549.
95. Leung N, Dispenzieri A, Fervenza FC, et al. Renal response after high-dose melphalan and stem cell transplantation is a favorable marker in patients with primary systemic amyloidosis. *Am J Kidney Dis* 2005 Aug;46(2):270-277.