



Contents lists available at ScienceDirect

## International Journal of Surgery Case Reports

journal homepage: [www.casereports.com](http://www.casereports.com)

## Multidisciplinary management of a patient with van der Woude syndrome: A case report



Azita Tehranchi<sup>a,b</sup>, Hossein Behnia<sup>c,d</sup>, Nasser Nadjmi<sup>e,f</sup>, Vahid Reza Yassaee<sup>g,h</sup>,  
Zeinab Ravesh<sup>g</sup>, Morteza Mina<sup>i,\*</sup>

<sup>a</sup> Preventive Research Center, Research Institute of Dental Sciences, Shahid Beheshti University of Medical Sciences, Tehran, Iran

<sup>b</sup> Orthodontic Department, Dental School, Tehran, Iran

<sup>c</sup> Dentofacial Deformities Research Center, Research Institute of Dental Sciences, Shahid Beheshti University of Medical Sciences, Tehran, Iran

<sup>d</sup> Dental School, Tehran, Iran

<sup>e</sup> University of Antwerp (UA), Belgium

<sup>f</sup> The Team for Cleft and Craniofacial Anomalies, Oral and Maxillofacial Surgery, University of Antwerp, Prinsstraat 13, 2000 Antwerp, Belgium

<sup>g</sup> Genomic Research Center, Aarabi St., Yaman Ave., Evin, Velenjak, Shahid Beheshti University of Medical Sciences, Tehran, 1966645643, Iran

<sup>h</sup> Dept. of Medical Genetic, Faculty of Medicine, Shahid Beheshti University of Medical Sciences, Tehran, 1966645643, Iran

<sup>i</sup> North Khorasan University of Medical Sciences, Bojnurd, Iran

### ARTICLE INFO

#### Article history:

Received 18 September 2016

Received in revised form

18 November 2016

Accepted 18 November 2016

Available online 6 December 2016

#### Keywords:

Van der Woude syndrome

Cleft lip

Distraction osteogenesis

Maxilla

Case report

### ABSTRACT

**INTRODUCTION:** Van der Woude syndrome (VWS) is the most frequent form of syndromic cleft lip and palate (SCLP) accounting for 2% of all patients with CLP.

**CASE PRESENTATION:** We describe the orthodontic treatment of a girl diagnosed with VWS referred by her family dentist for her cosmetic concerns.

**DISCUSSION:** Comprehensive orthodontic treatment, secondary bone graft, distraction osteogenesis (for a deficient maxilla), secondary palatoplasty and excision of lower lip pits, as well as orthodontic and prosthetic procedures may provide a satisfactory outcome. Genetic testing showed a known putative splice site mutation (c.174+1 G/A) as the prime cause of VWS in our patient and her family.

**CONCLUSION:** SCLP has significant effects on facial aesthetics and the psychosocial status. Parents should be assessed and counseled appropriately. This condition is treatable in the absence of life threatening systemic anomalies. An interdisciplinary team approach is advocated.

© 2016 The Author(s). Published by Elsevier Ltd on behalf of IJS Publishing Group Ltd. This is an open access article under the CC BY-NC-ND license (<http://creativecommons.org/licenses/by-nc-nd/4.0/>).

### 1. Introduction

Van der Woude syndrome (VWS) is the most frequent form of syndromic cleft lip and palate (SCLP) accounting for 2% of all patients with CLP [1].

A main factor causing the dominant characteristics of VWS (i.e. cleft lip with or without cleft palate, isolated cleft palate, lower lip pits, hypodontia, and epidermal and genital anomalies) is interferon regulatory factor 6 (IRF6), which is a protein encoded by the gene mutation at 1q32-q41 in the allelic disorders such as VWS and popliteal pterygium syndrome [2]. Other characteristics of this syndrome include normal intelligence, an autosomal-dominant mode of transmission and a high degree of penetrance [3]. The estimated

contribution of IRF6 in the etiology of cleft lip and palate is about 12% [4].

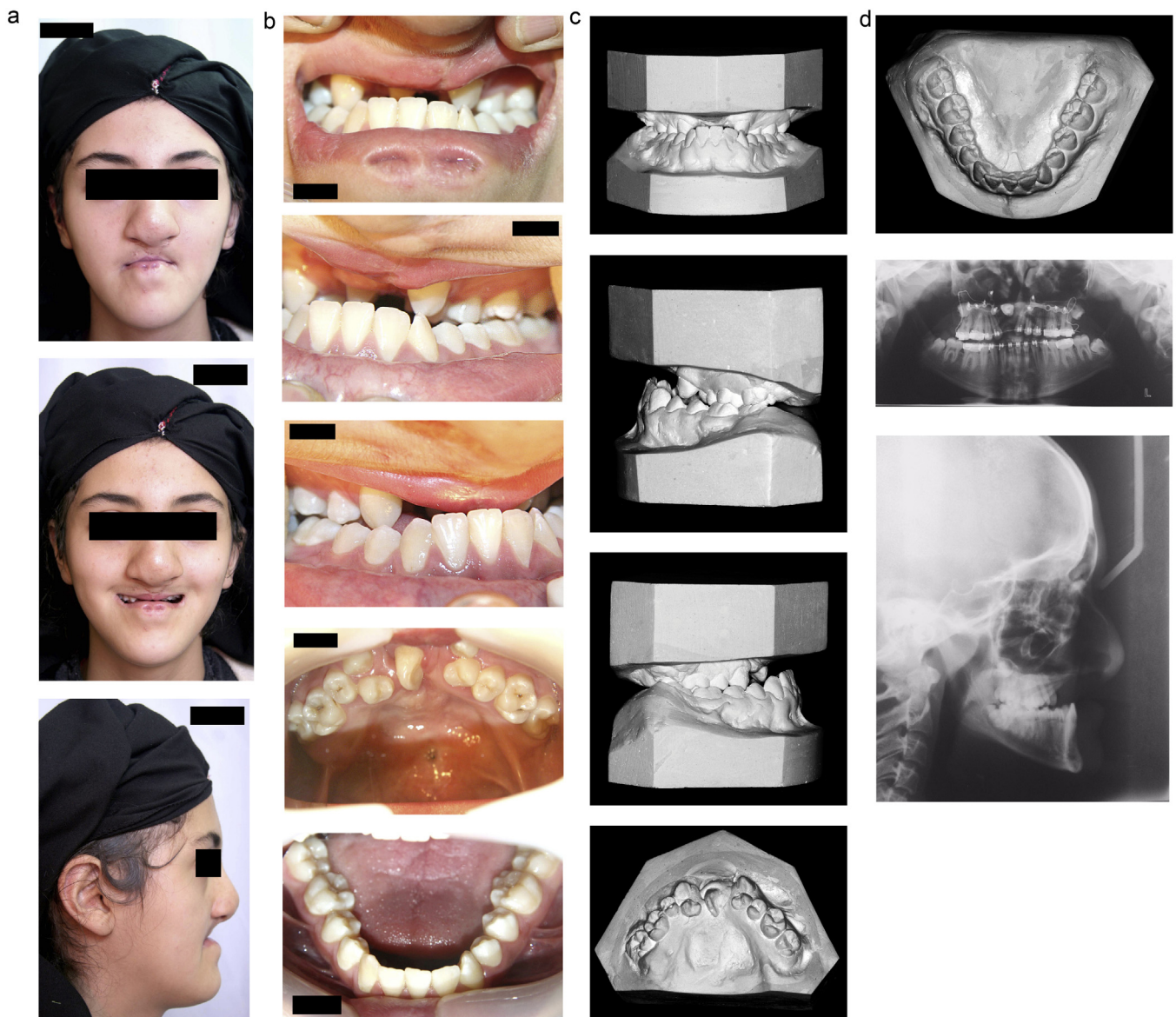The most distinctive features of patients with VWS are lower lip pits and lower lip protrusion. Lower lip pits have been reported under different terms, such as lower lip humps, cysts, sinuses, and fistula [5]. Parents often mistake these pits as depressions caused by the maxillary central incisors, even though the pits are present from birth before eruption of maxillary incisors [6].

Severe maxillary deficiency is another deformity in patients with VWS and requires a multidisciplinary approach for successful results [7].

Herein, we report a previously described heterozygous splice site mutation (c.174+1 G/A) on the IRF6 gene of a girl born to a non-consanguineous Iranian family presenting with VWS. We also aim to elucidate the multidisciplinary approach taken to treat the patient. Case reports have been a long-held tradition within the surgical literature. Reporting guidelines can improve transparency and reporting quality. This case report is in line with the SCARE criteria [8].

\* Corresponding author.

E-mail addresses: [azitatehranchi@yahoo.com](mailto:azitatehranchi@yahoo.com) (A. Tehranchi), [hosseinehnia1@gmail.com](mailto:hosseinehnia1@gmail.com) (H. Behnia), [nasser@nadjmi.com](mailto:nasser@nadjmi.com) (N. Nadjmi), [v.yassaee-grc@sbmu.ac.ir](mailto:v.yassaee-grc@sbmu.ac.ir) (V.R. Yassaee), [zeinab.ravesh@yahoo.com](mailto:zeinab.ravesh@yahoo.com) (Z. Ravesh), [mortezamina@yahoo.com](mailto:mortezamina@yahoo.com) (M. Mina).



**Fig. 1.** (a and b) Pretreatment photographs of the patient at age 14 y prior to treatment. (c) Pretreatment study casts. (d) Initial panoramic view and lateral cephalogram.

## 2. Case presentation

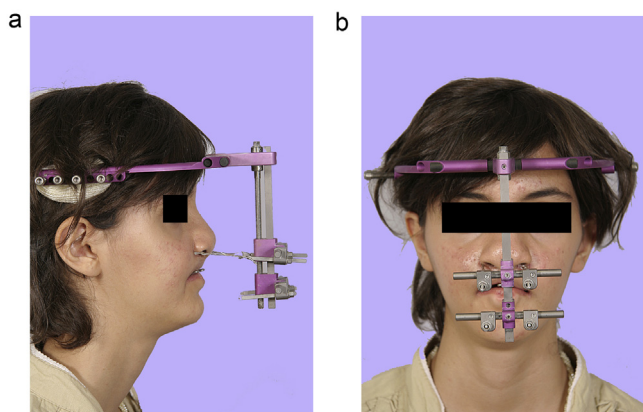
A 14-year-old Iranian girl was referred to the orthodontic department by her family dentist for her cosmetic concerns. She was a gifted and talented student. Physical examination revealed bilateral cleft lip and palate with paramedian lip pits (Fig. 1). Her mother and sister also had the same anomalies, but neither her father nor her brother had congenital deformities. The case history revealed that she had undergone primary lip repair in a charity dentofacial center 4 months after birth. The process of soft and hard palate repair was also performed simultaneously, at around 12 months of age. Poor surgical outcome was her main chief complaint.

Observation of airflow using a mirror upon nasal pinching showed abnormal velopharyngeal function. The patient had no learning disability and she could speak both Persian and English; however, she had severe hypernasality. She also had bilateral posterior crossbite and a 13 mm reverse overjet.

She had undergone phase I orthodontic treatment at age 12 with a removable appliance. The aim of this phase was to expand the maxillary arch in preparation for repair of the alveolar cleft.

Immigration to another city terminated her following procedures i.e. alveolar bone grafting and facial growth monitoring. She was referred at the age of 14 with several residual deformities namely lower lip pits, severe maxillary deficiency, ectopically erupted teeth and congenitally missing teeth. Her profile showed a protruded lower lip and mandible, and retruded midface and a drooping nasal tip were noted on the facial view (Fig. 1). A postero-anterior cephalogram and a panoramic view showed bilateral alveolar clefts, missing permanent maxillary lateral incisors and an impacted left central incisor. A lateral cephalogram showed features of patients with cleft lip and palate.

The treatment objectives of this patient were to improve her esthetic concerns as well as betterment of the occlusion. At the start of treatment, upper arch expansion was done with a hyrax appliance; then, a straight wire appliance was placed in the maxillary and mandibular arches. After that, a sagittal maxillary distraction osteogenesis was performed. After a Le Fort I type osteotomy, a rigid external device (KLS Martin, Gebruder Martin GmbH & Co., Germany) was fixed to the cranium to obtain rigid anchorage, and was connected to the maxillary bone via miniplates (bone-borne



**Fig. 2.** Distraction osteogenesis with RED appliance frontal and lateral view. (For interpretation of the references to colour in this figure legend, the reader is referred to the web version of this article.)

appliance) on both sides (Fig. 2) [7]. A latency period of 5 days following the osteotomy was awaited before distraction. Distraction was then performed at a rate of 1 mm per day. The duration of the activation phase was determined clinically and cephalometrically, based on the correction of the retruded mid-face. After the activation was completed, the distraction device was left in place for about 60 days, in order to provide rigid retention. Subsequently, a reverse pull headgear with elastic traction (200–300 grams) was used at nights for an additional 60 days.

The next stage in the functional and cosmetic rehabilitation of the patient was secondary palatoplasty and removal of the lip pits. Under general anesthesia, a modified Furlow palatoplasty (following Nadjmi [9]) was performed. Nasal mucosa was lengthened and cranialized using a Z-plasty. Subsequently, the levator muscles that were not addressed during the primary palatoplasty were identified, dissected from their abnormal position and reunited in the midline in an end-to-end fashion. On the right side, the levator muscle remained attached to the nasal layer while on the left side it remained attached to the oral layer. The Z-plasty in the oral layer was closed without tension. Finally, a *myo*-mucosal buccinator flap from the left side was used to reconstruct the hypoplastic, scarred and short palate. After this, the lip pits were addressed. A soft catheter was introduced into the sinus tracts of the lip pits until the dead end was felt. Methylene blue was then injected gently into the tracts while the catheter was removed gently. A longitudinally directed elliptical incision was made around the opening of the lip pits, and then the sinus tracts were followed caudally using sharp and blunt dissection, without perforating them. Finally they were removed and the lip defects were closed in layers. Defects created in the orbicularis muscles were closed before closing the lip mucosa. This was done to avoid inversion of the lower lip vermillion.

The lower lip repair technique produced satisfactory results. The procedure left no lower lip deformities or irregularity of the white roll. Velopharyngeal insufficiency was performed, the patient and her family were satisfied with her postoperative speech results. At the end of treatment, the patient received prosthetics for the missing maxillary central incisor, and the impacted tooth was left inside the bone. Table 2 shows the sequence and order of events in the patient's history. Finally, a functional and stable occlusion was achieved (Fig. 3).

An improved facial profile was obtained after maxillary distraction osteogenesis. Table 1 shows the pre- and post-treatment cephalometric measurements. Traced lateral cephalograms show notable increments in angular as well as linear measurements (Fig. 4, Table 1).

**Table 1**  
Cephalometric measurements before and after treatment (°).

Angle	Pretreatment	Post treatment
SNA	65	76
SNB	78	77
ANB	-13	-1
U-1 to SN plane	105	106
L-1 to mandibular plane	70	76
Mandibular plane to SN	30	33
Nasolabial	170	153

**Table 2**  
The sequence and order of events in the patient's history.

Procedures	Age
Lip Repair	4 month
Palate Repair (Hard/Soft)	12 months
Orthodontic Treatment (Phase I)	12 years
Orthodontic Treatment (Phase II)	14 years
Distraction Osteogenesis (Maxilla)	15 years
Palatoplasty	16 years
Lip Repair (Lip Pits)	16 years

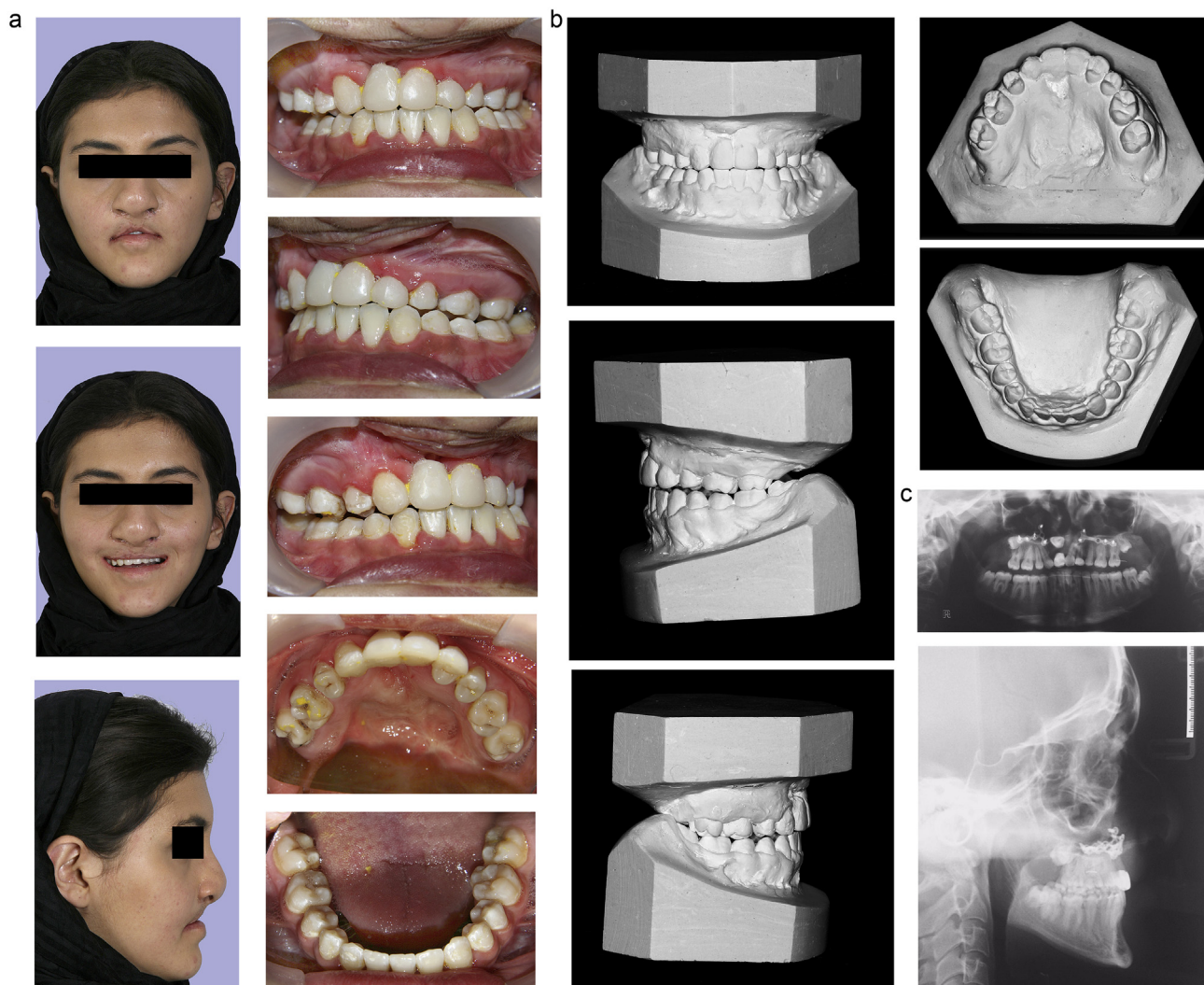After obtaining written informed consent, blood samples underwent DNA extraction. Mutation screening of the IRF6 gene was carried out by Sanger sequencing of all coding exons and adjacent intronic boundaries and aligned with the reference sequence applying SeqMan (Lasergene, Madison WI, USA). Results showed a known heterozygous splice site mutation (c.174+1 G/A). State of the art analysis tools assessed potential truncation and non-functional protein products. Slight maxillary relapse was observed during the follow-up sessions; therefore, nightly application of a face mask was considered in addition to routine retention appliances.

### 3. Discussion

In humans, mutations in the IRF6 gene can cause both autosomal dominant VWS and the popliteal pterygium syndrome [10]. VWS is said to be the most common of the over 300 syndromes with oral clefting. It is one of a few clefting syndromes in which a cleft lip with or without a cleft palate or a cleft palate occur in different members of the same family. It may also skip a generation or only manifest with small paramedian lower lip pits or mounds of tissue. Thus, a family history of any of these findings should raise suspicion. It has been stated that this syndrome is not associated with a consistent skeletal pattern. This is not surprising given the wide range of clinical expression from normal to cleft lip and palate, so that the skeletal pattern of each patient will be influenced by the particular malformation(s), if any is present [11]. In such cases, consultation with a clinical geneticist can provide valuable insight into a patient's condition, particularly when the less common cases or cases with multiple complexities are encountered in the clinic [12].

Precise orthodontic management is needed in children with such syndromes [13]. It includes presurgical orthopedics at early ages and phase I and II orthodontic treatment at proper ages [14]. Treatment of severe maxillary deficiencies with traditional orthognathic approaches necessitates waiting until skeletal maturity has been reached. It usually combines bimaxillary surgery to meet improvements in occlusal and aesthetic relationships. The fact is that despite all advantages and disadvantages of surgery, the procedure of mandibular setback on a normal mandible often compromises the long-term aesthetic outcomes. On the basis of these issues, we decided to perform maxillary distraction with a rigid, external fixed device. Distraction osteogenesis allows the body's healing system to generate new bone formation for augmenting or lengthening bone [15]. Besides, previously described benefits of





**Fig. 3.** (a) Post treatment photograph of the patient (b) Post treatment study models (c) Post treatment Panoramic view and lateral cephalogram.

maxillary distraction osteogenesis with the RED appliance allows for treatment of patients with severe maxillary deficiencies at almost any age [7].

The choice of early surgical repair can be psychologically useful for parents who look forward to an early “normalization” of the appearance of their child and are concerned about their child’s socialization. [16] Both upper cleft lip repair and lower lip hypotonia can contribute to development of deformities in patients with VW [16]. Central lip dysplasia is a key feature of VWS and it makes the lower lips hypotonic [5]. Many techniques have been advocated for the treatment of congenital sinuses of the lower lip. Although the lower lip pits in VWS appear simple to excise, it is difficult to achieve good aesthetic results [16]. A review of the literature showed that management of lower lip pits with simple excision usually requires more additional procedures due to unacceptable results and residual deformities [17,18].

The procedures in late childhood and adolescence should focus on occlusion, aesthetics and psychosocial concerns. They should be timed according to the child’s facial growth, eruption status of teeth, emotional maturity, and ability to cope with treatment. The ultimate goal of treatment should be to achieve intelligible speech and normal appearance with good balance of facial skeleton, soft tissues and occlusion, aiming to help the child develop into a confident young adult. Recent advances in tissue engineering have become available as regenerative treatment for bone defects in

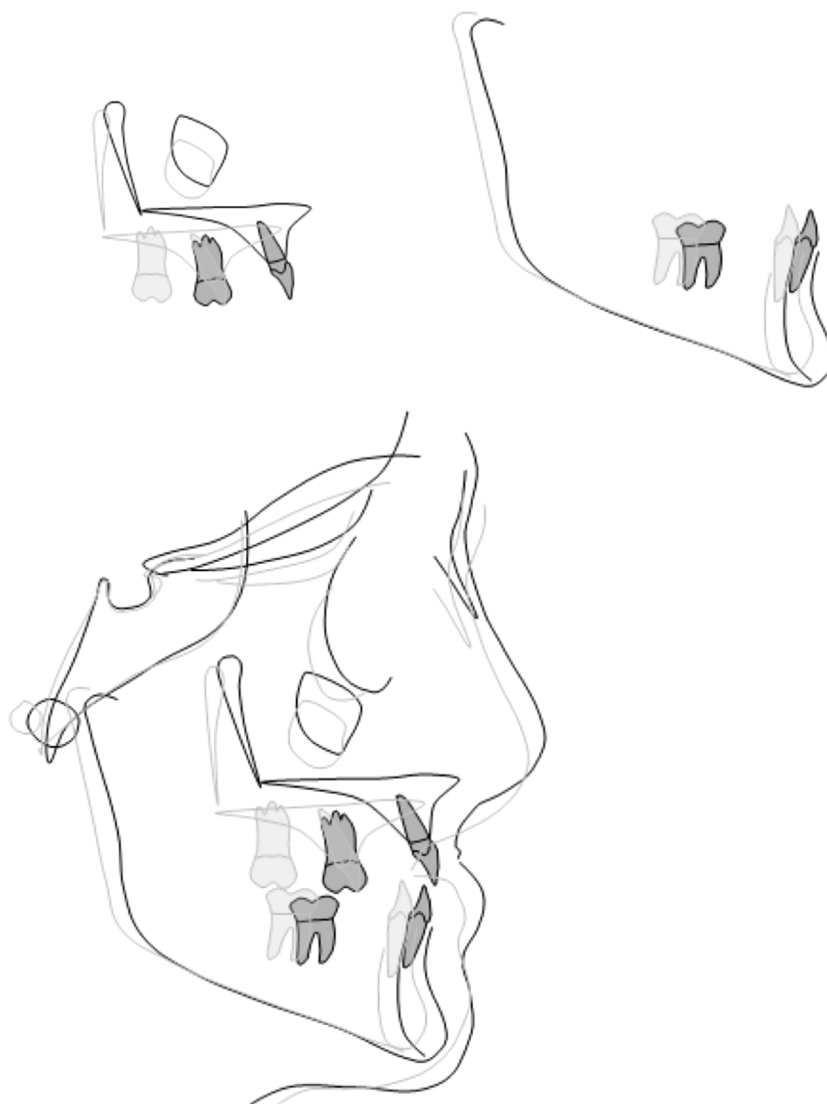
patients with such syndromes; however, more studies are required before the application of this method and enhancement of regeneration capacity [19,20].

This case report showed that, despite poor early management of a patient with VWS, further team work procedures during adolescence could sufficiently improve her facial aesthetics and dental occlusion.

In syndromic anomalies, collaboration between maxillofacial surgeons and orthodontists is the key factor for obtaining satisfying results. As described in the quote by famous American surgeon, Atul Gawande, advances in our technology and know-how have the potential to create better medical and dental outcomes for our patients, but they also create situations in which avoidable failures occur. Therefore, in the management of patients with skeletal jaw imbalances in the horizontal, vertical and/or transverse plane will benefit from the use of a checklist. The checklist provides both the patient and their doctors with an excellent means of achieving the desired treatment outcome when there is a significant dentofacial imbalance [21].

#### 4. Conclusion

The orthodontic treatment of a girl diagnosed with VWS requires a combination of comprehensive orthodontic treatment, secondary



**Fig. 4.** Pretreatment and post treatment lateral cephalogram superimposition.

bone graft [22], distraction osteogenesis for a deficient maxilla, secondary palatoplasty, and excision of lower lip pits, as well as prosthetic procedures to obtain a satisfactory outcome. The patient was satisfied with the results obtained, so she postponed her rhinoplasty. Genetic testing determined a known putative splice site mutation (c.174+1 G/A) as the prime cause of VWS in the patient and her family.

#### **Informed consent**

Written informed consent was obtained from the patient for publication of this case report and the accompanying images. A copy of the written consent is available for review by the Editor-in-Chief of this journal on request.

#### **Conflicts of interest**

No conflict of interest.

#### **Sources of funding**

No source of funding.

#### **Ethical approval**

It was a case report.

#### **Consent**

Obtained written and signed consent provided from the patient.

#### **Author contribution**

Dr Tehranchi and Dr Mina contributed in orthodontic treatment of the patient and writing the paper.

Dr Behnia and Dr Nadjmi contributed in surgical procedures and RED device application.

Dr Yassaee and Dr Ravesh contributed in genetic data interpretation and gene mutation analysis.

#### **Registration of research studies**

This is a case report.

**Guarantor**

Dr Morteza Mina.

**References**

- [1] B.C. Schutte, B.C. Bjork, K.B. Coppage, et al., A preliminary gene map for the Van der Woude syndrome critical region derived from 900 kb of genomic sequence at 1q32-q41, *Genome Res.* 10 (1) (2000) 81–94.
- [2] P.A. Mossey, J. Little, R.G. Munger, M.J. Dixon, W.C. Shaw, Cleft lip and palate, *Lancet* (London, England) 374 (9703) (2009) 1773–1785.
- [3] A.B. Burdick, D. Bixler, C.L. Puckett, Genetic analysis in families with van der Woude syndrome, *J. Craniofac. Genet. Dev. Biol.* 5 (2) (1985) 181–208.
- [4] A.R. Vieira, Unraveling human cleft lip and palate research, *J. Dent. Res.* 87 (2) (2008) 119–125.
- [5] C.H. Chen, H.T. Liao, V.B. Shyu, P.K. Chen, Inverted-T lip reduction for lower lip repair in Van der Woude syndrome: a review and comparison of aesthetic results, *Int. J. Oral Maxillofac. Surg.* 42 (2) (2013) 198–203.
- [6] M. Rizos, M.N. Spyropoulos, Van der Woude syndrome: a review Cardinal signs, epidemiology, associated features, differential diagnosis, expressivity, genetic counselling and treatment, *Eur. J. Orthod.* 26 (1) (2004) 17–24.
- [7] J.W. Polley, A.A. Figueroa, Management of severe maxillary deficiency in childhood and adolescence through distraction osteogenesis with an external, adjustable, rigid distraction device, *J. Craniofac. Surg.* 8 (3) (1997) 181–185 (discussion 186).
- [8] R.A. Agha, A.J. Fowler, A. Saeta, I. Barai, S. Rajmohan, D.P. Orgill, The SCARE statement: consensus-based surgical case report guidelines, *Int. J. Surg.* (London, England) 34 (2016) 180–186.
- [9] N. Nadjmi, R. Van Erum, M. De Bodt, E.M. Bronkhorst, Two-stage palatoplasty using a modified Furlow procedure, *Int. J. Oral Maxillofac. Surg.* 42 (5) (2013) 551–558.
- [10] F. Rahimov, M.L. Marazita, A. Visel, et al., Disruption of an AP-2alpha binding site in an IRF6 enhancer is associated with cleft lip, *Nat. Genet.* 40 (11) (2008) 1341–1347.
- [11] A.K. Lam, D.J. David, G.C. Townsend, P.J. Anderson, Van der Woude syndrome: dentofacial features and implications for clinical practice, *Aust. Dent. J.* 55 (1) (2010) 51–58.
- [12] W.E. Roberts, J.K. Hartsfield Jr., Multidisciplinary management of congenital and acquired compensated malocclusions: diagnosis, etiology and treatment planning, *J. (Ind. Dent. Assoc.)* 76 (2) (1997) 42–43 (45–48, 50–41; quiz 52).
- [13] M. Mina, A. Borzabadi-Farahani, A. Tehranchi, M. Nouri, F. Younessian, Mathematical Beta Function Formulation for Maxillary Arch Form Prediction in Normal Occlusion Population, *Odontology/the Society of the Nippon Dental University*, 2016.
- [14] R. Chigurupati, Cleft lip and palate: timing and approaches to reconstruction, in: C. Shahrokh Bagheri, R. Bryan Bell, H.A. Khan (Eds.), *Current Therapy In Oral and Maxillofacial Surgery*, Vol. 1, Saunders, 2011, pp. 726–750.
- [15] A. Tehranchi, H. Behnia, Facial symmetry after distraction osteogenesis and orthodontic therapy, *Am. J. Orthod. Dentofac. Orthop.* 120 (2) (2001) 149–153.
- [16] N. Capon-Degardin, V. Martinot-Duquennoy, G. Auvray, P. Pellerin, Lower lip repair in Van der Woude syndrome, *Eur. J. Pediatr. Surg.* 13 (2) (2003) 92–96.
- [17] A.E. Rintala, A.Y. Lahti, U.S. Gylling, Congenital sinuses of the lower lip in connection with cleft lip and palate, *Cleft Palate J.* 7 (1970) 336–346.
- [18] D.G. Bowers, Surgical repair of congenital lower lip sinuses, *Plast. Reconstr. Surg.* 49 (6) (1972) 632–636.
- [19] H. Behnia, A. Khojasteh, M. Soleimani, et al., Secondary repair of alveolar clefts using human mesenchymal stem cells, *Oral Surg. Oral Med. Oral Pathol. Oral Radiol. Endodon.* 108 (2) (2009) e1–e6.
- [20] H. Behnia, A. Khojasteh, M. Soleimani, A. Tehranchi, A. Atashi, Repair of alveolar cleft defect with mesenchymal stem cells and platelet derived growth factors: a preliminary report, *J. Craniomaxillofac. Surg.* 40 (1) (2012) 2–7.
- [21] D.R. Musich, Orthodontic treatment in patients requiring orthognathic surgical procedures, in: V. Krishnan, Z. Davidovitch e (Eds.), *Integrated Clinical Orthodontics*, Vol. 1st, Wiley-Blackwell, 2012, p. 332.
- [22] H. Behnia, A. Mesgarzadeh, A. Tehranchi, G. Morad, S. Samieerad, F. Younessian, Stabilization of premaxilla repositioned during secondary bone grafting in complete bilateral cleft lip and palate patients, *J. Craniofac. Surg.* 25 (4) (2014) 1554–1557.

**Open Access**

This article is published Open Access at [sciencedirect.com](https://www.sciencedirect.com). It is distributed under the [IJSCR Supplemental terms and conditions](#), which permits unrestricted non commercial use, distribution, and reproduction in any medium, provided the original authors and source are credited.