Left retrocaval ureter around the ipsilateral limb of a double caudal vena cava in a cat

Reference:

Casteleyn Christophe, Cornillie P., Van Cruchten Steven, van Ginneken Christa.- Left retrocaval ureter around the ipsilateral limb of a double caudal vena cava in a cat
Journal of comparative pathology - ISSN 0021-9975 - 152:4(2015), p. 313-316
Full text (Publishers DOI): http://dx.doi.org/doi:10.1016/j.jcpa.2015.01.010
To cite this reference: http://hdl.handle.net/10067/1248530151162165141

Left retrocaval ureter around the ipsilateral limb of a double caudal vena cava in a cat

C. Casteleyn[a], P. Cornillie[b], S. Van Cruchten[a] and C. Van Ginneken[a]

[a] *Laboratory of Applied Veterinary Morphology, Department of Veterinary Sciences, Faculty of Pharmaceutical, Biomedical and Veterinary Sciences, University of Antwerp, Universiteitsplein 1, B-2610 Wilrijk, Belgium*

[b] *Department of Morphology, Faculty of Veterinary Medicine, Ghent University, Salisburylaan 133, B-9820 Merelbeke, Belgium*

Correspondence to: Christophe Casteleyn
christophe.casteleyn@uantwerpen.be
Tel.: +32 3 265 2821

Summary

Necropsy of an adult, neutered male cat, which was euthanized due to its FIV-positive status, demonstrated the presence of a left retrocaval ureter that was entrapped around the left limb of a double caudal vena cava. These associated anomalies originate from the complex embryofoetal development of the caudal vena cava. Since no clinical signs had been reported and no gross lesions related to this anomaly were observed, this manifestation should be considered as a mere anatomical variation.

Keywords: Double caudal vena cava; retrocaval ureter; cat

An adult, neutered male cat (*Felis catus*) was euthanized after being tested positive for FIV (feline immunodeficiency virus). The cadaver was presented at the Department of Veterinary Sciences of the University of Antwerp for educational purposes. No gross macroscopic lesions potentially associated with FIV positivity were found. However, the cat presented a double caudal vena cava. More specifically, the left and right caudal vena cava merged only at the level of the first lumbar vertebra to form a single vessel. The left and right caudal vena cava individually drained the ipsilateral common iliac veins. No anastomoses were found between the left and right counterparts at the level of the iliac veins, nor between any other segment of the double caudal vena cava. Just prior to its confluence with its contralateral part, the left caudal vena cava crossed the abdominal aorta ventrally (Fig. 1).

The complex embryofoetal development of the caudal vena cava lies at the basis of the observed vascular anomaly. For years, the supracardinal model that was published (for the cat) in 1920 by Huntington and McClure was considered the gold standard. This model that is applied in both human and veterinary embryology states that the right-sided counterparts of three pairs of embryonic veins (i.e. supracardinal, subcardinal and caudal cardinal veins) form the abdominal part of the caudal vena cava by means of fusion, anastomosis and asymmetric vascular degeneration during prenatal life (Huntington and McClure, 1920; Butler, 1927; Cornillie and Simoens, 2005; Cornillie et al., 2006; Hyttel, 2010; Sadler, 2012).

However, a recent study revisiting the development of the inferior vena cava and vena azygos by means of three-dimensional reconstructions of human embryos (Hikspoors et al., 2014) has revealed various inaccuracies in the supracardinal system of Huntington and McClure (1920). All dorsal veins, formerly indicated as the supracardinal veins, have to be considered as actual segments of the caudal cardinal system that gradually adopts a different topography due to allometric growth of surrounding organs and tissues. What is important for the present case is that, according to these recent insights, two paired longitudinal channels

53 can be found in the region of the kidneys, namely both caudal cardinal veins, which course at
54 the dorsomedial side of the kidneys, and the caudal extensions of the subcardinal veins, which
55 also run medially but ventral to the kidneys.

56 At the pelvic inlet, just caudal to the bifurcation of the aorta into the umbilical arteries,
57 these four veins are united in a huge anastomosis. At a certain point during development the
58 caudal cardinal venous segments draining into the subcardinal anastomosis at the
59 craniomedial poles of the kidneys, the infrarenal segments of the subcardinal veins collecting
60 and interconnecting the left and right common iliac veins, and tributaries of both venous
61 systems form a vascular ring around the ipsilateral kidney and ureter (Cornillie and Simoens,
62 2005; Hikspoors et al., 2014). This complex venous configuration evolves from a bilateral
63 symmetric system to a single, right-sided vein, in a process during which the left-sided
64 counterparts of all aforementioned veins gradually disappear (Cornillie and Simoens, 2005)
65 (Fig. 2). The presence of a double caudal vena cava is therefore considered to result from the
66 persistence of the left-sided venous segments, in combination with the absence of the
67 aforementioned iliac anastomosis (Bass et al., 2000; Cornillie, 2008).

68 Moreover, careful dissection during necropsy revealed another curiosity. The left
69 ureter was entrapped by the left (limb of the) caudal vena cava, a condition known as
70 retrocaval or circumcaval ureter (Gramegna et al., 2003). It slightly deviated towards the
71 midline to cross the left caudal vena cava dorsally, at the level of the fifth lumbar vertebra.
72 The left ureter resumed its more lateral course towards the urinary bladder after emerging
73 between the vein and the left psoas musculature. The right ureter presented a normal course
74 along the right psoas muscles (Fig. 3).

75 A rare case of retrocaval ureter in an intact male cat was reported in 2006 by Cornillie
76 and co-workers. This cat, however, presented a right retrocaval ureter associated with a single
77 caudal vena cava. The recently gained insights into the development of the infrarenal part of

the caudal vena cava allow formulation of the following hypothesis on the origin of a retrocaval ureter. The basis is that the infrarenal segment of the subcardinal vein, which forms the ventral branch of the circumureteric vascular ring, persists instead of the dorsally located caudal cardinal vein. When the subcardinal vein contributes in the formation of the caudal vena cava, it will cross the ureter ventrally and sweep it along its migratory path towards the midline. This results in the medial deviation and entrapment of the ureter between the caudal vena cava and psoas musculature. In our case with occurrence of a left retrocaval ureter associated with a double caudal vena cava, it is hypothesized that this occurred on the left side. More specifically, the infrarenal part of the left limb of the caudal vena cava was formed by the persisting infrarenal segment of the subcardinal vein that runs ventral to the left ureter, while the right limb was formed by the caudal cardinal vein that runs dorsal to the right ureter (Fig. 4).

According to an extended study performed by Bélanger and co-workers (2014), who examined the carcasses of 301 cats, a right retrocaval ureter is a rather common anatomic variation. It was seen in 28% of the examined carcasses. Far more unique is the presence of a left retrocaval ureter, having a prevalence of 1%. The presence of a double caudal vena cava without entrapment of one or both ureters is seldom seen (0.7%). The combination of the vascular and urinary variations is more typical as it has been observed in approximately 5% of the examined carcasses. The combination of a left retrocaval ureter and a double caudal vena cava was only observed in one female cat (Bélanger et al., 2014). So, this case report is the first to describe these findings in a male cat.

The clinical relevance of the presented anomalies is unknown since no gross macroscopic lesions were observed and no clinical signs had been reported. Nevertheless, it is likely that cats with retrocaval ureters are more susceptible to ureteral obstruction and consequently hydronephrosis. The former can be the result of the external pressure exerted on

the ureter by the caudal vena cava that retracts the ureter to the midline (Cornillie et al., 2006). Moreover, humans that develop kidney stones may suffer from obstructing uroliths that cannot pass the ureter where it sweeps around the caudal vena cava to flow to the urinary bladder (Soundappan and Barker, 2004). In cats, the pathogenesis of urolithiasis is different from that in humans as cats are more prone to develop lower urinary tract disease. This is characterized, amongst others, by the formation of urinary bladder stones and the potential obstruction of the urethra (Lund et al., 2013).

In summary, retrocaval ureter(s) and/or a double caudal vena cava in cats are rarely observed during necropsy. Since no clinical signs have yet been associated with these anomalies, they should be considered as mere anatomical variations.

Conflict of interest statement: The authors have no conflict of interest to report.

References

Bass JE, Redwine MD, Kramer LA, Huynh PT, Harris JH (2000) Spectrum of congenital anomalies of the inferior vena cava: cross-sectional imaging findings. *Radiographics*, **20**, 639-652.

Bélanger R, Shmon CL, Gilbert PJ, Linn KA (2014) Prevalence of circumcaval ureters and double caudal vena cava in cats. *American Journal of Veterinary Research*, **75**, 91-95.

Butler EG (1927) The relative role played by the embryonic veins in the development of the mammalian vena cava posterior. *American Journal of Anatomy*, **39**, 267-353.

Cornillie P (2008) *Development of the caudal vena cava in the pig embryo: a three-dimensonal angiogenic model*. PhD Thesis, Ghent University.

Cornillie P, Baten T, Simoens P (2006) Retrocaval ureter in a cat. *The Veterinary Record*, **159**, 24-25.

128 Cornillie P, Simoens P (2005) Prenatal development of the caudal vena cava in mammals:
129 review of the different theories with special reference to the dog. *Anatomia, Histologia,*
130 *Embryologia*, **34**, 364-372.
131 Gramegna V, Madaro A, Pellegrini F, Capizzi S, Romano O, et al. (2003) A rare case of
132 retrocaval ureter associated with persistent left vena cava. *Urologia Internationalis*, **70**,
133 337-338.
134 Hikspoors JPJM, Soffers JHM, Mekonen HK, Cornillie P, Köhler SE et al. (2014).
135 Development of the infrahepatic inferior caval and azygos venous systems in human.
136 *Journal of Anatomy* (in press).
137 Huntington GS, McClure CFW (1920) The development of the veins in the domestic cat
138 (*Felis domestica*) with especial reference, 1) to the share taken by the supracardinal veins
139 in the development of the postcava and azygos veins and 2) to the interpretation of the
140 variant conditions of the postcava and its tributaries, as found in the adult. *The Anatomical*
141 *Record*, **20**, 1-30.
142 Hyttel P (2010) Development of the blood cells, heart and vascular system. In: *Essentials of*
143 *Domestic Animal Embryology*, 1st Edit., P Hyttel, F Sinowatz, M Vejlsted, Eds., Elsevier,
144 Oxford, pp. 182-207.
145 Lund HS, Krontveit RI, Halvorsen I, Eggertsdóttir AV (2013) Evaluation of urinalyses from
146 untreated adult cats with lower urinary tract disease and healthy control cats: Predictive
147 abilities and clinical relevance. *Journal of Feline Medicine and Surgery*, **15**, 1086-1097.
148 Sadler TW (2012) Cardiovascular system. In: *Langman's Medical Embryology*, 12th Edit.,
149 TW Sadler, Ed., Lippincot Williams & Wilkins, Philadelphia, 162-200.
150 Soundappan SVS, Barker AP (2004) Retrocaval ureter in children: a report of two cases.
151 *Pediatric Surgery International*, **20**, 158-160.

Figure legends

Fig. 1. Ventral view of the opened abdominal cavity in a necropsied neutered male cat demonstrating the presence of a left caudal vena cava (l cvc) and a right caudal vena cava (r cvc). The left ureter (arrows) is entrapped by the former vessel. ll = left lung, li = liver, st = stomach, sp = spleen, l rv = left renal vein, lk = left kidney, cd = colon descendens, j = jejunum, ub = urinary bladder, fh = femoral head.

Fig. 2. Ventral schematic views of a human embryo (L = left side, R = right side) showing the development of the caudal vena cava (after Hikspoors et al., 2014). First (left image), a vascular ring around each kidney and ureter is formed by the caudal cardinal venous segments (1: I and IV) that drain into the subcardinal anastomosis (a and b) at the craniomedial poles of the kidneys (2), the infrarenal segments of the subcardinal veins (3: II and III) that collect (c and d) and interconnect (e) the left and right common iliac veins, and tributaries of both venous systems. The paired subcardinal vein anastomoses in the ventral midline (f). Subsequently (right image), the infrarenal part of the caudal vena cava is formed by the interconnection of the left and right common iliac veins (e). The renal part is made of the right-sided caudal cardinal vein (I), whereas the suprarenal segment is formed by the right side of the regressing anastomosis (f). The renal veins originate from the cranial anastomoses between the caudal cardinal and subcardinal venous systems (a and b).

Fig. 3. Ventral view of the abdominal cavity of the same cat as in Fig. 1. The structures of interest have been dissected to clearly show the retrocaval position of the left ureter. The kidneys have been removed and the urinary bladder was incised to investigate the potential presence of hydronephrosis and urolithiasis, respectively. cvc = caudal vena cava, l cvc = left

caudal vena cava, r cvc = right caudal vena cava, lu = left ureter, pm = psoas muscles, aa = abdominal aorta, ru = right ureter, fh = femoral head, ub = urinary bladder.

Fig. 4. Schematic representation of the formation of a left retrocaval ureter in the presence of a double caudal vena cava. When the left limb of the caudal vena cava (l cvc) is formed by the persisting subcardinal vein (III), it will cross the ureter ventrally and entrap it while making the anastomosis with the caudal cardinal vein (d), which is located dorsal to the ureter, at the pelvic inlet. The absence of a right retrocaval ureter is explained by the formation of the right limb of the caudal vena cava by the right caudal cardinal vein (a, I and c) that runs dorsal to the ureter. lk = left kidney, lu = left ureter, rk = right kidney, ru = right ureter, cvc = caudal vena cava, r cvc = right caudal vena cava.

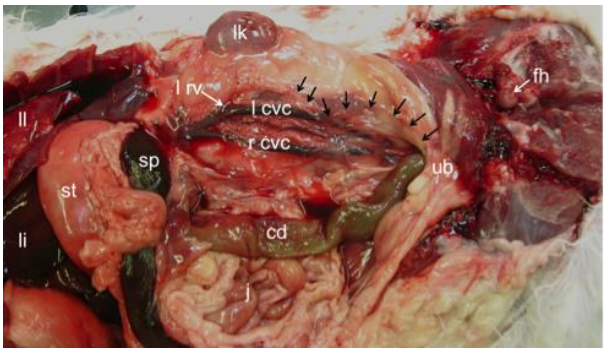

Fig. 1

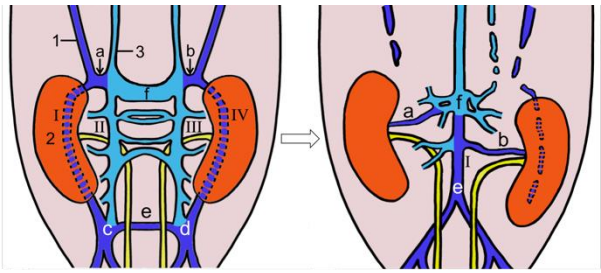

Fig. 2

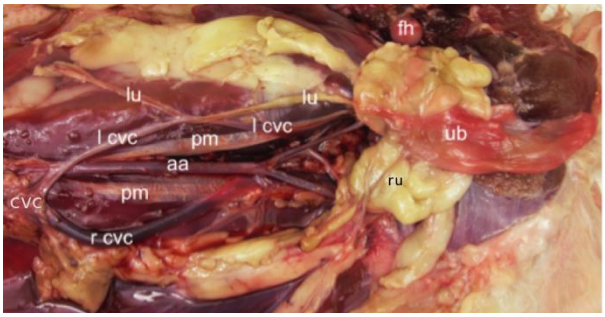
fh
lu
lu
l cvc
pm
l cvc
ub
aa
ru
cvc
pm
r cvc

Fig. 3

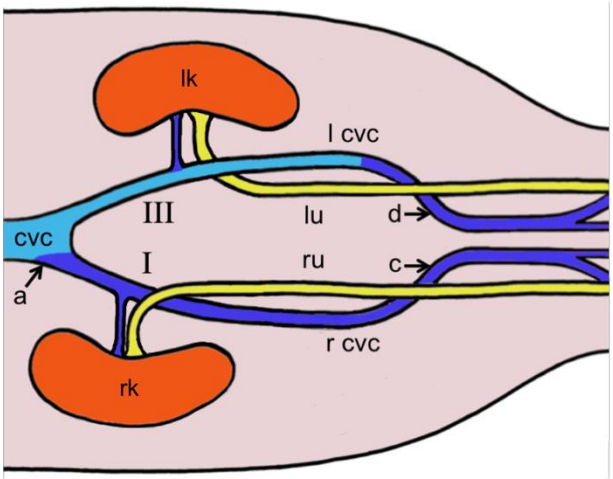
lk
l cvc
III
lu
d
cvc
I
ru
c
a
r cvc
rk

Fig. 4