



SURGICAL MANAGEMENT OF A PENETRATING BRAIN WOUND AND ASSOCIATED PERFORATING OCULAR INJURY CAUSED BY A LOW-VELOCITY SHARP METALLIC OBJECT: A CASE REPORT AND LITERATURE REVIEW

Bruno Splavski^{1,2,3}, Renata Iveković⁴, Ivan Bošnjak¹, Brano Splavski Jr⁵, Ante Rotim¹
and Krešimir Rotim^{1,2,3}

¹Department of Neurosurgery, Sestre milosrdnice University Hospital Center, Zagreb, Croatia

²J. J. Strossmayer University of Osijek Faculty of Medicine, Osijek, Croatia

³University of Applied Health Sciences, Zagreb, Croatia

⁴Department of Ophthalmology, Sestre milosrdnice University Hospital Center, Zagreb, Croatia

⁵Department of Ophthalmology, University Hospital, Antwerp, Belgium

SUMMARY – Penetrating traumatic brain injury accompanied by perforating ocular injury caused by low-velocity foreign bodies is a life-threatening condition, a surgical emergency and a major challenge in surgical practice, representing a severe subtype of non-missile traumatic brain injury, which is a relatively rare pathology among civilians. Optimal management of such an injury remains controversial, requiring full understanding of its pathophysiology and a multidisciplinary expert approach. Herein, we report a case of penetrating brain and associated perforating eye injury and discuss relevant literature providing further insight into this demanding complex multi-organ injury. We present a case of 39-year-old male patient with transorbital penetrating brain and perforating ocular injury undergoing emergency surgery to remove a retained sharp metallic object from the left parietal lobe. Following appropriate and urgent diagnostics, a decompressive left-sided fronto-temporo-parietal craniectomy was immediately performed. A retained sharp metallic object (a slice of a round saw) was successfully removed, while primary left globe repair and palpebral and fornix reconstruction were performed afterwards by an ophthalmologist. A prophylactic administration of broad-spectrum antibiotics was applied to prevent infectious complications. Early postoperative recovery was uneventful. The patient was discharged on day 45 post-injury having moderate right-sided motor weakness, ipsilateral facial nerve central palsy, and light motoric dysphasia. The vision to his left eye was completely and permanently lost. In conclusion, management of non-missile transorbital penetrating brain injury can be satisfactory when proper clinical and radiologic evaluation, and amply, less radical surgical approach is performed early. A multidisciplinary routine is a prerequisite in achieving a favorable management outcome.

Key words: *penetrating traumatic brain injury; transorbital; perforating ocular injury; low-velocity non-missile injury; retained foreign bodies; surgical management; outcome*

Introduction

Penetrating traumatic brain injury (PTBI) caused by low-velocity sharp objects represents a severe subtype of non-missile traumatic head injury, and a relatively rare pathology among civilians, with better outcomes because of more localized primary injury¹.

Correspondence to:

Bruno Splavski, MD, PhD

Department of Neurosurgery

Sestre milosrdnice University Hospital Center

Vinogradska 29, 10 000 Zagreb, Croatia

e-mail: splavuno@gmail.com

Received April 21, 2022, accepted May 11, 2022

However, it still presents a life-threatening condition and a significant challenge to practicing neurosurgeons worldwide², particularly when it is associated with perforating eye injury. In such cases, the surgical strategy is divided into the transorbital and transcranial approach³.

Hence, personalized and timely surgical intervention should be undertaken depending on the mechanism and the extent of PTBI⁴.

Optimum management of this potentially fatal injury is still ambiguous and controversial, requiring ample understanding of its pathophysiology^{1,4}, and a multidisciplinary expert approach. Nonetheless, such an injury can be satisfactorily treated by proper preoperative imaging, prompt surgical management, and adequate postoperative care.

The orbit forms an easy pathway for low-velocity foreign bodies penetrating into the intracranial space⁵. In spite of that, orbitocranial PTBI is relatively rare in clinical practice, representing an unfamiliar subset of head injury⁶. Perforating open-globe injury is categorized as an object incoming through one part of the eye and exiting through another⁷, and it is often accompanied by intraorbitally retained foreign bodies. In such a mechanical injury, surgical urgency consisting of primary ocular repair is mandatory. However, the best treatment of poorly accessible retained bone and metallic foreign bodies has not been fully recognized yet⁸⁻¹⁷.

Herein we present a case of transorbital penetrating brain and associated perforating eye injury, including its clinical presentation, imaging and management, and discuss recent relevant literature, providing further insight into this demanding complex multi-organ injury.

Methods

We present a case report of the patient with penetrating brain and perforating ocular injury undergoing emergency multidisciplinary expert surgical treatment consisting of wound debridement, decompressive craniectomy, removal of accessible retained foreign bodies from brain parenchyma and the orbit, globe closure, and eyelid reconstruction.

Preoperative imaging, including native, non-contrast computed tomography (CT) of the head and CT angiography (CTA) was selectively performed to assist the surgical plan. Immediate wound debridement, ocular injury repair, and decompressive craniectomy were carried out. Foreign objects were removed surgi-

cally, but only those that were accessible. Postoperative prophylactic administration of broad-spectrum antibiotics was used to prevent infectious complications including endophthalmitis, meningitis, and/or brain abscess formation.

Initial standard ophthalmology evaluation including visual acuity, pupillary assessment, fundoscopic examination, and intraocular pressure measurement was not performed due to an emergency. Cautious external and anterior segment inspections were performed to determine the grade of orbital and eye globe damage.

Case report

An otherwise healthy 39-year-old man was transferred to the Emergency Department after sustaining a non-missile transorbital penetrating brain and concomitant left eye perforating injury during mechanical work with a round saw (Fig. 1). He was comatose upon arrival and non-responding to mechanical stimuli, but was hemodynamically stable and breathing spontaneously. The left orbital roof was the route by which foreign bodies had entered the brain.

The left eye globe was fully traumatized. The patient had sustained a full-thickness scleral wound extending from lateral corneal limbus from the 1 o'clock position backwards to the optical nerve. There was also a huge uveal and vitreous prolapse, while the lens was not identified.

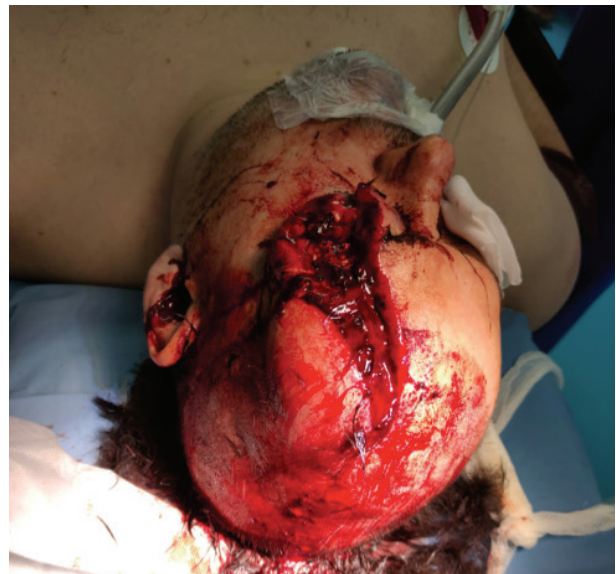

Fig. 1. Photograph of the patient showing the left transorbital eye ball perforating open wound entering the skull base.

Urgent native head CT showed multiple bone fragments and metallic foreign bodies in the lateral extra-ocular aspect of the left orbit and in the left lateral rectus muscle (likely the entry wound) (Fig. 2 a), as well as above and behind the crushed globe in

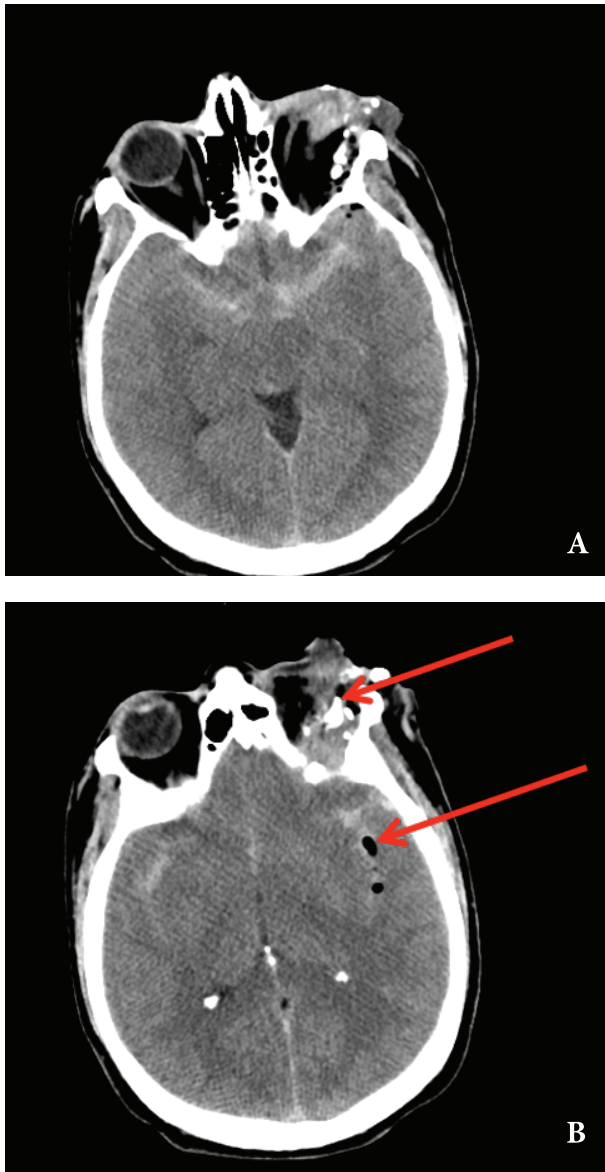


Fig. 2. Urgent native axial head computed tomography (CT) showing subarachnoid hemorrhage and radiodense multiple bone fragments and metallic foreign bodies in the lateral extraocular aspect of the left orbit and in the left lateral rectus muscle (a), as well as above and behind the destroyed globe in the left orbit (arrow), together with emphysematous changes along the projectile endocranial path filled with a small amount of air (pneumocephalus) (arrow) (b).

the left orbit (Fig. 2 b). Traumatic damage of brain parenchyma was visible along the projectile endocranial path, filled out with drops of air and encompassed by subarachnoid hemorrhage (Fig. 2 b). It also revealed a blood-filled penetrating wound impact canal throughout the brain parenchyma, spreading from the left temporobasal region up to the left parietal lobe, which was packed with retained foreign bodies/bony fragments and a small amount of air (Fig. 3 a). A sharp metallic object was subcortically lodged in the left parietal lobe, perpendicular to the parietal bone (Fig. 3 b, c and d). A computed tomography angiogram (CTA) showed no obvious vascular injury of brain vessels, but the imaging was restricted due to metallic artifacts.

The patient was immediately taken to the operating room for combined neurosurgical and ophthalmological surgical treatment. A large decompressive left-sided fronto-temporo-parietal craniectomy was urgently performed. The left transorbital penetrating wound entering the skull base was thoroughly inspected, irrigated with a saline solution, and relieved of wound debris and tiny bony particles originating from the orbital roof communitive fracture, as well as from intracranially retained minute metallic foreign bodies. A photograph illustrating the primary left globe injury before repair by an ophthalmologist is shown in Fig. 4. A large and sharp triangular metallic foreign object measuring 40.0x3.2 mm (a slice of the round saw), which was rough and broken around its edges, was identified by finger palpation as subcortically lodged in the left parietal lobe. It was successfully removed under direct visualization with minimal cortical damage and bleeding (Fig. 5 a, b). Exact hemostasis was achieved, the dura was suspended and left wide open, epidural vacuum drain was placed, and the wound was closed on the layers. Wound debridement had been carried out previously.

Subsequently, the patient underwent primary left globe repair by an ophthalmologist, during which the prolapsed uvea and vitreous body were removed, while scleral lacerations and eyelids were repaired in all layers. The roof of the left orbit was revealed and inspected, and then packed with foam gel to stop the communication between the orbit and endocranial space.

Postoperatively, the patient was taken to the Intensive Care Unit (ICU) and mechanically ventilated. On day 2 post injury, he regained consciousness, was extubated, and developed contralateral hemiplegia together with right central facioparesis and sensory and motor transitory aphasia.

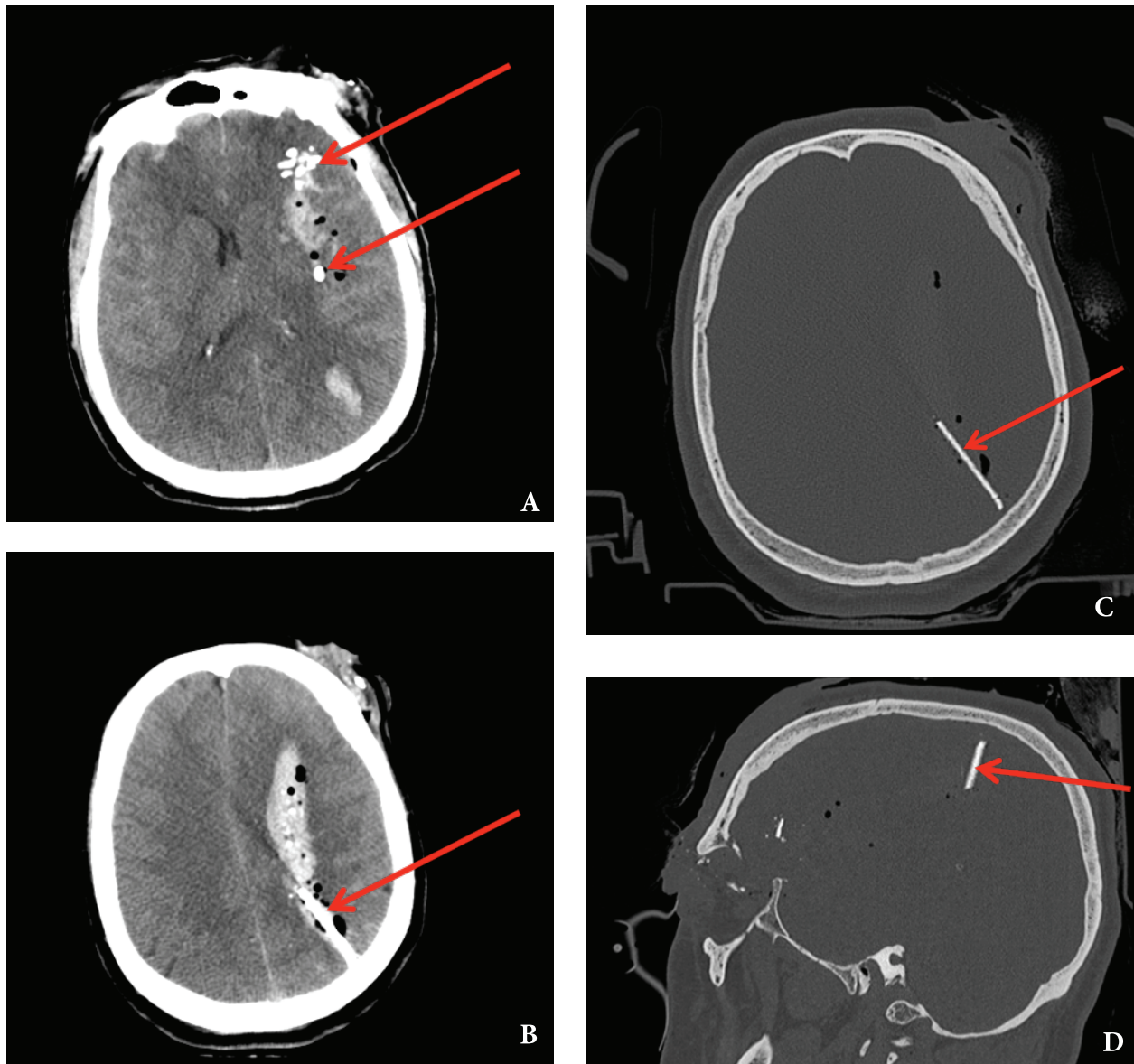


Fig. 3. Native axial brain CT showing brain edema revealing endocranially retained multiple radiodense foreign bodies and bony fragments along the penetrating wound impact canal (arrow), filled with intracerebral hemorrhage and small amounts of intracranial air (a). A blood-filled wound canal throughout brain parenchyma ending in the left parietal lobe subcortically, where a sharp metallic object is lodged (arrow) (b). Axial (c) and sagittal brain CT bone window reformation (d), identifying endocranially retained metallic objects oriented perpendicularly to the parietal bone (arrows).

The early postoperative non-contrast head CT scan showed a diffuse edema of the left hemisphere with a mass protruding throughout the edges of the craniectomic bone defect, and a penetrating wound impact canal filled with retained foreign bodies and intracerebral hemorrhage in regression (Fig. 6 a).

To prevent infectious complications, prophylactic administration of broad-spectrum antibiot-

ics (*vancomycin*, *meropenem*, and a third-generation cephalosporin – *ceftazidime* for 14 days) as well as intravitreal antibiotics to reduce the risk of endophthalmitis were applied. Although the dura was left wide open during a decompressive craniectomy, the patient did not have a reported cerebrospinal fluid (CSF) leak post-procedure or any signs of CNS infection.

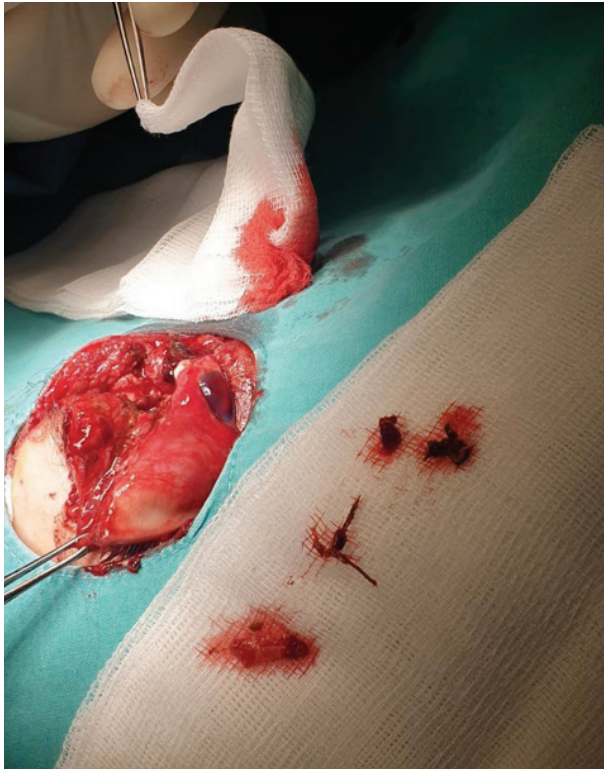


Fig. 4. Intraoperative photography illustrating the left globe and extracted foreign bodies before primary repair by an ophthalmologist.

Repeated native axial brain CT performed on day 45 post injury confirmed almost complete regression of intra-axial intracerebral hemorrhage with sporadic zones of post-traumatic encephalopathy and retained bone fragments, but without compressive mass effect/midline shifting and a slight ventricular enlargement of the left lateral ventricle frontal horn (Fig. 6 b). Control native axial CT of the brain performed at a 6-month check-up revealed a zone of post-traumatic cerebral parenchymal loss of the left fronto-parietal area (Fig. 6 c).

The patient was discharged to a rehabilitation facility on day 45 post injury with moderate right-sided motor weakness (contralateral hemiparesis), right 7th cranial nerve central palsy (face weakness) and light motor dysphasia (Fig. 7). Unfortunately, the vision to the left eye was completely and permanently lost and phthisis of the left eye was expected. At 6-month follow-up and after a protracted long-term physical and logopedics rehabilitation, motor and speech deficits were substantially diminished and overall functional outcome was greatly im-

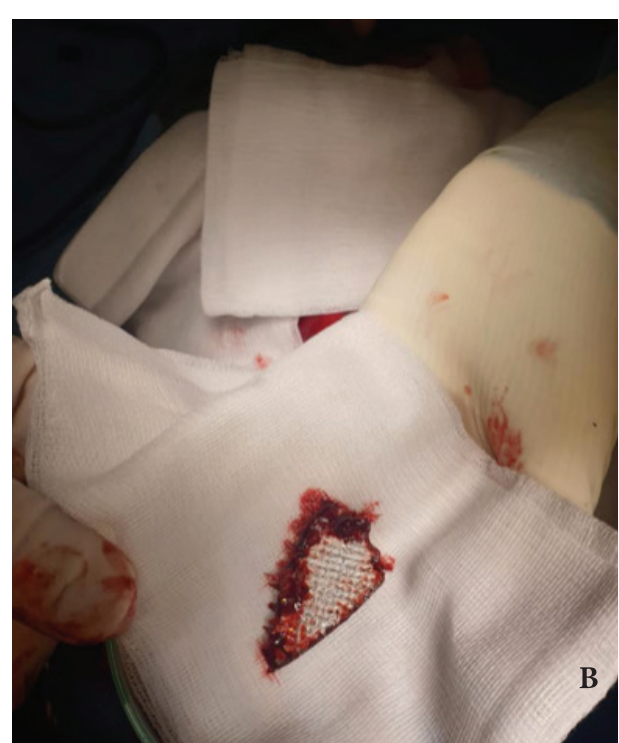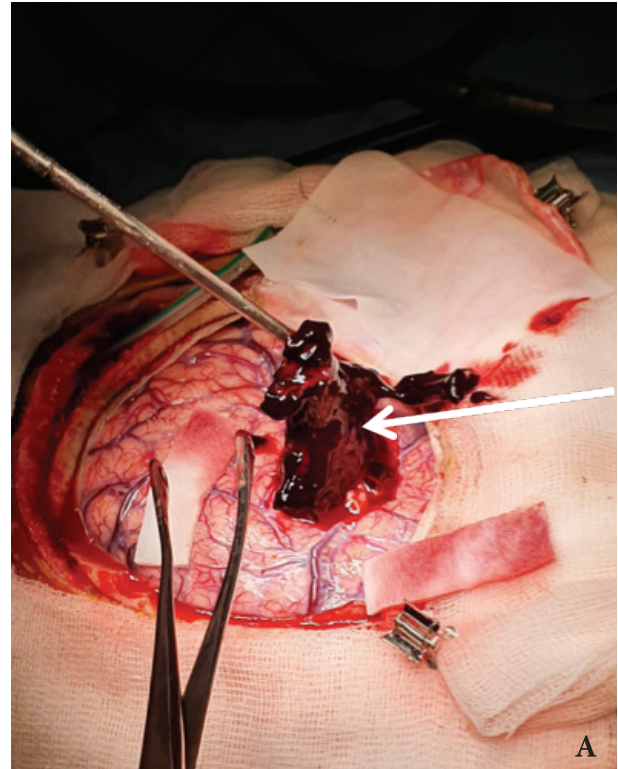


Fig. 5. Intraoperative photography showing successful removal of a foreign object lodged in the left parietal lobe subcortically (white arrow) (a). A sharp and rough triangular metallic object being removed (b).

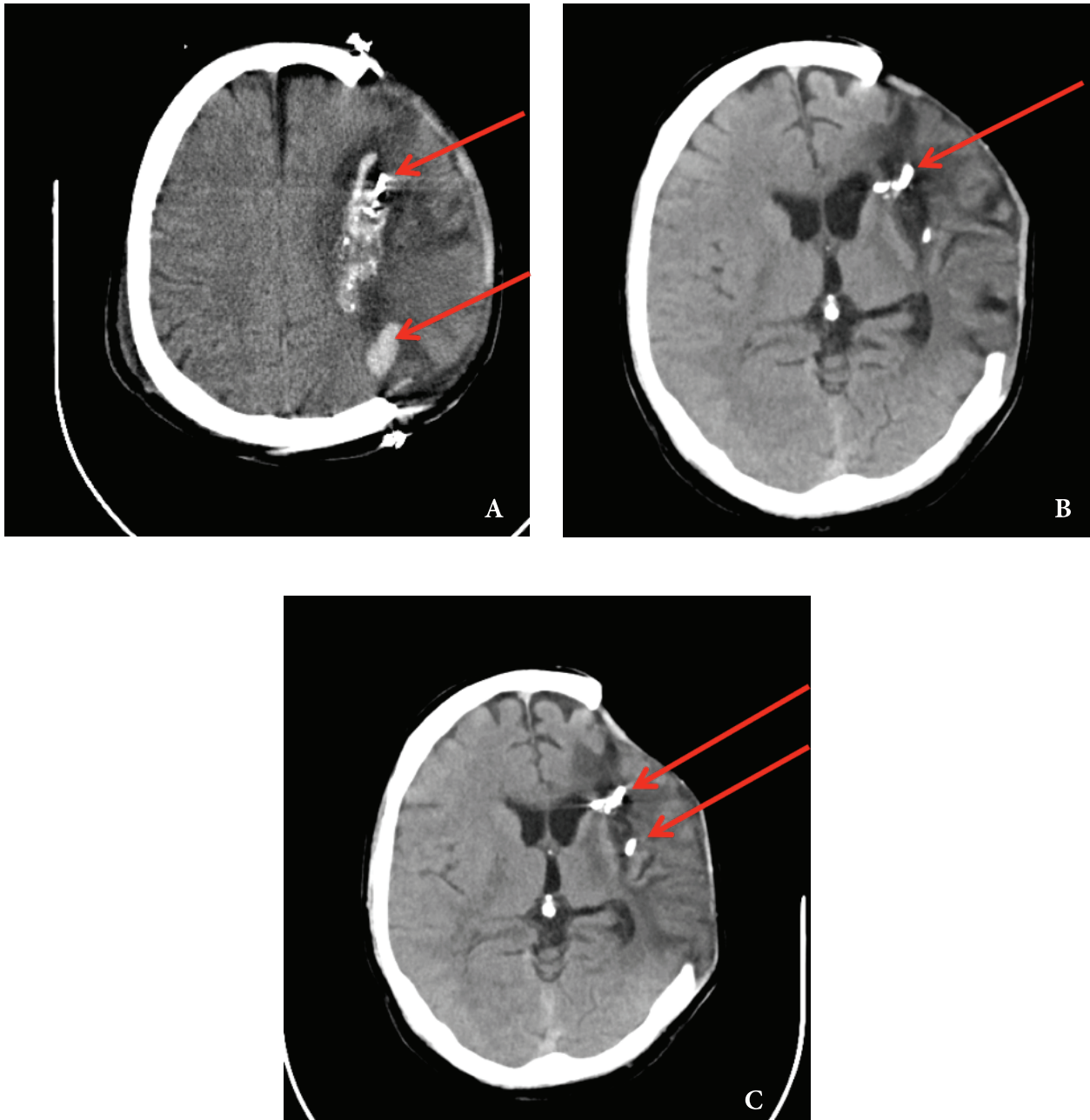


Fig. 6. Early postoperative native axial head CT scan showing a diffuse edema of the left hemisphere with a mass protruding throughout the edges of a craniectomy bone defect, and penetrating wound impact canal filled with retained foreign bodies and intracerebral hemorrhage in regression (arrows) (a). Repeated native axial brain CT performed on day 45 post injury revealing almost complete regression of intra-axial intracerebral hemorrhage with sporadic zones of post-traumatic encephalopathy and retained bone fragments (arrow), but without mass effect / midline shifting, and a slight enlargement of the left lateral ventricle frontal horn (b). Control native axial CT of the brain executed at a 6-month check-up revealing a zone of post-traumatic cerebral parenchymal loss of the left fronto-parietal area together with retained foreign bodies in the right fronto-parietal lobes (arrows) (c).

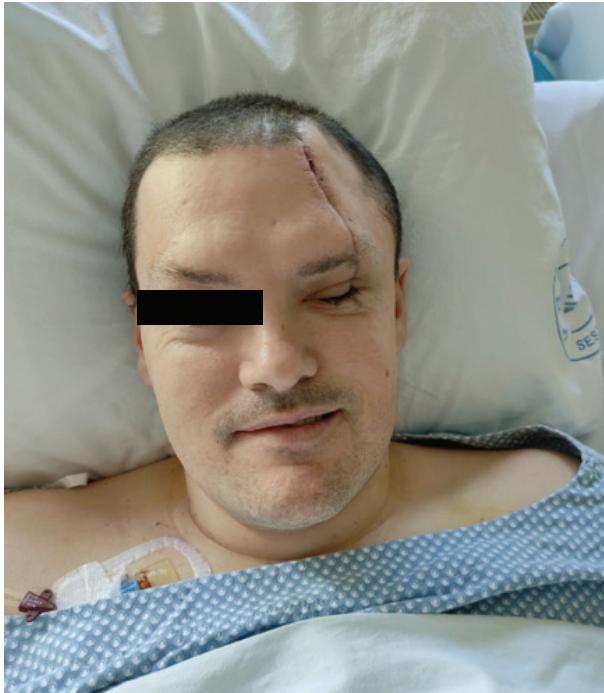

Fig. 7. Portrait of the patient before hospital discharge, showing right facial nerve central palsy (face weakness).

proved, with the patient becoming ambulatory once again.

Discussion

Although relatively rare and less destructive than missile injuries, non-missile PTBIs are dangerous and potentially lethal when vital neural and vascular endocranial structures are involved¹. Nonetheless, such injuries are generally on the rise and therefore deserve more attention¹⁸. There are injuries of the low-velocity type, having a defined impact velocity of less than 100 meters per second⁴.

Computed tomography (CT) brain scanning is an readily available and the most reliable neuroradiologic method of choice for patients with PTBI, providing rapid and detailed evaluation of bony structures and soft tissues of the orbit^{11,19}, as well as of the skull and brain. CT should be performed first to identify foreign bodies, as well as to determine their course and the extent of ocular²⁰ and brain tissue damage, while computed tomography angiography (CTA) as well as digital subtraction angiography (DSA) are recommended when there is a high suspicion of vascular injury²¹⁻²³. Magnetic resonance imaging (MRI) is generally not

recommended for the evaluation of the retained foreign bodies due to risks associated with the magnetic metal effect²³.

It is still debatable whether craniectomy or craniotomy is the best approach in patients with PTBI²⁴. Nonetheless, early surgical exploration by a multidisciplinary team is essential to attain good recovery and a favorable outcome for orbitocranial low-velocity injury^{6,11}. The current tendency is toward a less aggressive debridement of deep-seated bone and metallic fragments and a more aggressive systemic and intravitreal comprehensive prophylactic antibiotic treatment to improve the outcome^{25,26}. Retained intraorbital and intraocular foreign bodies of non-biological origin, which are not readily accessible, may be left in place safely^{9,12,27-29}. We have followed the above postulates in the management of our patient. Hence, we opted for the removal of easily accessible retained foreign bodies only, regardless of their orbital or intracranial location, while those that were deep-seated and difficult to approach were left intact. The timing of initial surgical repair in our case followed general trends in penetrating brain wounds and open-globe repair, consisting of early management and a less radical approach when retained bodies are concerned^{11,25}. Although management needs to be personalized and tailored for each patient individually, anatomic orbital structures stability has to be attained if possible. In case of a large eye trauma, reconstruction of the eyelids and fornices is crucial because of the application of future prostheses. In general, early primary repair is recommended for open globe injury, as this has been associated with reduced incidence of infection²⁶⁻²⁹.

Complications such as intracranial infections, CSF leaks, intracranial hemorrhage, pneumocephalus, cerebral edema, and post-traumatic epilepsy are usually associated with PTBI^{4,30-32}. A retained foreign body poses a risk of severe infection, including brain abscess and meningitis¹. However, reviewing the literature, it seems that intracranially retained foreign bodies and bone fragments do not increase the infection rate to a great extent^{25,33}, which suggests that it is not necessary to reoperate to extract retained fragments^{34,35}. Prophylactic systemic and intravitreal broad-spectrum antibiotics covering both gram-positive and gram-negative microorganisms following open globe injury have been found to reduce the risk of endophthalmitis^{26,36-39}. Some authors even described an uncharacteristic absence of endophthalmitis following severe globe injuries with intraocular retained

foreign bodies in a military setting^{40,41}. Following such a treatment doctrine, our patient remained infection-free during the entire hospital stay.

The risk of post-traumatic epilepsy after PTBI is also high², since the bone and metallic fragments driven into the brain and avascular glial scarring are traditionally held responsible for epileptic seizures^{32,42}. Nonetheless, our patient did not develop post-traumatic seizures so far.

The prognosis of non-missile transorbital PTBI mainly depends on the extent of oculoorbital injury and brain damage, on the course and velocity of the object fragments, as well as on interdisciplinary care. The location of eye globe perforating sites may be a significant prognostic indicator as well⁴³. Nonetheless, a comprehensive preoperative evaluation and a combined ophthalmic and neurosurgical approach are recommended to minimize morbidity⁴⁴ and to improve the prognosis.

Following early and less aggressive multidisciplinary surgical treatment and broad-spectrum antibiotic prophylaxis, as well as prolonged hospital care, our patient managed to recover to the level of upper moderate disability, having no clinical signs of postoperative complications including CNS and ocular infection and post-traumatic seizures.

In conclusion, although the presenting picture of non-missile transorbital penetrating brain injury may be discouraging, the management outcome can be satisfactory when proper clinical and radiologic evaluation are applied and simple surgical techniques are performed early. Accurate diagnosis, a less radical surgical multidisciplinary approach, and successful postoperative management are the prerequisites for achieving a favorable outcome in PTBI.

Lastly, we would like to emphasize certain limitations stemming from its case report form. The aim of this paper was not to establish firm recommendations for the management of such a demanding injury, but rather to present our experience in emergency handling of PTBI and to discuss some controversies in contemporary treatment. Clearly, further research in a form of systematic reviews or meta-analyses is needed to support our conclusion.

References

1. Young M, Putty M, Finneran MM, Johnson R, Schaible K, Farhat H. Multidisciplinary management of low-velocity nonmissile penetrating head injuries. *Cureus*. 2020;12(3):e7388. doi: 10.7759/cureus.7388.
2. Kazim SF, Shamim MS, Tahir MZ, Enam SA, Waheed S. Management of penetrating brain injury. *J Emerg Trauma Shock*. 2011;4(3):395-402. doi:10.4103/0974-2700.83871.
3. Xue H, Zhang WT, Wang GM, Shi L, Zhang YM, Yang HF. Transorbital nonmissile penetrating brain injury: Report of two cases. *World J Clin Cases*. 2020;8(2):471-8. doi: 10.12998/wjcc.v8.i2.471.
4. Li XS, Yan J, Liu C, Luo Y, Liao XS, Yu L, Xiao SW. Non-missile penetrating head injuries: surgical management and review of the literature. *World Neurosurg*. 2017;98:873.e9-873.e25. doi: 10.1016/j.wneu.2016.11.125.
5. Balasubramanian C, Kaliaperumal C, Jadun CK, Dias PS. Transorbital intracranial penetrating injury – an anatomical classification. *Surg Neurol*. 2009;71(2):238-40. doi: 10.1016/j.surneu.2007.07.050.
6. Mzimiri JM, Li J, Bajawi MA, Lan S, Chen F, Liu J. Orbitocranial low-velocity penetrating injury: a personal experience, case series, review of the literature, and proposed management plan. *World Neurosurg*. 2016;87:26-34. doi: 10.1016/j.wneu.2015.12.063.
7. Pieramici DJ, Sternberg P Jr, Aaberg TM Sr, Bridges WZ Jr, Capone A Jr, Cardillo JA, et al.; The Ocular Trauma Classification Group. A system for classifying mechanical injuries of the eye (globe). *Am J Ophthalmol*. 1997;123(6):820-831. doi: 10.1016/s0002-9394(14)71132-8.
8. Colyer MH, Chun DW, Bower KS, Dick JS, Weichel ED. Perforating globe injuries during Operation Iraqi Freedom. *Ophthalmology*. 2008;115(11):2087-2093.e2. doi: 10.1016/j.ophtha.2008.05.013.
9. Finkelstein M, Legmann A, Rubin PA. Projectile metallic foreign bodies in the orbit: a retrospective study of epidemiologic factors, management, and outcomes. *Ophthalmology*. 1997;104(1):96-103. doi:10.1016/S0161-6420(97)30355-8.
10. Iqbal M, Charteris DG, Cooling RJ, Mackintosh GI. Conservative management of double penetrating ocular injuries. *Eye (Lond)*. 2000;14(pt 2):249-251. doi: 10.1038/eye.2000.67.
11. Jung HC, Lee SY, Yoon CK, Park UC, Heo JW, Lee EK. Intraocular foreign body: diagnostic protocols and treatment strategies in ocular trauma patients. *J Clin Med*. 2021;10(9):1861. doi: 10.3390/jcm10091861.
12. Li E, Chamber CB. Diseases of eyelids and orbit. *Med Clin North Am*. 2021;105:551-62. doi: 10.1016/j.mcna.2021.02.007.
13. Martin DF, Meredith TA, Topping TM, Sternberg P, Kaplan HJ. Perforating (through-and-through) injuries of the globe. Surgical results with vitrectomy. *Arch Ophthalmol*. 1991;109(7):951-6. doi: 10.1001/archophth.1991.01080070063036.
14. Mohamed AA. Vitrectomy in double-perforation gunshot injury. *Clin Ophthalmol*. 2013;7:2219-24. doi: 10.2147/OPTH.S46804.
15. Ramsay RC, Cantrill HL, Knobloch WH. Vitrectomy for double penetrating ocular injuries. *Am J Ophthalmol*. 1985;100(4):586-9. doi: 10.1016/0002-9394(85)90686-5.
16. Vatne HO, Syrdalen P. Vitrectomy in double perforating eye injuries. *Acta Ophthalmol (Copenh)*. 1985;63(5):552-6. doi: 10.1111/j.1755-3768.1985.tb05244.x.
17. Weichel ED, Bower KS, Colyer MH. Chorioretinectomy for perforating or severe intraocular foreign body injuries. *Graef*

- fes Arch Clin Exp Ophthalmol. 2010;248(3):319-30. doi: 10.1007/s00417-009-1236-x.
18. Lan Z, Richard SA, Ma L, Yang C. Nonmissile anterior skull-base penetrating brain injury: experience with 22 patients. *Asian J Neurosurg.* 2018;13(3):742-8. doi: 10.4103/ajns.AJNS_36_18.
 19. Betts AM, O'Brien WT, Davies BW, Youssef OH. A systematic approach to CT evaluation of orbital trauma. *Emerg Radiol.* 2014;21(5):511-31. doi: 10.1007/s10140-014-1221-5.
 20. Patel SN, Langer PD, Zarbin MA, Bhagat N. Diagnostic value of clinical examination and radiographic imaging in identification of intraocular foreign bodies in open globe injury. *Eur J Ophthalmol.* 2012;22(2):259-68. doi: 10.5301/EJO.2011.8347.
 21. Sweeney JM, Lebovitz JJ, Eller JL, Coppens JR, Bucholz RD, Abdulrauf SI. Management of nonmissile penetrating brain injuries: a description of three cases and review of the literature. *Skull Base Rep.* 2011;1(1):39-46. doi: 10.1055/s-0031-1275257.
 22. Zyck S, Toshkezi G, Krishnamurthy S, Carter DA, Siddiqui A, Hazama A, et al. Treatment of penetrating nonmissile traumatic brain injury. Case series and review of the literature. *World Neurosurg.* 2016;91:297-307. doi: 10.1016/j.wneu.2016.04.012.
 23. Pinto A, Brunese L, Daniele S, Faggian A, Guarnieri G, Muto M, et al. Role of computed tomography in the assessment of intraorbital foreign bodies. *Semin Ultrasound CT MR.* 2012;33(5):392-5. doi: 10.1053/j.sult.2012.06.004.
 24. Haddad FS. Nature and management of penetrating head injuries during the civil war in Lebanon. *Can J Surg.* 1978;21:233-40.
 25. Brandvold B, Levi L, Feinsod M, George ED. Penetrating craniocerebral injuries in the Israeli involvement in the Lebanese conflict, 1982-1985. Analysis of a less aggressive surgical approach. *J Neurosurg.* 1990;72:15-21.
 26. Ahmed Y, Schimel AM, Pathengay A, Colyer MH, Flynn HW. Endophthalmitis following open-globe injuries. *Eye (Lond).* 2012;26(2):212-7. doi: 10.1038/eye.2011.313.
 27. Callahan AB, Yoon MK. Intraorbital foreign bodies: retrospective chart review and review of literature. *Int Ophthalmol Clin.* 2013;53(4):157-65. doi: 10.1097/IIO.0b013e-3182a12b55.
 28. Fulcher TP, McNab AA, Sullivan TJ. Clinical features and management of intraorbital foreign bodies. *Ophthalmology.* 2002;109(3):494-500. doi: 10.1016/S0161-6420(01)00982-4.
 29. Ho VH, Wilson MW, Fleming JC, Haik BG. Retained intraorbital metallic foreign bodies. *Ophthalm Plast Reconstr Surg.* 2004;20(3):232-6. doi: 10.1097/01.IOP.0000129014.94384.e6.
 30. Chowdhury FH, Haque MR, Hossain Z, Chowdhury NK, Alam SM, Sarker MH. Nonmissile penetrating injury to the head: experience with 17 cases. *World Neurosurg.* 2016;94:529-43. doi: 10.1016/j.wneu.2016.06.062.
 31. Turbin RE, Maxwell DN, Langer PD, Frohman LP, Hubbi B, Wolansky L, et al. Patterns of transorbital intracranial injury: a review and comparison of occult and non-occult cases. *Surv Ophthalmol.* 2006;51(5):449-460. doi: 10.1016/j.survophthal.2006.06.008.
 32. Adeloye A, Odeku EL. Epilepsy after missile wounds of the head. *J Neurol Neurosurg Psychiatr.* 1971;34:98-103.
 33. Aarabi B. Causes of infection in penetrating wounds in the Iran-Iraq war. *Neurosurgery.* 1989;25:923-6.
 34. Splavski B, Vranković Đ, Šarić G, Saftić R, Maksimović Z, Bajek G, et al. Early surgery and other indicators influencing the outcome of war missile skull base injuries. *Surg Neurol.* 1998;50(3):194-9. doi: 10.1016/s0090-3019(98)00047-0.
 35. Splavski B, Šišljagić V, Perić LJ, Vranković Đ, Ebling Z. Intracranial infection as a common complication following war missile skull base injury. *Injury.* 2000;31(4):233-7. doi: 10.1016/S0020-1383(99)00273-9.
 36. Abouammoh MA, Al-Mousa A, Gogandi M, Al-Mezaine H, Osman E, Alsharidah AM, et al. Prophylactic intravitreal antibiotics reduce the risk of post-traumatic endophthalmitis after repair of open globe injuries. *Acta Ophthalmol.* 2018;96(3):e361-e365. doi: 10.1111/aos.13531.
 37. Durrani AF, Zhao PY, Zhou Y, Huvarud M, Azzouz L, Keil JM, et al. risk factors for endophthalmitis following open globe injuries: a 17-year analysis. *Clin Ophthalmol.* 2021;15:2077-87. doi: 10.2147/OPHTH.S307718.
 38. Liang Y, Liang S, Liu X, Liu D, Duan J. Intraocular foreign bodies: clinical characteristics and factors affecting visual outcome. *J Ophthalmol.* 2021;2021:9933403. doi: 10.1155/2021/9933403.
 39. Zhang Y, Zhang MN, Jiang CH, Yao Y, Zhang K. Endophthalmitis following open globe injury. *Br J Ophthalmol.* 2010;94(1):111-4. doi: 10.1136/bjo.2009.164913.
 40. Colyer MH, Weber ED, Weichel ED, Dick JS, Bower KS, Ward TP, et al. Delayed intraocular foreign body removal without endophthalmitis during Operations Iraqi Freedom and Enduring Freedom. *Ophthalmology.* 2007;114(8):1439-47. doi: 10.1016/j.ophtha.2006.10.052.
 41. Thach AB, Ward TP, Dick JS II, Bauman WC, Madigan WP Jr, Goff MJ, et al. Intraocular foreign body injuries during Operation Iraqi Freedom. *Ophthalmology.* 2005;112:1829-33. doi: 10.1016/j.ophtha.2005.04.024.
 42. Caveness WF, Meirowsky AM, Rish BL, Mohr JP, Kistler JP, Dillon JD, et al. The nature of posttraumatic epilepsy. *J Neurosurg.* 1979;50:545-53.
 43. Cruvinel Isaac DL, Ghanem VC, Nascimento MA, Torigoe M, Kara-José N. Prognostic factors in open globe injuries. *Ophthalmologica.* 2003;217(6):431-5. doi: 10.1159/000073075.
 44. Gönül E, Erdoğan E, Taşar M, Yetişer S, Akay KM, Düz B, et al. Penetrating orbitocranial gunshot injuries. *Surg Neurol.* 2005;63(1):24-30. doi: 10.1016/j.surneu.2004.05.043.

Sažetak

OPERACIJSKO LIJEČENJE PENETRIRAJUĆE RANE MOZGA I PRIDRUŽENE PERFORIRAJUĆE OZLJEDE OKA UZROKOVANE METALNIM OBJEKTOM MALE BRZINE KRETANJA: PRIKAZ SLUČAJA I UVID U LITERATURU

B. Splavski, R. Iveković, I. Bošnjak, B. Splavski Jr, A. Rotim i K. Rotim

Penetrirajuća ozljeda mozga i pridružena perforirajuća ozljeda oka uzrokovana stranim tijelima male brzine kretanja po život je opasno, hitno kirurško stanje koje predstavlja veliki izazov u kirurškoj opskrbi, kao i tešku podvrstu mirnodopske ozljede mozga, koja je relativno rijetka u civilnoj populaciji. Optimalno liječenje ovakve ozljede i nadalje je dvojbeno te zahtijeva potpuno razumijevanje patofiziologije njezinog razvoja, kao i multidisciplinarni ekspertni pristup. U ovom radu donosimo prikaz slučaja penetrirajuće ozljede mozga i pridružene perforirajuće ozljede oka te uvid u recentnu literaturu, kako bi podrobno raspravili o ovoj zahtjevnoj i složenoj višeorganskoj ozljedi. Muškarac u dobi od 39 godina zadobio je transorbitalnu penetrirajuću ozljedu mozga i perforirajuću okularnu ozljedu zbog čega je podvrgnut hitnom kirurškom liječenju kako bi se uklonilo oštar metalni objekt zaostalo u području lijevog tjemenog režnja. Nakon provedene žurne dijagnostike, odmah je učinjena dekompresijska ljevostrana fronto-temporo-parijetalna karniektomija te je uspješno uklonjeno zaostalo metalno strano tijelo (odsječak cirkularne pile), nakon čega je po oftalmologu učinjena primarna opskrba ozljede lijeve očne jabučice i rekonstrukcija vjeđa i forniksa kroz slojeve lijevo. Profilaktička primjena antibiotika širokoga spektra provedena je kako bi se spriječio nastanak infekcijskih komplikacija. Rani poslijeoperacijski oporavak bio je zadovoljavajući. Bolesnik je otpušten iz bolnice 45. dan nakon ozljede s umjerenom motoričkom slabošću desnih udova, istostranom centralnom facioparezom i blagom motoričkom disfazijom. Vid na lijevome oku trajno je i potpuno izgubljen.

Zaključujemo kako liječenje mirnodopske transorbitalne penetrirajuće ozljede mozga može biti uspješno ako je provedena pravodobna primjerena klinička i radiološka provjera i ako je primijenjen ogovarajući manje radikalni kirurški pristup. Multidisciplinarna opskrba preduvjet je postizanja povoljnog učinka liječenja.

Ključne riječi: Penetrirajuća ozljeda mozga, transorbitalna; Perforirajuća ozljeda oka; Mirnodopska ozljeda projektilom male brzine kretanja; Zaostala strana tijela; Kirurško liječenje; Uspješnost liječenja