



Spontaneous resolution of an intrapericardial thrombus as a complication of pericardiocentesis in a neonate

Brief Report

Cite this article: Crombez J, Dewals W, Muiño Mosquera L, Martens T, Van Damme K, and Bruyndonckx L (2024). Spontaneous resolution of an intrapericardial thrombus as a complication of pericardiocentesis in a neonate. *Cardiology in the Young*, page 1 of 3. doi: [10.1017/S1047951123004535](https://doi.org/10.1017/S1047951123004535)

Received: 28 September 2023

Revised: 19 December 2023

Accepted: 25 December 2023



Keywords:

Umbilical venous catheter; pleural effusion; pericardial effusion; pericardiocentesis; intrapericardial thrombus; case report

Corresponding author:

Joy Crombez; Email: joy.crombez@uza.be

KVD and LB both contributed equally.

Joy Crombez¹ , Wendy Dewals², Laura Muiño Mosquera³ , Thomas Martens⁴, Karlijn Van Damme^{1,5} and Luc Bruyndonckx^{2,5}

¹Department of Neonatology, Antwerp University Hospital, Edegem, Belgium; ²Department of Paediatric Cardiology, Antwerp University Hospital, Edegem, Belgium; ³Department of Paediatric Cardiology, Ghent University Hospital, Ghent, Belgium; ⁴Department of Cardiac Surgery, Ghent University Hospital, Ghent, Belgium and ⁵Laboratory of Experimental Medicine and Paediatrics, University of Antwerp, Antwerp, Belgium

Abstract

We present the case of a premature neonate with pericardial effusion secondary to extravasation of total parenteral nutrition from a mispositioned/migrated umbilical venous catheter. Emergency pericardiocentesis was complicated by an intrapericardial thrombus, which was managed conservatively with spontaneous resolution within 24 hours. This case illustrates that the rare complication of an intrapericardial thrombus after pericardiocentesis can be successfully managed conservatively with close monitoring in haemodynamically stable paediatric patients.

Case report

We present the case of a neonate born at 32 + 4 weeks by planned caesarean section because of intra-uterine growth restriction. Neonatal stabilisation with inflations and ventilations was required to achieve adequate breathing at minute 10 (Apgar-score 3/5/7 at 1–5–10 minutes, respectively). Nasal continuous positive airway pressure was started because of neonatal respiratory distress syndrome, and the patient was stably admitted to the neonatal ICU. Clinical examination revealed an asymmetric intra-uterine growth restriction with a birthweight of 900 g (−2.51 standard deviations) and a head circumference of 28 centimetres (−1.28 standard deviations), a single umbilical artery, and a hypospadias. Single nucleotide polymorphism array and trio-based whole-exome sequencing were normal. An umbilical venous and arterial catheter were inserted according to the Dunn method. Blood could easily be aspirated. After chest and abdominal X-ray suggested correct positioning of both catheter tips (Supplementary Figure S1A–B), total parenteral nutrition was started. At 39 hours of life, the infant developed increasing respiratory distress with bilateral reduced air entry on clinical examination and FiO₂ up to 1.0. A chest X-ray showed bilateral opacities (Supplementary Figure S1C). The patient was intubated and mechanically ventilated. Surfactant was administered intratracheally, resulting in temporary stabilisation of the respiratory condition. Within four hours, respiratory distress recurred, with increasing oxygen requirement and haemodynamic compromise. Chest ultrasound revealed bilateral pleural and pericardial effusion, while the umbilical venous catheter tip could not be visualised and blood could no longer be aspirated via the catheter. Because of suspicion of extravasation of total parenteral nutrition through the umbilical venous line, total parenteral nutrition administration was stopped and the catheter removed immediately. Due to impending hypovolemic shock, peripheral venous access was obtained, and a normal saline bolus was administered followed by an emergency pericardiocentesis by subxiphoid approach under ultrasound guidance. During this procedure, 2 mL of a serous bloody fluid was aspirated. Biochemical analysis of the aspirated fluid showed high glucose (1017 mg/dL) and triglycerides (597 mg/dL), confirming the presence of total parenteral nutrition in the pericardial space. The patient's clinical condition improved after pericardiocentesis with a decrease in tachycardia and normalisation of arterial blood pressure. Echocardiography showed minor residual pericardial effusion but a new intrapericardial thrombus (15 × 8 mm) adjacent to the right ventricle, without haemodynamic compromise (Fig. 1a–b; Supplementary Video S1). The patient was transferred to a paediatric cardiac surgery centre to allow pericardiotomy and thrombus removal, if necessary. Chest ultrasound upon arrival demonstrated stable sizes of the pericardial thrombus and effusion, as well as the pleural effusion. Because of the absence of signs of impending cardiac tamponade and surgical risk associated with a birthweight of 900 g, a conservative approach with close monitoring of vital signs (e.g. continuous arterial blood pressure measurement via arterial umbilical catheter, heart rate, and oxygen saturation) and serial imaging was adopted. Cardiac ultrasound after six hours

© The Author(s), 2024. Published by Cambridge University Press. This is an Open Access article, distributed under the terms of the Creative Commons Attribution licence (<http://creativecommons.org/licenses/by/4.0/>), which permits unrestricted re-use, distribution and reproduction, provided the original article is properly cited.



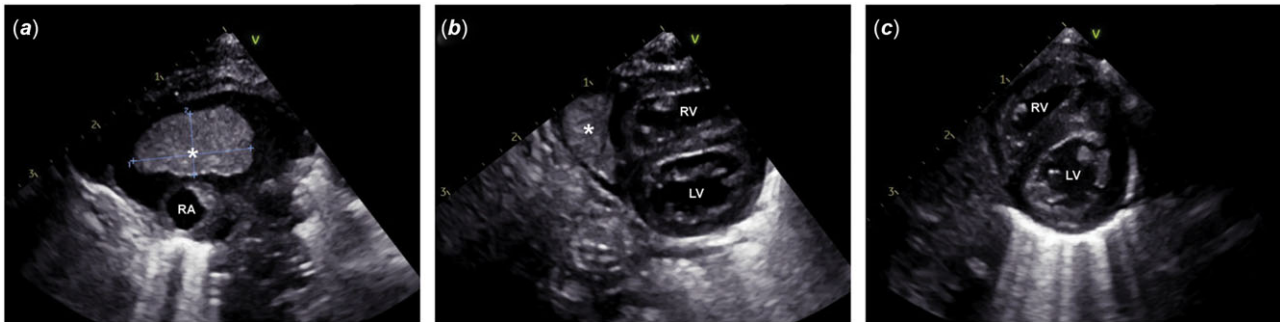


Figure 1. (a). Echocardiography performed after pericardiocentesis demonstrates the intrapericardial thrombus (asterisk) with a maximal diameter of approximately 8 × 15 mm and a minor residual pericardial effusion. (b). Parasternal short-axis view shows the intrapericardial thrombus (asterisk) adjacent to the right ventricle. (c). Repeat echocardiography after retransfer shows complete resolution of the intrapericardial thrombus and pericardial effusion. RA = right atrium, RV = right ventricle, LV = left ventricle.

showed a spontaneous decrease of the pleural effusion and stable size of the pericardial thrombus and effusion. Hence, close monitoring was continued without further interventions. One day after transfer, the pleural and pericardial effusion, as well as the pericardial thrombus, had completely resolved. Four days after initial transfer, the patient was retransferred to our centre. Echocardiography could no longer visualise any residual pericardial thrombus (Fig. 1c). Our patient was successfully weaned from mechanical ventilation and switched back to nasal continuous positive airway pressure and remained haemodynamically stable throughout the rest of his stay in the neonatal ICU.

Discussion

Umbilical venous catheters are commonly used for central venous access in premature and severely ill neonates due to their ease of placement. However, umbilical venous catheters may be associated with important complications in up to 13.3–20.3% of patients, mainly related to incorrect position (e.g. extravasation and cardiac tamponade) and long catheter dwell times (e.g. thrombi, bloodstream infections).¹

In our case, the patient presented with acute respiratory distress approximately two days after umbilical venous catheter placement, and thoracic ultrasound revealed pericardial and bilateral pleural effusions. His clinical deterioration was attributed to incorrect positioning of the umbilical venous catheter. Although catheter tip position appeared to be correct on chest radiography carried out after placement, a meta-analysis demonstrated chest X-ray to be a poor predictor of umbilical venous catheter tip position, when compared to ultrasound (sensitivity 90%, specificity 82%).² Nevertheless, even correct initial positioning does not preclude migration of the catheter tip, for example, due to drying and thus shortening of the umbilical cord remnant. A prospective observational study revealed catheter tip migration to occur in almost half of the infants with an umbilical venous catheter in situ.³ In our case, umbilical venous catheter tip appeared to have migrated upwards, with the catheter tip projecting above the diaphragm on control chest X-ray on day 2 of life (Supplementary Figure SIC).

A recent meta-analysis showed an incidence of 3.8% of central venous catheter-related pericardial effusion, similar to the incidence in a large cohort of umbilical venous catheters.^{1,4} Pericardial effusion may result from direct perforation of the myocardium during catheter placement, from necrosis of the myocardial wall by repeated contact with the catheter tip in case of catheter malposition or migration or from endothelial osmotic injury. Given the potentially rapid progression to cardiac tamponade, high mortality rates up to

75% in pericardial effusions related to central venous catheters have been reported.⁵ Timely pericardiocentesis has been shown to successfully reduce progression to cardiogenic shock and mortality.⁴ In our case, emergency pericardiocentesis was performed because of haemodynamic instability, yet this was complicated by an intrapericardial thrombus. Although a life-saving procedure, pericardiocentesis can cause life-threatening complications, like intrapericardial haemorrhage or thrombus formation.⁶ Several case reports in adults, but not in neonates, have described the appearance of an intrapericardial thrombus as a homogeneous echogenic mass with definite margins in the pericardium on echocardiography after pericardiocentesis,^{7–9} often resulting in haemodynamic instability and need for emergency pericardiotomy.¹⁰ Our patient was transferred to a paediatric cardiac surgery centre for potential pericardiotomy and thrombus removal, but was eventually successfully managed conservatively given his stable haemodynamic situation after pericardiocentesis and no further progression of the thrombus on follow-up cardiac ultrasound imaging.

Our case report describes the spontaneous resolution of a pericardiocentesis-related intrapericardial thrombus in a neonate. This rare case highlights that clinically stable paediatric patients suffering from pericardiocentesis-related intrapericardial thrombi can be managed conservatively, thereby avoiding pericardiotomy-related complications. We recommend transferring these patients to a paediatric cardiac surgery centre, allowing rapid surgical intervention in case of clinical deterioration. In addition, our case highlights once again the potential complications of umbilical catheters. We recommend follow-up of catheter tip position in case of longer dwell times and a high index of suspicion for catheter-related complications in the event of clinical deterioration.

Supplementary material. The supplementary material for this article can be found at <https://doi.org/10.1017/S1047951123004535>.

Author contribution. The first draft of the manuscript was written by Joy Crombez, and all authors commented on subsequent versions of the manuscript. All authors read and approved the final manuscript.

Financial support. This research received no specific grant from any funding agency, commercial, or not-for-profit sectors.

Competing interests. None.

Ethical standards. This article does not contain any studies with human participants or animals performed by any of the authors. Informed consent of the patient's parents was obtained.

References

1. Levit OL, Shabanova V, Bizzarro MJ. Umbilical catheter-associated complications in a level IV neonatal intensive care unit. *J Perinatol* 2020; 40: 573–580.
2. Cao J, Zhang Y, Yin Y, Liu Y. Accuracy of chest radiography compared to ultrasound for positioning the umbilical venous catheter in neonates: a meta-analysis and systematic review. *J Vasc Access* 2023; 24: 1051–1060.
3. Franta J, Harabor A, Soraisham AS. Ultrasound assessment of umbilical venous catheter migration in preterm infants: a prospective study. *Arch Dis Child Fetal Neonatal Ed* 2017; 102: F251–5.
4. Wang J, Wang Q, Liu Y, et al. The incidence and mortality rate of catheter-related neonatal pericardial effusion: a meta-analysis. *Medicine (United States)* 2022; 101: E32050.
5. Nowlen TT, Rosenthal GL, Johnson GL, Tom DJ, Vargo TA. Pericardial effusion and tamponade in infants with central catheters. *Pediatrics* 2002; 110: 137–142.
6. Kumar R, Sinha A, Lin M, et al. Complications of pericardiocentesis: a clinical synopsis. *Int J Crit Illn Inj Sci* 2015; 5: 206.
7. Lin CS, Jan YI, Chen HY, Hou SH, Kuo CC. Two-dimensional echocardiographic detection of pericardiocentesis-induced intrapericardial thrombus. *Chest* 1984; 86: 787–789.
8. Iliceto S, Antonelli G, Sorino M, Calabrese P, Biasco G, Rizzon P. Two-dimensional echocardiographic recognition of complications of cardiac invasive procedures. *Am J Cardiol* 1984; 53: 846–848.
9. Schuster AH, Nanda NC. Pericardiocentesis induced intrapericardial thrombus: detection by two-dimensional echocardiography. *Am Heart J* 1982; 104: 308–311.
10. Accadia M, Di Maio M, Ingo R, et al. Pericardial thrombus and cardiac tamponade after pericardiocentesis with intact heart walls. *Echocardiography* 2019; 36: 803–805.