



# Psoriatic Dactylitis with Onychodystrophy

**IMAGES IN CLINICAL  
RADIOLOGY**

**LUCAS VAN HOUTVEN** 

**FILIP M. VANHOENACKER** 

\*Author affiliations can be found in the back matter of this article

**]**u[ubiquity press

## ABSTRACT

*Teaching point:* Magnetic resonance imaging (MRI) and ultrasound may be useful to assess the extent of onychodystrophy associated with psoriatic dactylitis by showing nail bed thickening, matrix changes, and vascularity indicative of active inflammation.

## CORRESPONDING AUTHOR:

**Filip M. Vanhoenacker**

AZ Sint-Maarten Mechelen and  
University Antwerp and Ghent,  
Liersesteenweg 435, 2800  
Mechelen, Belgium

[filip.vanhoenacker@telenet.be](mailto:filip.vanhoenacker@telenet.be)

---

## KEYWORDS:

Psoriasis, dactylitis, ultrasound,  
MRI

## TO CITE THIS ARTICLE:

Van Houtven L, Vanhoenacker FM. Psoriatic Dactylitis with Onychodystrophy. *Journal of the Belgian Society of Radiology*. 2024; 108(1): 38, 1–3. DOI: <https://doi.org/10.5334/jbsr.3559>

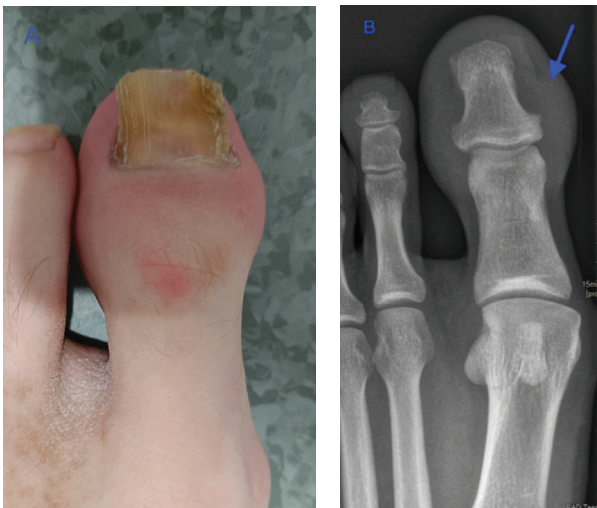## CASE PRESENTATION

A 31-year-old patient with known psoriasis presented with swelling, redness, and nail dystrophy of the left great toe (Figure 1A). Conventional radiography (CR) showed subtle irregular delineated bone proliferation medially at the distal phalanx (Figure 1B, arrow) and non-specific soft tissue swelling.

Magnetic resonance imaging (MRI) revealed bone marrow edema at the distal phalanx on fat-suppressed (FS) T2-Weighted (WI) (Figure 2A, arrow). FS T1-WI after gadolinium contrast administration showed bone marrow enhancement of the distal phalanx (Figure 2B, blue arrow) and thickening and enhancement of the nail bed and underneath the nailbed (red arrow).

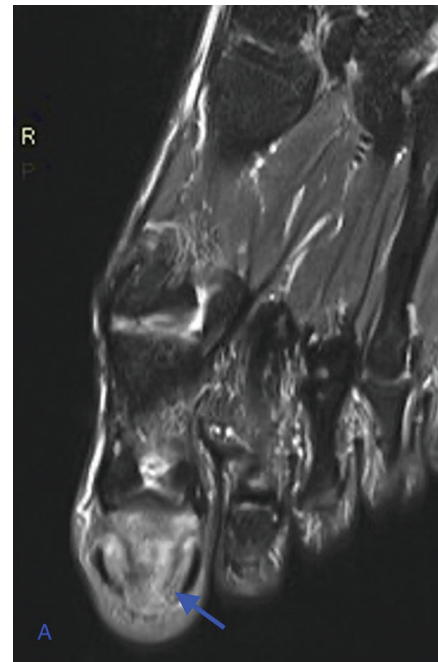
Subsequent ultrasound (US) confirmed increased subungual power Doppler flow signals (Figure 3, arrows), indicative of active inflammation.

Based on the combination of clinical history and imaging findings, the diagnosis of psoriatic dactylitis with onychodystrophy was made.

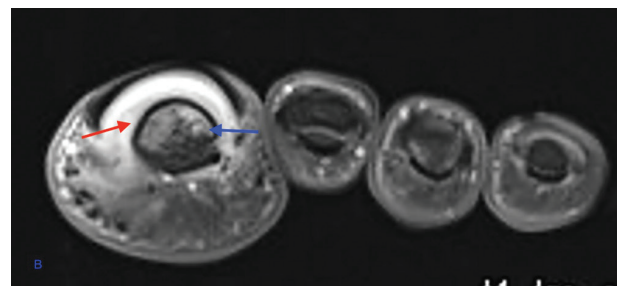


**Figure 1 A** Clinical picture of the left hallux showing swelling, redness, and nail dystrophy of the left great toe.

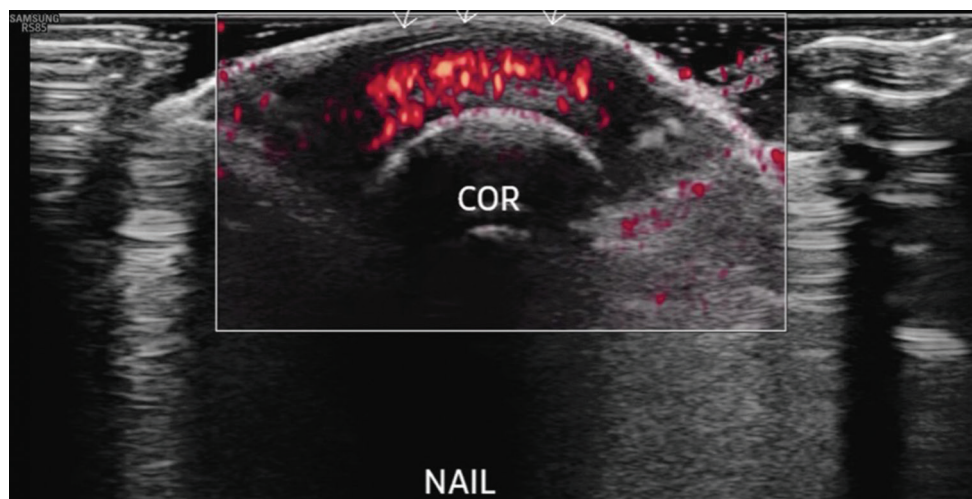
**Figure 1 B** Conventional radiograph of the left foot shows non-specific soft tissue swelling and subtle irregular delineated bone proliferation medially at the distal phalanx (arrow).



**Figure 2 A** Axial FS T2-WI MRI shows bone marrow edema at the distal phalanx (arrow).



**Figure 2 B** Coronal FS T1-WI after gadolinium contrast administration shows bone marrow enhancement of the distal phalanx (blue arrow) and enhancement of the nail bed (red arrow).



**Figure 3** Transverse ultrasound shows increased subungual power Doppler signal.

## COMMENT

Psoriatic onychodystrophy is a condition that may be associated with skin psoriasis and psoriatic arthritis (PsA). Clinically, it consists of nail abnormalities such as pitting, onycholysis, subungual hyperkeratosis, and discoloration.

The hallux is a site of predilection.

On MRI, the nail matrix and nail bed are thickened, with enhancement indicating inflammation. Fluid-sensitive sequences such as FS T2-WI and Short Tau Inversion Recovery (STIR) sequences reveal high signal within the nail bed and matrix. Bone marrow edema within the distal phalanx indicates associated psoriatic dactylitis, in keeping with more advanced disease. Diffuse swelling of the digits due to soft tissue inflammation and joint effusion, commonly referred to as “sausage digits,” can be appreciated on CR and MRI as well.

Periostitis, erosions, and bone proliferations are other well-known signs of PsA in CR [1].

US demonstrates thickening at the nail bed and underneath the nail with increased power Doppler signal, indicative of active inflammation. The US is particularly useful for monitoring the response to treatments.

Treatment for psoriatic onychopathy and dactylitis varies based on disease severity. Topical treatments suffice for mild cases, while systemic therapies are reserved for severe presentations. Early intervention is crucial to preventing disease progression.

In conclusion, the radiologist should be aware of nail abnormalities associated with psoriasis and psoriatic dactylitis. The clues to the diagnosis are the history of (cutaneous) psoriasis, typical nail abnormalities, and awareness of the imaging findings of psoriatic onychodystrophy.

## COMPETING INTERESTS

The authors have no competing interests to declare.

## AUTHOR AFFILIATIONS

**Lucas Van Houtven**  [orcid.org/0000-0003-3259-2015](https://orcid.org/0000-0003-3259-2015) AZ Sint-Maarten Mechelen and University Antwerp

**Filip M. Vanhoenacker**  [orcid.org/0000-0002-7253-1201](https://orcid.org/0000-0002-7253-1201) AZ Sint-Maarten Mechelen and University Antwerp and Ghent, Liersessesteeweg 435, 2800 Mechelen, Belgium

## REFERENCE

1. **Bethapudi S, Halstead J, Ash Z, McGonagle D, Grainger AJ.** Psoriatic onycho pachydermo periostitis (POPP). *Skelet Radiol.* 2014;43(3):373–374. DOI: <https://doi.org/10.1007/s00256-013-1682-8>.

---

### TO CITE THIS ARTICLE:

Van Houtven L, Vanhoenacker FM. Psoriatic Dactylitis with Onychodystrophy. *Journal of the Belgian Society of Radiology.* 2024; 108(1): 38, 1–3. DOI: <https://doi.org/10.5334/jbsr.3559>

**Submitted:** 27 February 2024    **Accepted:** 22 March 2024    **Published:** 11 April 2024

### COPYRIGHT:

© 2024 The Author(s). This is an open-access article distributed under the terms of the Creative Commons Attribution 4.0 International License (CC-BY 4.0), which permits unrestricted use, distribution, and reproduction in any medium, provided the original author and source are credited. See <https://creativecommons.org/licenses/by/4.0/>.

*Journal of the Belgian Society of Radiology* is a peer-reviewed open access journal published by Ubiquity Press.