

CASE REPORT

Salmonella hvittingfoss, a rare case of postoperative endometritis: A case report and review of the literature

Sarah Baïli  | Sascha Vereeck | Yves Jacquemyn 

Department of Obstetrics and Gynaecology, Antwerp University Hospital UZA, Edegem Belgium and Antwerp University UA, ASRARC and Global Health Institute, Antwerp, Belgium

Correspondence

Sarah Baïli, Department of Obstetrics and Gynaecology, Antwerp University Hospital UZA, Edegem and Antwerp University UA, ASRARC and Global Health Institute, Antwerp, Drie Eikenstraat 655, 2650 Edegem, Belgium.
Email: sarah.baïli@hotmail.com

Key clinical message

Microbiological diagnosis of endometritis and appropriate antibiotic treatment based on the antibiogram is essential. We should remain critical about the potential etiologic pathogens, especially when traveling abroad and during pregnancy. Therefore, it is essential to obtain cultures prior to the administration of antibiotics.

Abstract

We present a case of postoperative endometritis in a patient with incomplete miscarriage, who underwent dilatation and curettage. Blood, cervical and stool cultures revealed the presence of *Salmonella hvittingfoss*. Gynecological postoperative infections with *Salmonella* spp. are rare according to the current literature.

KEYWORDS

dilatation and curettage, endometritis, miscarriage, postoperative, salmonella

1 | INTRODUCTION

Salmonella species can be divided into two groups: typhoid (typhi/paratyphi) and non-typhoid. The former leads to enteric fever, a severe, potentially life-threatening disease. This remains a major public health issue, particularly in developing areas.¹ The latter consists of numerous subtypes, causing salmonellosis, which is characterized by generally mild and self-limiting gastrointestinal symptoms. These bacteria are usually acquired through ingestion of contaminated food or water, predominantly eggs, egg-based products, and poultry.² Salmonellosis is the second most frequent cause of gastrointestinal infections in the European Union, with 60,494 laboratory-detected cases reported in 2021.³

Occasionally, a non-typhoidal *Salmonella* infection can become invasive and may result in extra-intestinal complications, including meningitis, pneumonia, encephalopathy, endocarditis, empyema, and abscessation.^{2,4} Invasive infections are more commonly seen in patients

with an impaired immune system, among others due to immunosuppressive medication, immunodeficiency, systemic diseases, and pregnancy.⁴ The pelvic organs are an unusual extra-intestinal location of invasive *Salmonella* infections.⁵ However, both *Salmonella typhi* and non-typhi have been described in literature as a rare cause for pelvic infections.

Here, we present a unique case of pelvic infection caused by non-typhoidal *Salmonella hvittingfoss* following surgical removal of trophoblastic remnants.

2 | CASE

A 33-year-old nulliparous woman was referred to our hospital by her general practitioner due to trophoblastic remnants after management of a missed abortion with misoprostol. She had no medical history, did not smoke and was allergic to penicillin and terbinafine.

This is an open access article under the terms of the [Creative Commons Attribution-NonCommercial-NoDerivs](https://creativecommons.org/licenses/by-nc-nd/4.0/) License, which permits use and distribution in any medium, provided the original work is properly cited, the use is non-commercial and no modifications or adaptations are made.

© 2024 The Authors. *Clinical Case Reports* published by John Wiley & Sons Ltd.

Upon initial evaluation by her general practitioner, an early intrauterine pregnancy without heartbeat was detected. Based on a crown-rump-length (CRL) of 3 mm a gestational age of about 5–7 weeks was estimated. This evaluation took place before she went on an extended holiday to Indonesia. During her vacation she contacted a local doctor for follow-up, where an ultrasound showed a miscarriage with a CRL of 7 mm (in accordance with a pregnancy of around 6–7 weeks) without a heartbeat. Management with misoprostol was recommended. Only abdominal cramps and diarrhea were reported after oral ingestion of the medication. After 9 days a repeat ultrasound showed the ineffectiveness of the medical treatment.

Upon returning from holiday, she was referred to the gynecology department of our hospital. A transvaginal ultrasound confirmed the persistent products of conception. Uterine evacuation by dilatation and suction curettage (D&C) was performed under ultrasound guidance, which confirmed the complete removal of the trophoblast without complications. The anatomopathological examination of the trophoblast did not show any signs of infections or abnormalities.

Five days post-surgery, the patient presented to the emergency department with increased blood loss. Upon assessment, she was hemodynamically stable, without a fever and a normal amount of blood loss. Blood analysis showed a normal hemoglobin (12.2 g/dL), a slightly elevated white cell count ($11.1 \times 10^9/L$) and a normal C-reactive protein (CRP) (4.1 mg/L). A transvaginal ultrasound demonstrated an intrauterine irregular mixed hyper- and hypo-echogenic mass measuring 4.9×2.3 cm (Figure 1), most consistent with a blood clot. These symptoms and images were viewed within the normal postoperative course.

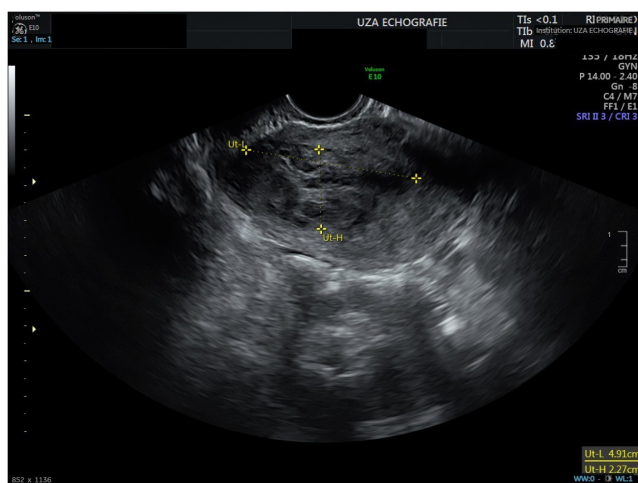


FIGURE 1 Transvaginal ultrasound at first emergency encounter.

One day later the patient presented herself again at the emergency department because of a high fever, up to $39.8^{\circ}C$. Blood analysis showed a slightly higher white cell count ($11.9 \times 10^9/L$) than the day before and an elevated CRP (39.8 mg/L) as well. After examination, the initial diagnosis was postoperative endometritis. She was admitted with intravenous antibiotics. Clindamycin at a dosage of 900 mg every 8 h was administered due to a penicillin allergy. Blood cultures showed a growth of *Salmonella*. Furthermore, the cervical swab revealed this pathogen as well. Urine culture stayed sterile. After identifying a *Salmonella* species in both the cervical swab and the blood cultures, a stool culture was obtained. The latter was also positive for *Salmonella*. All these cultures showed the same serotype of *Salmonella*: *S. hvittingfoss*.

After consulting the infectiologist and based on the susceptibility of the organism, the antibiotic treatment was switched at Day 2 of hospitalization. Ciprofloxacin intravenously, at a dosage of 400 mg every 12 h, was given for 7 days. After this switch in therapy, the patient remained fever-free and had a clinical and biochemical recovery.

Because of the mass still present in the womb, the patient was also given misoprostol at a dosage of $800 \mu g$ every 12 h, for the first 2 days of hospitalization. Afterwards, there was minimal to no blood loss. After consulting with several gynecologists, a wait-and-see approach was advised due to the clinical recovery. The patient was discharged after 9 days of hospitalization with no remnant signs of endometritis.

At the gynecological consultation 4 weeks later there was a complete recovery with no residual intrauterine tissue (Figure 2).

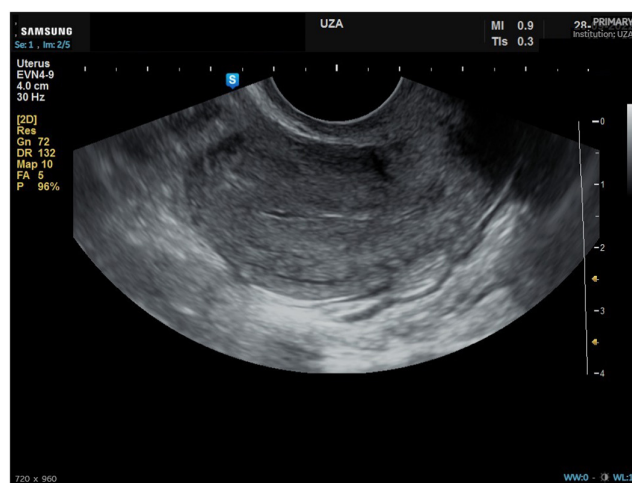


FIGURE 2 Transvaginal ultrasound at follow-up appointment showing no remnant tissue intrauterine.

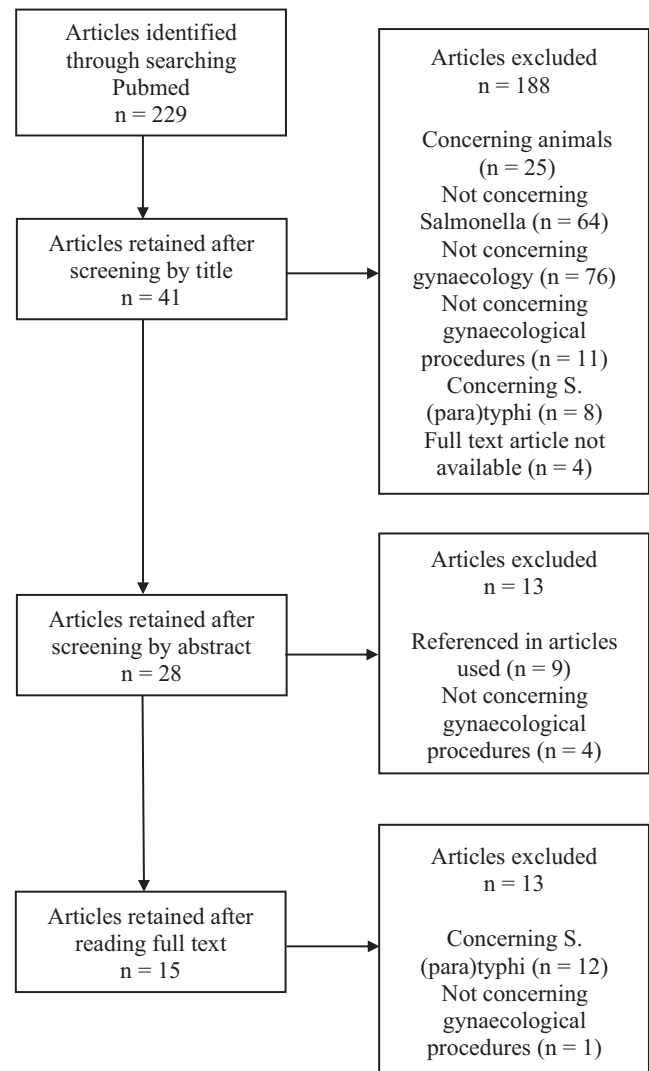
3 | METHODS

A systematic search was conducted on Pubmed to identify literature regarding invasive infections with *Salmonella* after a gynecological procedure and *Salmonella* infection of the pelvic organs. This search was conducted in February 2023. There was no limitation on the year of publication. The following filters were applied: 'human', 'female' and 'Dutch/English/French articles'. The following combination of MESH terms were used: *Salmonella* AND endometritis; *Salmonella* AND gynecology AND infection; *Salmonella* AND genital AND infection; *Salmonella* AND pelvic AND inflammatory AND disease; *Salmonella* AND miscarriage AND curettage; *Salmonella* AND curettage; *Salmonella* AND uterine AND infection; *Salmonella* AND abortion. Reference and citation lists were used. Articles were first screened by title and subsequently by abstract, resulting in the identification of 28 articles of potential use. After reviewing each article, 15 were used (Graph 1).

At the same time more selective searches were conducted on Pubmed to find information about postoperative endometritis and salmonellosis. We limited our search on the year of publication: from 2000 to 2023. The same filters were applied: 'human', 'female' and 'Dutch/English/French articles'. The following combinations of MESH terms were used: invasive AND *Salmonella* AND infection AND global; invasive AND *Salmonella* AND infection AND Europe; postoperative AND endometritis AND microbiology; epidemiology AND endometritis AND abortion; antibiotic prophylaxis AND postsurgical AND gynecology. The same selection process, as described above, was applied. From this search six articles were used (Graph 2).

4 | DISCUSSION

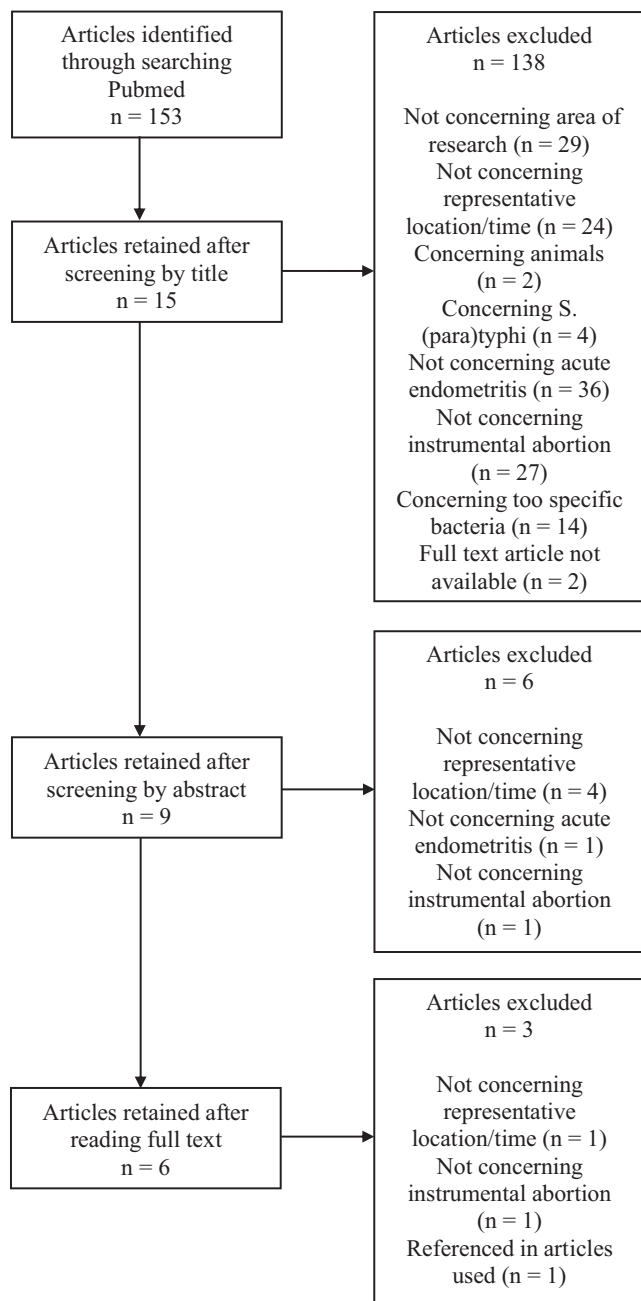
Organisms can reach the organs of the female genital tract through three pathways: ascending vaginally, via direct contact with an inflamed bowel or through hematogenous dissemination.⁶ The latter is possible via direct bacteremia or by the bacteria breaching the intestinal cell wall and entering macrophages which can lead to the involvement of secondary locations of *Salmonella*.⁷ In our case, the *Salmonella* bacteria could be cultured in blood cultures, a cervical swab, and a stool culture. Our primary hypothesis is contamination during surgery with subsequent triggering of an invasive infection. The *Salmonella* bacteria, which colonized the gastrointestinal tract, ascended vaginally, facilitated by the surgery. Due to the invasive nature of the procedure the pathogen was able to cause an endometritis. Our patient did have an episode of diarrhea



GRAPH 1 Flow diagram of the literature review and selection process of articles used regarding invasive infection with *Salmonella* after a gynecological procedure and *Salmonella* infection of the pelvic organs.

during her trip. However, this was first thought to be a side effect of misoprostol. Another, but less likely, pathogenesis is an infection due to hematogenous spread. After her *Salmonella* infection during the holiday, the pathogen could have disseminated hematogenously to the uterus and caused an infection. This route is less plausible as it does not explain the interval in time between the gastroenteritis and the endometritis, nor the timing of the invasive infection after the surgery.

The prevalence of infections after surgical abortion procedures such as D&C is 0.1%–4.7% worldwide and 0.0%–0.4% in high-income countries.⁸ The most common pathogens are those of the genital microbiome, which is polymicrobial consisting of aerobes and anaerobes. Anaerobic bacteria are most often associated with infections after D&C. Occasionally the enteric flora and



GRAPH 2 Flow diagram of the literature review and selection process of articles used regarding salmonellosis and postoperative endometritis.

sexually transmittable diseases, such as *C. trachomatis* and *N. gonorrhoea*, can cause these postoperative infections.^{8,9} These responsible micro-organisms are comparable with the pathogens linked with a postpartum endometritis.^{8,9} Hence, the standard antibiotic treatment of postoperative and postpartum endometritis should be comparable. It consists of a broad-spectrum antibiotic, which must be adjusted based on the antibiogram. However, the initial antibiotic treatment in our case was clindamycin because of a penicillin allergy. This is a poor choice since it is not active against most

gram-negative aerobes and it is recommended to combine clindamycin with another antibiotic, active against aerobic gram-negative bacteria, for the treatment of endometritis and septic abortion.¹⁰ Additionally, based on the microbiological spectrum, clindamycin is not active against Enterobacteriaceae, such as *Salmonella* species.¹⁰ The preferred treatment for non-typhoidal *Salmonella* infections is ciprofloxacin.⁵

The actual prevalence of different micro-organisms responsible for endometritis may be underestimated, given that in clinical practice the broad-spectrum antibiotics are often administered before cultures are obtained. Sometimes the general practitioner has already started antibiotics, or in hospitals where a resident gynecologist is not available during the night, antibiotics are prescribed without elaborate clinical examination before referral to a gynecologist.

As previously discussed, Salmonellosis (an infection with a non-typhoidal *Salmonella* species) is very common, with a rate of 16.6 cases per 100,000 population in Europe in 2021.³ The incidence of invasive infections with non-typhoidal *Salmonella* are less frequent and, less described in literature. A global systematic analysis¹⁰ showed a worldwide incidence of 7.5 cases per 100,000 population in 2017, with most cases located in sub-Saharan Africa. In high income countries the estimated incidence in 2017 was 1.1 cases per 100,000.¹¹ Furthermore, a study by Mughini-Gras et al.¹² described an annual average proportion of 4.6% of invasive non-typhoidal infections in the Netherlands between 2005 and 2018. The pelvic organs are a rare but described extra-intestinal location of invasive *Salmonella* infections.⁵ In literature, there are more than 30 cases documented of a *Salmonella* abscess of the ovaries, mostly occurring in case of a pre-existing cyst.^{7,13–15} A few case studies of pelvic inflammatory disease caused by a non-typhoidal *Salmonella* species are reported.^{5,16} Moreover, non-typhoidal *Salmonella* infections are described in pregnancy resulting in various complications, including septic abortion, pregnancy loss, chorioamnionitis and neonatal sepsis.^{4,17–21} In our literature review, only one case of a pelvic infection after a gynecological procedure was found. Latlitha et al.²² briefly described a case of a pelvic infection with *S. typhimurium* after a hysterectomy. The literature review showed no previous report of an invasive *Salmonella* infection due to vaginal surgery. To the best of our knowledge, this is the first case of a pelvic infection caused by *S. hvittingfoss*.

During pregnancy the immune system is altered to accommodate the growth of the fetus. Different mechanisms have been described. A known process is altering the ratio of Th1/Th2 cytokine levels in the advantage of the Th2 immunity. This is important as the immune response against *Salmonella* is largely Th1-dependent.

Consequently, a pregnant woman is more susceptible for Salmonella infections.^{4,18} In our case, this mechanism could have contributed to the primary infection with Salmonella abroad.

Nutritional advice provided to pregnant women mainly focuses on the prevention of Listeria and Toxoplasmosis. However, it is important to emphasize the risk of a Salmonella infection as well, especially for pregnant women traveling to developing countries.

The procedure was performed following the in-hospital protocol, with vaginal disinfection using chlorhexidine gluconate 0.05% and no administration of prophylactic antibiotics. However, the ACOG²³ advises to use 4% chlorhexidine gluconate or povidone-iodine for preoperative vaginal disinfection before a vaginal surgery. Concerning antibiotic prophylaxis there are different guidelines with different consensus. The ACOG²³ advises the use of perioperative antibiotics. This is based on extrapolation of a meta-analysis which showed a reduction of postoperative infections when prophylactic antibiotics are used during induced surgical abortion.²³ However, others do not recommend the administration of antibiotic prophylaxis during a D&C for incomplete abortion.^{24,25}

5 | CONCLUSION

In conclusion, non-typhoidal Salmonella may cause postoperative endometritis. It is important to remain critical about potential etiologic pathogens, especially if patients traveled abroad or had a previous history of gastroenteritis. Furthermore, in case of pregnancy, we must be more vigilant for less probable micro-organisms since immunity is altered during pregnancy. This case highlights the need for microbiological diagnosis of endometritis and appropriate antibiotic treatment based on the antibiogram.

Perioperative vaginal disinfection, in case of vaginal surgery, can be done using 4% chlorhexidine gluconate or povidone-iodine. Further research is needed regarding the use of perioperative antibiotic prophylaxis during surgical evacuation of an incomplete abortion.

Additionally, it is important to provide nutritional advice to pregnant woman which also emphasize the risk of a Salmonella infection, particularly to those traveling to developing countries.

AUTHOR CONTRIBUTIONS

Sarah Baily: Conceptualization; data curation; formal analysis; writing – original draft; writing – review and editing. **Sascha Vereeck:** Data curation; writing – review and editing. **Yves Jacquemyn:** Conceptualization; writing – review and editing.

FUNDING INFORMATION

There is no funding for this article.

CONFLICT OF INTEREST STATEMENT

There is no conflict of interest to report.

DATA AVAILABILITY STATEMENT

Data sharing is not applicable to this article as no new data were created or analyzed in this study.

CONSENT

Written informed consent was obtained from the patient to publish her clinical information and images in this report in accordance with the journal's patient consent policy.

ORCID

Sarah Baily  <https://orcid.org/0009-0003-5568-3611>

Yves Jacquemyn  <https://orcid.org/0000-0003-3172-5672>

REFERENCES

- World Health Organization. Typhoid. https://www.who.int/news-room/fact-sheets/detail/typhoid?gclid=CjwKCAiAjPyfBhBMEiwAB2CCIk6CWJupm3kP6ifjDLYQpliqLZwKkWO7ZGN09uHYEXUVq99P-RNWRoCtkQAvD_BwE. Accessed March 1, 2023.
- Burgmans JP, van Erp EJ, Brimicombe RW, Kazzaz BA. Salmonella enteritidis in an endometriotic ovarian cyst. *Eur J Obstet Gynecol Reprod Biol*. 1997;72(2):207-211. doi:10.1016/s0301-2115(96)02680-2
- European Centre for Disease Prevention and Control. Salmonellosis. *ECDC. Annual Epidemiological Report for 2021*. ECDC; 2022.
- Delcourt C, Yombi JC, Vo B, Yildiz H. Salmonella enteritidis during pregnancy, a rare cause of septic abortion: case report and review of the literature. *J Obstet Gynaecol*. 2019;39(4):554-555. doi:10.1080/01443615.2018.1529153
- Valayatham V. Salmonella: the pelvic masquerader. *Int J Infect Dis*. 2009;13(2):e53-e55. doi:10.1016/j.ijid.2008.06.015
- Thaneemalai J, Asma H, Savithri DP. Salmonella tuboovarian abscess. *Med J Malaysia*. 2007;62(5):422-423.
- Pathiraja PDM, Rafi J, Woolnough E, Clare A. Bali belly: Salmonella senftenberg found in an infected ovarian endometrioma. *Case Rep Obstet Gynecol*. 2020;2020:3581091. doi:10.1155/2020/3581091
- Rouse CE, Eckert LO, Muñoz FM, et al. Postpartum endometritis and infection following incomplete or complete abortion: case definition & guidelines for data collection, analysis, and presentation of maternal immunization safety data. *Vaccine*. 2019;37(52):7585-7595. doi:10.1016/j.vaccine.2019.09.101
- Lapinsky SE. Obstetric infections. *Crit Care Clin*. 2013;29(3):509-520. doi:10.1016/j.ccc.2013.03.006
- Guay D. Update on clindamycin in the management of bacterial, fungal and protozoal infections. *Expert Opin Pharmacother*. 2007;8(14):2401-2444. doi:10.1517/14656566.8.14.2401
- GBD 2017 Non-Typhoidal Salmonella Invasive Disease Collaborators. The global burden of non-typhoidal salmonella

- invasive disease: a systematic analysis for the Global Burden of Disease Study 2017. *Lancet Infect Dis.* 2019;19(12):1312-1324. doi:[10.1016/S1473-3099\(19\)30418-9](https://doi.org/10.1016/S1473-3099(19)30418-9)
12. Mughini-Gras L, Pijnacker R, Duijster J, et al. Changing epidemiology of invasive non-typhoid Salmonella infection: a nationwide population-based registry study. *Clin Microbiol Infect.* 2020;26(7):941.e9-941.e14. doi:[10.1016/j.cmi.2019.11.015](https://doi.org/10.1016/j.cmi.2019.11.015)
 13. Adelman MW, Johnson JH, Hohmann EL, Gandhi RT. Ovarian endometrioma superinfected with salmonella: case report and review of the literature. *Open Forum Infect Dis.* 2017;4(2):ofx048. doi:[10.1093/ofid/ofx048](https://doi.org/10.1093/ofid/ofx048)
 14. Toyoshima H, Hagimoto M, Tanigawa M, Tanaka H, Nakanishi Y, Sakabe S. Salmonella stanley ovarian abscess with endometrioma in a pregnant woman in the third trimester. *IDCases.* 2021;24:e01068. doi:[10.1016/j.idcr.2021.e01068](https://doi.org/10.1016/j.idcr.2021.e01068)
 15. Tanaka T, Ota Y, Sano R, Shimoya K, Moriya T, Shiota M. Diagnostic laparoscopy for ovarian tumor due to Salmonella infection. *Gynecol Minim Invasive Ther.* 2022;11(1):61-63. doi:[10.4103/GMIT.GMIT_92_20](https://doi.org/10.4103/GMIT.GMIT_92_20)
 16. Kostiala AA, Ranta T. Pelvic inflammatory disease caused by Salmonella Panama and its treatment with ciprofloxacin. *Case Report Br J Obstet Gynaecol.* 1989;96(1):120-122. doi:[10.1111/j.1471-0528.1989.tb01589](https://doi.org/10.1111/j.1471-0528.1989.tb01589)
 17. Gyang A, Saunders M. Salmonella Mississippi: a rare cause of second trimester miscarriage. *Arch Gynecol Obstet.* 2008;277(5):437-438. doi:[10.1007/s00404-007-0506-2](https://doi.org/10.1007/s00404-007-0506-2)
 18. Mooney C, James J. Salmonella bacteremia in the second trimester: a case report. *Sci J Womens Health Care.* 2021;5(1):001-004.
 19. van der Klooster JM, Roelofs HJ. Management of Salmonella infections during pregnancy and puerperium. *Neth J Med.* 1997;51(2):83-86. doi:[10.1016/s0300-2977\(97\)00037-5](https://doi.org/10.1016/s0300-2977(97)00037-5)
 20. Mollo B, Hobson CA, Le Hello S, et al. Intrauterine infection caused by nontyphoidal salmonella: a literature review. *J Matern Fetal Neonatal Med.* 2021;34(23):4000-4004. doi:[10.1080/14767058.2019.1702950](https://doi.org/10.1080/14767058.2019.1702950)
 21. Roll C, Schmid EN, Menken U, Hanssler L. Fatal Salmonella enteritidis sepsis acquired prenatally in a premature infant. *Obstet Gynecol.* 1996;88(4 Pt 2):692-693. doi:[10.1016/0029-7844\(96\)00076-2](https://doi.org/10.1016/0029-7844(96)00076-2)
 22. Lalitha MK, John R. Unusual manifestations of salmonellosis—a surgical problem. *Q J Med.* 1994;87(5):301-309.
 23. ACOG practice bulletin no. 195: prevention of infection after gynecologic procedures. *Obstet Gynecol.* 2018;131(6):e172-e189. doi:[10.1097/AOG.0000000000002670](https://doi.org/10.1097/AOG.0000000000002670)
 24. DeNoble AE, Kuller JA, Heine RP, Dotters-Katz S. Antibiotics for the prevention and treatment of postsurgical obstetric infections. *Obstet Gynecol Surv.* 2018;73(8):475-485. doi:[10.1097/OGX.0000000000000590](https://doi.org/10.1097/OGX.0000000000000590)
 25. Bauer MP, van de Garde EMW, van Kasteren MEE, et al. SWAB Richtlijn Peri-operatieve profylaxe. Stichting Werkgroep Antibioticabeleid (SWAB). <https://swab.nl/nl/exec/file/download/89>. Published July, 2019. Accessed March 1, 2023.

How to cite this article: Baily S, Vereeck S, Jacquemyn Y. Salmonella hvittingfoss, a rare case of postoperative endometritis: A case report and review of the literature. *Clin Case Rep.* 2024;12:e8591. doi:[10.1002/ccr3.8591](https://doi.org/10.1002/ccr3.8591)